

PHRASES
PRACTICAL
HUMAN ANATOMY

WEISSE

PHRASES

EST.	C
	3
No.	11

A.E. HANSON
PHILA. PA.

A. E. Hanson
Med Dept U P '92



238

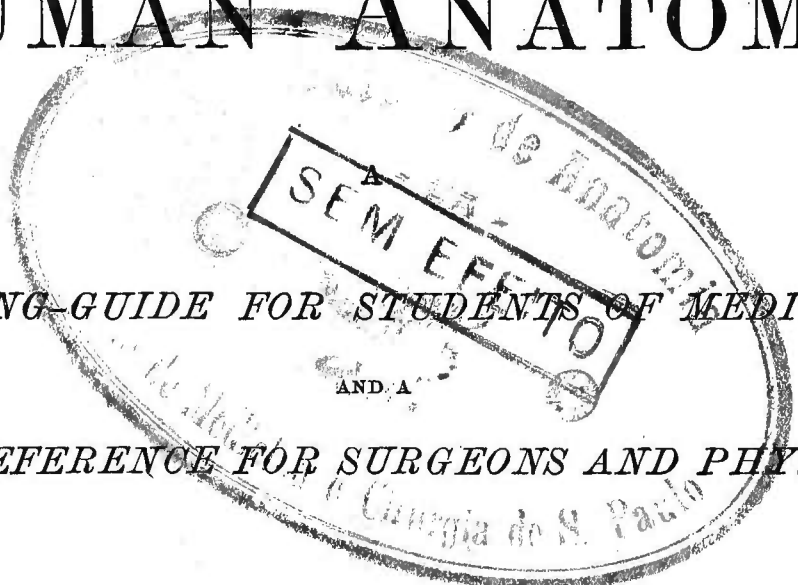
PRACTICAL

HUMAN ANATOMY

WORKING-GUIDE FOR STUDENTS OF MEDICINE

AND A

READY-REFERENCE FOR SURGEONS AND PHYSICIANS



BY

FANEUIL D. WEISSE, M.D.

PROSECTOR (1863 TO 1865) TO THE LATE VALENTINE MOTT, M.D., LL.D., EMERITUS PROFESSOR OF SURGERY AND SURGICAL ANATOMY, MEDICAL DEPARTMENT OF THE UNIVERSITY OF THE CITY OF NEW YORK.

PROFESSOR OF PRACTICAL AND SURGICAL ANATOMY, MEDICAL DEPARTMENT OF THE UNIVERSITY OF THE CITY OF NEW YORK.

PROFESSOR OF ANATOMY, NEW YORK COLLEGE OF DENTISTRY.

ILLUSTRATED BY 222 LETTERED PLATES, CONTAINING 321 FIGURES.

THIRD EDITION.

NEW YORK

WILLIAM WOOD & COMPANY

56 AND 58 LAFAYETTE PLACE

1888



CLASS. QM34
(W432p
1888
v.1-

COPYRIGHT, 1886, BY
WILLIAM WOOD & COMPANY

TROW'S
PRINTING AND BOOKBINDING COMPANY.

To

JOHN A. WEISSE, M.D.

MY FATHER,

THIS WORK IS DEDICATED

WITH THE WARMEST FILIAL AFFECTION, AND A DEEP SENSE OF GRATITUDE
FOR HIS PERSONAL GUIDANCE OF MY EDUCATION.

PREFACE TO THE THIRD EDITION.

WE are much gratified to realize that "Practical Human Anatomy" has met with such favor as to have passed, in less than three years, to its third edition.

In the presentation of this edition the author would make the following acknowledgments :

1st. To the professors and demonstrators of anatomy of the medical institutions throughout the United States, and of other countries, who have, by letters, expressed their commendations of the work ;

2d. To the medical press of the United States, the Dominion of Canada, and the British Islands for their kind reception of the same ;

3d. To the medical colleges throughout the country for their having, so generally, included it among their text-books for students, as to give it the first rank among books on practical anatomy now in use in this country, and as to make it, of all anatomical works, second only to Gray's "Anatomy" in the number of medical students of the United States to whom it is recommended ;

4th. To those who have interested themselves in verifying, by their own dissections, special points advanced, which vary from the usually accepted teachings ;

5th. To those who have called attention to errors and omissions.

It must be said of "Practical Human Anatomy" that it is not intended to take the place of Gray's or Quain's classic and encyclopedic works on descriptive human anatomy. Its aim is to be a practical, illustrated supplement to them.

An Appendix has been added to this edition, in which omissions have been made good. Besides the correction of certain errors in the text, Plates 192, 193, 194, 195, 196, 197, 201, 203, and 204 have been altered with respect to the course of the hypoglossal nerve.

To increase the usefulness of the work most of the copies of this edition will be bound in *four parts*, thereby converting it, practically, into a *pocket manual*. This form is intended more especially for the use of the student in the dissecting-room.

PREFACE.

THIS work was commenced with a desire—after an experience of nearly twenty years in study, actual dissections, and the teaching of anatomy—to produce a practical working-guide for the student at the cadaver, and a ready-reference book, which would take the place of the cadaver, for practitioners of surgery and medicine.

The plan of the work embraces the following points :

1st, the division of the body into *practical dissections* ;
2d, the giving, in *dissection-paragraphs*, the progressive steps by which the several parts, involved in a dissection, are to be systematically displayed ;

3d, the guidance, by lines across the parts in the Plates—called *section-lines*—to the points where they are to be cut, for their reflection, in order to advance to a succeeding stage of the dissection ;

4th, the indication, by *numbering the parts of the dissections*, of the order in which they are exposed ;

5th, the description of the parts, in *descriptive-anatomy paragraphs*, as they are brought into view ;

6th, the adherence, in expressing the relations of parts, to a well-defined nomenclature of *general and special anatomical terms* ;

7th, the illustration of the anatomy of the regions and viscera of the body by Plates, *with the names of the parts printed upon them or at the sides of the Figures with indicating lines to them*—the *dead-anatomy* is thus presented to the student, and the *living-anatomy* to the surgeon and physician.

The dissections have been planned, as far as practicable, to give all the attachments of included muscles.

Each dissection has been completely described and illus-

trated, irrespective of the contiguous dissections upon which it may encroach.

The bones of the body have not been described in detail ; their practical relations to the anatomical elements of the several dissections are shown in the Plate illustrations of their surfaces with the areas they afford for muscle attachments ; together with their presentation in the progressive steps of the dissections.

The attachments of muscles are given without any distinction as to their being the *origin* and *insertion* of the same ; it is more natural and clear to enumerate the attachments only.

The illustrations include the following :

- 153 full-page, original, Plates ;
- 51 Plates, of 132 original Figures ;
- 6 full-page Plates selected from standard authors ;
- 9 Plates, of 25 Figures selected from standard authors ;
- Plate 56, of one original and two selected Figures ;
- Plate 66, of one original and one selected Figure ;
- 15 original text Figures.

The original Plates and Figures were sketched and drawn by Mr. Maximilian Cohn from dissections by the author.

The illustration and description of the complete distribution of the sympathetic nervous system, and of the lymphatic system, have not been given, as they do not come within the scope of the work. The dissection of the globe of the eye, and of the auditory apparatus have been omitted.

No reference has been made to surgical and medical or applied anatomy, as it is deemed best to do *one thing at a time*. Moreover, the systematic mastery of the anatomy of the body places one in a position to make practical applications of the same, to the elucidation of surgical, medical, and obstetrical problems ; and to read, appreciatively, the special works on surgical and medical anatomy.

That which can be demonstrated to the unaided eye is the province of anatomy ; therefore, the structure of parts, requiring the aid of the microscope, has not been alluded to, as it belongs to Histology.

The practitioner of surgery and medicine, in the absence of a cadaver to refer to, has been much in need of illustrations of anatomy, that would present him a progressive series of

dissections of a region or organ about which he desired information. To meet this want has been one of the aims in the preparation of this work, special attention having been given to those regions and organs which claim frequent surgical and medical care. To this end also the Contents and Index have been so elaborated as to facilitate the finding of the Plate illustrations and text descriptions of any part.

Too much cannot be said in praise of the comparatively wonderful artistic skill displayed by Mr. Maximilian Cohn, in his faithful reproductions of nature, given us in the Plates and Plate Figures; and the clearness of his lettering of the same. The illustrations are photographic in their representations of nature, and are works of art in themselves.

Thanks are due to the Moss Engraving Co. for the care which has been bestowed upon the photo-engraving and the printing of the Plates.

Nature has been the text-book, to which reference has always been made; but, a due respect for the labors of our fathers and of our contemporaries has been kept in view.

The original intention was to illustrate this work by selections from the illustrations of standard authors, simply adapting and lettering the same to fulfil our purpose. After having carried out this scheme to the extent of some 300 photo-Plates and 150 electrotypes, the plan was abandoned, because it was found impracticable to accomplish the object of the work therewith, and *the cadaver was resorted to*.

Errors and omissions, no doubt, may be found in the text and Plates, but should any, *of whatever nature*, appear to a reader, his personal communication of the same to the author will be regarded as a kindness.

The manifold difficulties and disappointments that have been met with, in the evolution of this volume, are only for a private ear. The desired end will have been attained, if the fruits borne of years of time, thought, and labor are: that it enables the student of medicine to acquire, more readily and thoroughly, a knowledge of human anatomy; and proves a companion to the surgeon and the physician, to keep them in mind of the practical facts of anatomy.

CONTENTS AND ILLUSTRATIONS.

INTRODUCTION.

PLATES 1 to 4, inclusive.....*Pages 1-12*

FIRST DISSECTION.

MALE PERINEUM.

PLATES 5 to 12 inclusive.....*Pages 13-28*

SECOND DISSECTION.

FEMALE PERINEUM.

PLATES 13 to 20, inclusive.....*Pages 29-42*

THIRD DISSECTION.

ANTERO-LATERAL AREAS OF THE ABDOMINAL PARIETES.

PLATES 21 to 28, inclusive.....*Pages 43-54*

FOURTH DISSECTION.

ABDOMINAL VISCERA IN SITU.

PLATES 29 to 38, inclusive.....*Pages 55-72*

FIFTH DISSECTION.

ABDOMINAL AND PELVIC INTERIORS.

PLATES 39 to 46, inclusive.....*Pages 73-84*

SIXTH DISSECTION.

ABDOMINAL VISCERA OUT OF THE BODY.

PLATES 47 to 54, inclusive.....*Pages 85-94*

SEVENTH DISSECTION.

MALE PELVIC VISCERA OUT OF THE BODY.

PLATES 55 and 56.....*Pages 95-100*

EIGHTH DISSECTION.

FEMALE PELVIC VISCERA OUT OF THE BODY.

PLATES 57 and 58.....*Pages 101-106*

NINTH DISSECTION.

ANTERIOR OF THIGH.

PLATES 59 to 66, inclusive *Pages* 107-122

TENTH DISSECTION.

ANTERIOR OF LEG AND DORSUM OF FOOT.

PLATES 67 to 74 inclusive..... *Pages* 123-132

ELEVENTH DISSECTION.

PLANTAR REGION OF THE FOOT.

PLATES 75 to 82, inclusive *Pages* 133-150

TWELFTH DISSECTION.

POSTERIOR REGION OF THE LEG AND THE POPLITEAL SPACE.

PLATES 83 to 90, inclusive *Pages* 151-162

THIRTEENTH DISSECTION.

GLUTEAL REGION AND POSTERIOR REGION OF THE THIGH.

PLATES 91 to 100, inclusive..... *Pages* 163-176

FOURTEENTH DISSECTION.

ARTICULATIONS OF ANKLE, FOOT, LEG, KNEE, AND HIP.

PLATES 101 to 112, inclusive. *Pages* 177-192

FIFTEENTH DISSECTION.

ANTERIOR OF THORAX, AXILLA, AND ARM.

PLATES 113 to 120, inclusive *Pages* 193-206

SIXTEENTH DISSECTION.

ANTERIOR OF ELBOW, FOREARM, AND HAND.

PLATES 121 to 134, inclusive *Pages* 207-236

SEVENTEENTH DISSECTION.

ANTERIOR OF THE THORACIC PARIETES; THORACIC VISCERA IN
SITU; INTERIOR OF THE THORACIC CAVITY.

PLATES 135 to 140, inclusive..... *Pages* 237-250

EIGHTEENTH DISSECTION.

VISCERA OF THE THORAX OUT OF THE BODY.

PLATES 141 to 146, inclusive..... *Pages* 251-264

NINETEENTH DISSECTION.

REGION OF THE BACK; SPINAL CORD IN SITU; VERTEBRAL COLUMN AND ITS LIGAMENTS.

PLATES 147 to 156, inclusive.....*Pages* 265-286

TWENTIETH DISSECTION.

ANTERIOR SCAPULAR MUSCLES; POSTERIOR OF SHOULDER AND ARM.

PLATES 157 to 162, inclusive.....*Pages* 287-294

TWENTY-FIRST DISSECTION.

POSTERIOR OF ELBOW, FOREARM, HAND, AND DIGITS.

PLATES 163 to 170, inclusive.....*Pages* 295-308

TWENTY-SECOND DISSECTION.

ARTICULATIONS OF HAND, ELBOW, FOREARM, AND SHOULDER.

PLATES 171 to 176, inclusive.....*Pages* 309-316

TWENTY-THIRD DISSECTION.

SCALP; VERTEX PORTION OF THE MEMBRANES OF THE BRAIN;
INTERIOR OF THE BASE OF THE CRANIUM.

PLATES 177 to 180, inclusive.....*Pages* 317-326

TWENTY-FOURTH DISSECTION.

SUPERFICIAL REGION OF THE FACE; ORBITAL CAVITY; MIDDLE
FOSSA OF THE CRANIUM; DEEP REGION OF THE FACE.

PLATES 181 to 188, inclusive.....*Pages* 327-354

TWENTY-FIFTH DISSECTION.

ANTERO-LATERAL AREAS OF THE NECK.

PLATES 189 to 198, inclusive.....*Pages* 355-376

TWENTY-SIXTH DISSECTION.

ARTERIES AND NERVES CONTIGUOUS TO THE PHARYNX; PHARYNX;
SOFT AND HARD PALATE; TONGUE AND CONTIGUOUS PARTS;
LARYNX; NASAL CAVITIES AND CONTIGUOUS PARTS.

PLATES 199 to 210, inclusive.....*Pages* 377-408

TWENTY-SEVENTH DISSECTION.

ARTERIES OF THE BRAIN; EXTERIOR OF THE CEREBRUM; PARTS
OF THE BRAIN.

PLATES 211 to 222, inclusive.. ..*Pages* 409-432

SOURCE OF SELECTED ILLUSTRATIONS.

PLATE 3:	Figs. 1, 2, and 3	<i>Bourgery.</i>
“ 4:	Figs. 1 and 2	<i>Bourgery.</i>
“ 23	<i>Hirschfeld.</i>
“ 26	<i>Hirshfeld.</i>
“ 31:	drawn from and modified	<i>Jamain.</i>
“ 33:	drawn from.....	<i>Sappey.</i>
“ 43.	<i>Bourgery.</i>
“ 45:	Figs. 1 and 2.....	<i>Bourgery.</i>
“ 47:	Figs. 1, 2, 3, 4, 5, and 6	<i>Bonamy.</i>
“ 49:	Fig. 1	<i>Bonamy.</i>
“ 49:	Fig. 2. Drawn from	<i>Jamain.</i>
“ 50:	Figs. 1 and 2	<i>Bonamy.</i>
“ 53:	Figs. 1 and 2.....	<i>Bonamy.</i>
“ 54:	Figs. 1, 2, 3, and 4.....	<i>Bonamy.</i>
	Figs. 1 and 2 of PLATE 56.....	<i>Bonamy.</i>
“ 58:	Figs. 1 and 2.....	<i>Bonamy.</i>
	Fig. 2 of PLATE 66	<i>Bourgery.</i>
“ 76:	modified.....	<i>Bourgery.</i>
“ 84:	modified.	<i>Bourgery.</i>
“ 92:	modified	<i>Bourgery.</i>

PRACTICAL HUMAN ANATOMY.

INTRODUCTION

It is, for the following reasons, of the greatest importance that the dissector read this introduction, carefully, before commencing his dissections: first, that he may be prepared to use this work to the greatest possible advantage; second, that he may have a general appreciation of the anatomical elements that he is to meet with; third, that he may obtain a general idea of how to dissect the several parts which enter into the make-up of the body; fourth, that he may know the relative importance of the parts exposed in a given dissection, and thereby be guided, as to which to preserve and which to cut away, as he progresses.

WORKING PLAN.

Dissector's Use of this Work.—The following course should be pursued with a given dissection: *first*, read, consecutively, the numbered descriptive-anatomy paragraphs (in large type), referring to the Plates as directed therein; *second*, read, continuously, the dissection paragraphs (in small type), referring to the Plates as indicated therein; *third*, dissect in strict accordance with the directions given in the dissection paragraphs; *fourth*, verify dissections by the Plates and by the text of the descriptive-anatomy paragraphs.

Plate References.—When a given Plate, say 51, is referred to in a descriptive-anatomy paragraph heading, the dissector is to continue to work with Plate 51, until another Plate or other Plates, say 52, or 55, 57, and 59, is or are referred to;

in a subsequent descriptive-anatomy paragraph heading ; then, it or they become the Plate or Plates to be worked with.

Of Right and Left Parts.—In the dissection and descriptive-anatomy paragraphs, and in the Plates, only the parts of one side are referred to or illustrated ; the dissector must make the necessary transposition, which his dissection may require.

Section Lines on the Parts.—Particular attention is called to *the black lines crossing parts in the plates* ; they indicate the points where parts are to be sectioned, that the same may be reflected. *A part is only to be sectioned, at that stage of the dissection, where it is so directed in a dissection paragraph* ; if parts are sectioned out of order, it leads to incompleteness in the work done. Dissection directions will sometimes state that muscles, etc., are to be reflected, while in the Plate, worked by, they are cut short or even cut away. *The dissection directions are to be followed without regard to the Plates* ; the latter are drawn to show parts to the best advantage.

Reproduction of Plates.—In using the Plates as guides to dissection, it must not be supposed by the dissector that he is to reproduce them severally on the subject. They are to be referred to as indicated in the descriptive anatomy and dissection paragraphs. The same part may appear in several Plates, from different points of view, but, collectively, they afford a clearer idea of the part, and its relations, than could be given in a single Plate.

Abnormalities.—In the descriptive-anatomy paragraphs no references are made to abnormalities ; for these, one of the standard text-books on descriptive anatomy may be consulted. The Plates present the normal anatomy.

Terms of Relation.—The *general terms* used in describing the relations of parts in the dissections, are as follows : *anterior* and *posterior*, refer to those surfaces of the body, respectively ; *superior* and *inferior*, as toward the head or feet ; *external* and *internal*, relatively to the median line of the

body. *Special terms*, applicable to special dissections, will be given in their proper places.

DISSECTING INSTRUMENTS.

Dissecting Instruments, Plate 1.—Experience has proved, that the following instruments, etc., will meet all the wants of the dissector, and in some respects, better than the contents of the conventional dissecting case: a pair of modified Coxeter forceps, two scalpels, a pair of sharp-pointed curved scissors, chain-hooks, thumb-pins, clasp-pins, two probes, and a scalpel strop. As contained in their case (1), they fulfil the ends of *compactness, usefulness* and *economy*.

Forceps.—The forceps (2) is the “Coxeter forceps,” modified by having its head cut square across, so that, when the closed blades are held in the hand, it may be used to strip muscles apart, etc.

Scalpels.—Each scalpel has a thick handle; a portion of the blade forms a shank to the knife, which strengthens the instrument, facilitates its manipulation, and limits its cutting portion to its available edge. One of the scalpels (3) has a rounded end, and a very convex cutting edge, which continues to the end of the blade; this scalpel is adapted for coarse work, such as reflecting flaps of skin, etc., and clearing fasciæ and muscles. The pointed scalpel (4) has a very convex cutting edge, and is intended for delicate work on nerves and vessels. These two knives will fulfill all the requirements of dissection.

Curved Scissors.—The sharp-pointed curved scissors (5) presents nothing peculiar. As an instrument for the dissector, it should be much more used than it is; after a little practice, it can with great advantage, in many instances, be made to take the place of the scalpel. As a scissors, it answers all the needs of a straight pair.

Chain-Hooks.—The chain-hooks (6) have blunt points, and the chain is very strong.

Thread.—The dissector should provide himself with *coarse linen thread*, and a needle for the same. Flaps may be advan-

tageously reflected by threads tied into perforations at their borders. Loops of thread passed around vessels, nerves, etc.—with their ends tied—will be found useful in holding them off.

Probes.—These (7) are used to demonstrate ducts, vessels, sheaths of tendons, etc.

Scalpel Strop.—This (8) will be found very convenient; one's knife is continually dulled, while dissecting; but a few passes of the scalpel over the strop will sharpen it.

A saw, chisel, hammer and hook, costotome, intestine scissors, etc., required by the dissector, constitute a part of the furniture of a practical anatomy room.

GENERAL RULES FOR DISSECTION.

Division of a Cadaver.—A cadaver may be divided into *sections* to be worked by five, six, or eight dissectors. A body assigned to five, one takes the head and neck, two take the upper extremities and thorax, and two the lower extremities, the pelvis, and the abdomen. A subject, apportioned to six, one works the head and neck, one the trunk (thorax, abdomen, and pelvis), two work the upper extremities, and two the lower extremities. A body, dissected by eight, there will be two to the head and neck, two to the trunk (thorax, abdomen, and pelvis), two to the upper extremities, and two to the lower extremities.

Object of Dissection.—*The object of dissection is to separate parts, not to cut them.* With the separation of parts is included the removal from their surfaces of fibrous tissue of investiture—as membranes, areolar tissue, fasciæ, inter-muscular septa, and vessel-sheaths.

Rules for Dissection.—There are three rules to be followed to make a good dissector:

First.—*Know what you are to look for.* This knowledge is attained by having previously read a description of the parts to be found in a given region.

Second.—*Work slowly and thoroughly.* To fulfil this rule, do not allow yourself to work without system or method, but follow the progressive steps of a given dissection, as laid down in the book, which you have selected to guide you.

Third :—*Never let your knife cut when you do not know what it is about to divide.*

Review of a Dissection.—When finishing work replace parts, as nearly as possible, in their normal relations, so that on resuming work, they may be removed in their relative order ; this affords repeated reviews of a dissection.

How to Keep a Dissection.—Re-apply skin flaps ; lay on the part the refuse tissue from the dissection ; cover with a *dampened* piece of muslin ; and, outside of all, wrap a piece of dry muslin or oil-silk.

SPECIAL RULES OF DISSECTION.

Anatomical Elements.—By an anatomical element, borrowing the term from chemical nomenclature, is to be understood a structural part of the body, such as the skin, a muscle, etc. The anatomical elements entering into the construction of the regions of the body are: *epidermis, skin, subcutaneous tissue, superficial fascia, intermuscular septa, muscles, bursæ, synovial sheaths of tendons, deep fascia, arteries, veins, lymphatic vessels, lymphatic glands, nerves, viscera, ducts, mucous membrane, serous membrane, ligaments, fibro-cartilages, cartilages, and bones.* All these elements are not present in every region of the body, and some are only found in special regions.

Epidermis.—The epidermis or cuticle claims the respect of the dissector as a useful portion of the skin to him : where the epidermis is removed, the evaporation, that takes place, causes the skin and subjacent tissues to become hard, dry, and matted together, so as to interfere materially with dissection.

Skin.—The skin or derma varies very much as to thickness, in the different regions. In making skin incisions, care should be taken, that the skin alone is cut through, as subcutaneous vessels, nerves, and even the muscles may be divided, and mar, in consequence, subsequent dissection.

DISSECTION.—The position of the knife, in making an incision through the skin or any other membrane, should be vertical to the surface (Fig. 1, Plate

2); in this position, the knife should be steadied, by the little finger resting upon the surface, and driven by the index finger at its shank; it should be drawn, as thus held, from the initial point to the terminus of the incision, the point only of the knife cutting the tissue. In reflecting flaps of skin, or other membranes (fascia, etc.), they should be commenced (Fig. 2, Plate 2) by pinching up the initial flap with the forceps, and incising the subcutaneous tissue, so as to raise the skin alone; as soon as there is sufficient flap to enable it to be grasped, it should be held taut in the fingers (Fig. 3, Plate 2) at about two inches from its attached margin; the scalpel should be held lightly with its blade flat on the subcutaneous tissue, its cutting edge at a right angle to the skin; in this position the strokes should be made in long sweeps, never allowing the cutting edge to actually touch the skin. It is not a cutting that is effected, but a scratching with the edge of the knife, which parts the taut fibrous framework of the subcutaneous tissue, thus allowing the skin to be raised from the surface beneath. Never cut away a portion of reflected skin, as it is the best possible protective covering to dissected parts.

Subcutaneous Tissue.—The subcutaneous tissue is more or less loaded with fat, and has embedded in it vessels and nerves. In some regions it can be split into two layers, which may be designated as the *superficial and the deep layer of the subcutaneous tissue*. This nomenclature avoids the confusion, which arises, if the subcutaneous tissue is called superficial fascia, and its layers superficial and deep fascia, or superficial and deep layers of the superficial fascia.

Subcutaneous Veins.—The veins, found in the subcutaneous tissue, occupy a superficial plane, and are distinguished because of the dark color, imparted to them by blood clot within.

DISSECTION.—The subcutaneous veins should be raised free from the tissue in which they are embedded, so as to lie loosely thereon.

Subcutaneous Nerves.—The subcutaneous nerves lie in a plane beneath the veins, and, as a rule, contiguous to and parallel with them.

DISSECTION.—They may be found by scratching through the subcutaneous tissue, at a right angle to the course of the nerves (Fig. 4, Plate 2); thus the subcutaneous tissue is displaced and the resistant nerve-cord becomes apparent; once recognized, at a given point, the nerve may be raised with the forceps and stripped out from its bedding with the point of the scalpel (Fig. 5, Plate 2), or with scissors. Having recognized the subcutaneous veins and nerves, the subcutaneous tissue, as flap or otherwise, may be cut away from the area of the dissection region. The subcutaneous veins and nerves may be divided and reflected as may be directed.

Superficial Fascia, Fig. 1, Plate 3.—The superficial fascia of a region is a sheet of fibrous tissue, which covers the superficies of the muscles; it is continuous over the whole body, and here and there will be seen to form special thickenings, annular ligaments, etc., to subserve the office of bands of protection and inclusion, to bind down tendons, or insure firm packing of subjacent parts.

DISSECTION.—Incisions of fascia should be made (the same as skin incisions) parallel with the fibres of the subjacent muscles. Flaps of fascia should be reflected, the same as the skin, the strokes of the blade of the scalpel should be parallel with the muscle fibres (Fig. 6, Plate 2). In reflecting the fascia from off a group of muscles, it will be noted that, at each intermuscular space, a continuity of the fascia with fibrous tissue in the intermuscular space exists; it is therefore necessary to cut through this fibrous tissue septum, in order to expose the adjacent muscle. In certain regions, the subjacent muscles are attached to the under surface of the fascia; at these areas, no attempts should be made to raise the fascia, but the same may be left upon the muscle, by cutting the fascia at the circumference of the attached portion. *Reflections of fascia should not be cut away.*

Intermuscular Septa, Figs. 2 and 3, Plate 3.—The intermuscular septa are fibrous tissue walls, recognized above, in continuity with the deep surface of the superficial fascia. They occupy the interspaces between muscles, forming compartments (Fig. 2) for their lodgement, and completely isolating each from the other. In Fig. 3, the intermuscular septa are shown in a transverse section of a limb.

Muscles.—The voluntary muscles invest the bony framework, being attached to the bones, at both ends, so as to produce movements at their articulations, or as in the case of the muscles of the face—attached to bone at one end and the skin at the other—to produce the facial expressions. Structurally, a muscle consists of a framework of fibrous tissue, which is continuous between its attachments; the tendon and the aponeurosis (flat tendon of a broad muscle) are respectively the fibrous framework of the muscle continued by itself; the fleshy portion of the muscle has, in addition, the muscle structure, lodged in the interstices of the fibrous framework. Every muscle is supplied with arteries, veins, lymphatics, and nerves; the arteries and nerve or nerves are derived from contiguous trunks. The arterial and nerve supply should always be recognized, and the same traced to where they enter the

muscle; their entrance will usually be found at the protected surfaces of the muscle.

DISSECTION.—In cleaning a muscle, never grasp it with the forceps, but let the tissue, to be removed from the muscle, be held off; the scalpel should be guided parallel with the muscle fibres (Fig. 6, Plate 2); the handle of the scalpel and the head of the forceps are excellent instruments to strip the sides of a muscle free from contiguous parts; but, in so doing, care must be taken not to break off nerves and vessels at their points of penetration into the muscle. In unpacking or separating muscles, lying in different planes or in contiguity in the same plane, they cannot be regarded as cleaned, until all their surfaces are freed of fibrous tissue.

Bursæ: Fig. 1, Plate 4; Plate 60.—A bursa is a fibrous-tissue bag, containing fluid, which is lodged upon a bony prominence, upon which skin or muscle plays; its object is to obviate undue irritation of the skin or muscle by pressure. The subcutaneous bursa over the patella (Plate 60), and the submuscular bursæ of the gluteus maximus and obturator internus (Fig. 1, Plate 4) are examples.

DISSECTION.—After recognition, a bursa may be cut away and its relations appreciated.

Sheaths of Tendons, Fig. 2, Plate 4.—Sheaths invest the long tendons of the limbs, for the isolation of the same, and the play of the tendons is facilitated by the sheaths being lined by serous membrane, which secretes synovia upon them to lubricate their surfaces. Examples of the synovial sheaths are well seen at the wrist and palm.

DISSECTION.—In the appreciation of the synovial sheaths of tendons, they should be opened at a given point and a probe inserted into them, along the tendon in both directions, to determine the extent of their investiture. After recognition, they should be stripped from the tendons with the curved scissors or scalpel.

Deep Fasciæ.—The deep fasciæ are specially thick septa or fasciæ, prolonged between the anatomical elements of a region, which form compartments for the grouping of muscles or the isolation of contiguous parts. They are also found lining the interior of cavities.

DISSECTION.—Their extent and points of attachment should be appreciated, after which, *if they interfere with subsequent dissection, they should be cut away.*

Arteries.—The arteries, when injected with substances such as plaster, wax, or rubber, are readily recognized, but when not so injected, they appear as flattened empty tubes. The smaller arteries are, as a rule, accompanied by two veins, called *venæ comites*, the larger ones by a single venous trunk.

DISSECTION.—The arterial trunks of a region should be first cleared of areolar tissue and sheath investitures; then their primary branches determined in the order of their size. All branches of distribution should be followed to the parts to which they distribute, and the anastomoses of branches should be recognized, where possible.

Veins.—The veins of the body are subcutaneous and *comites*. The subcutaneous veins are lodged, as their name indicates. The *comites* or deep veins accompany arteries; some of the deep veins are not *comites*. The venous channels (*sinuses*) within the cranium are not *comites* of arteries.

DISSECTION.—With a few exceptions, which will be noted, the subcutaneous veins do not require the dissector's attention; the *venæ comites* of the small arteries do not warrant preservation, as the recognition of the artery carries with it the appreciation of its companion veins; *the venæ comites of the small arteries may therefore be stripped away from them in the cleaning of the latter.* The large venous trunks run contiguous to the arteries, one to each, and their relations should be carefully noted; special directions will be given, when and how they are to be removed. *In dissecting arteries and veins the same rule holds as with muscles, viz.: that the vessels should not be raised by the forceps, but only the adventitious tissue and venæ comites (in the case of small arteries) are to be drawn away and cut from the surface of the vessel (see the figure illustrating the cleaning of a muscle, Fig. 6, Plate 2), the knife cutting parallel with the vessel, never across it.*

Nerves.—The nerve-trunks of a region will be found to run parallel with its vessels. If not immediately contiguous, they are not far removed. In appreciating a nerve it must be remembered that it is either motor, sensory, or mixed (containing both motor and sensory fibres). If a nerve is motor, its distribution will be to muscle only; if sensory only, it ends at an organ of special sense or the skin; if a mixed nerve, it will be found to have a deep distribution of its motor filaments to the muscles, and a superficial distribution of its sensory filaments to the skin. With the exception of a few nerves in the region of the head, which are either specially sensory or specially motor, the nerves of the body are mixed, having a deep muscle and a superficial skin distribution.

DISSECTION.—In exposing a nerve it should be first isolated for a short portion of its course, as with a subcutaneous nerve (see Fig. 4, Plate 2); then raise the nerve taut with the forceps (see Fig. 5, Plate 2), and with the sharp-pointed scalpel, held with its edge from you and cutting parallel with the nerve, strip out the nerve from the fibrous tissue, in which it is imbedded; as soon as enough of the nerve has been freed, it should be held in the fingers of the left hand and its stripping out continued. Observe the giving off of branches, those to the muscles, those communicating with contiguous nerves, and those to the skin, as the case may be. All the branches of a nerve should be traced to the parts, to which they distribute; the most delicate nerves, when once stripped out, will bear a great deal of handling, and the completeness of a dissection will more than reward the extra pains, taken to preserve them.

The dissector, in his general work, will be able to find, with but few exceptions, all the nerves shown in the plates. In a few of the plates, not original (Plate 33), the nerves were dissected out after the regional sections had been preserved, for a long time, in dilute nitric acid.

Lymphatic Glands.—Lymphatic glands are to be found in given situations in the body; when large they are evidence of a pathological condition, as in the perfect organism they may escape detection.

DISSECTION.—In the course of dissection it is sufficient to recognize the lymphatic glands as they may present, but it is needless to preserve them.

Lymphatic Vessels.—Lymphatic vessels are only recognized in special regions, viz.: the vicinity of the receptaculum chyli and along the left lymphatic or thoracic duct. They are, as a rule, so small elsewhere as to escape detection. Pictures illustrating them are drawn from specimens, where the lymphatic vessels have been injected by special methods necessary therefor.

Viscera.—The viscera of the body are certain organs, contained within the trunk and head; the directions for their dissection will be given in their proper places.

DISSECTION.—The anatomy of a viscus is complete in itself, therefore it may be removed from the body and kept in some preservative fluid—a solution of arsenite of soda or of chloride of zinc—for special dissection. Before removal of an organ from the body, its relations, the source of its arterial and nerve supply, the destination of its vein or veins, and its duct (if it has any) should be recognized, as far as practicable.

Ducts.—Ducts are the efferent canals from the secreting viscera, for the conveyance of the products of secretion; they are found only in the trunk and head regions of the body.

DISSECTION.—The relation of a duct, in situ, is to be first appreciated; then, its point of emergence from the viscus and its destination.

Mucous Membrane.—Mucous membrane lines all canals of the body with a surface outlet; at these points the membrane will be found continuous with the skin.

Serous Membrane.—A serous membrane invests all opposed surfaces, which move upon each other, the exception being the cartilage surfaces of joints; it covers all movable organs, and lines the interior of the cavities which contain them; it lines the ligaments of the movable joints, and forms the sheaths of tendons. It secretes a lubricating fluid to facilitate friction and prevent irritating effects therefrom.

DISSECTION.—Mucous and serous membranes should be dissected from subjacent tissue; a submucous and a subserous plane of areolar tissue may sometimes be demonstrated.

Bones.—The bones, which form the framework of a given dissection, should be considered, with reference: *first*, to the relations of their surfaces to the anatomical elements of the region; *second*, to the areas of attachment of muscles. The regional dissections have been planned so as to include all the attachments of a given muscle, thereby facilitating the appreciation of its function.

DISSECTION.—After a dissection has been completed, the muscles should be cut from the bones, one by one, noting the areas of their attachments. In so doing, not only the situation of a given muscle attachment is to be seen, but also its relations to contiguous areas of other muscle attachments.

Joints.—The joints of the body are the points where bone surfaces are in contiguity; they are complex in their construction, including: *bones, ligaments, cartilage, synovial (serous) membrane, and fibro-cartilage.* Joints are movable, partially movable, and immovable: a *movable joint* (elbow-joint) is constructed of bones covered with articular cartilage, and joined by ligaments lined by synovial membrane; if the joint is exposed to concussions (knee-joint), protection is afforded, from bone injury by the presence of movable plates of fibro-cartilage (interarticular), between the cartilage-covered articular

surfaces of the bones. In other joints (hip-joint) the articular cavities are deepened by the rimming of their borders with immovable fibro-cartilage (circumferential). In the articulation of bones, which form partially movable joints (the vertebræ), cartilage and synovial membrane are wanting, and plates of immovable, fibro-cartilage (interosseous) are fixed between the articular surfaces (intervertebral discs); these latter points of bone articulation allow a slight motion of their surfaces upon each other. In the *immovable joints* (cranial and upper-jaw regions of the head) the articular surfaces of the bones are held in apposition: for the cranium, by the continuity of the exterior periosteum and the interior dura mater; for the upper-jaw region, by the continuity of the periosteum; ultimately, in both regions, the articulations between the bones are obliterated by the development of osseous tissue.

DISSECTION.—In the dissection of joints it is absolutely necessary that they should be moist and pliable; to keep them so, they should be kept covered by refuse tissue, with wrappings of wet muslin, and outside dry muslin or oil-silk. If they have dried from neglect, they should be soaked in water till the ligaments are again pliable. The cleaning of the surface of ligaments may be effected with curved scissors and subsequent scraping with a scalpel.




FIG. 1

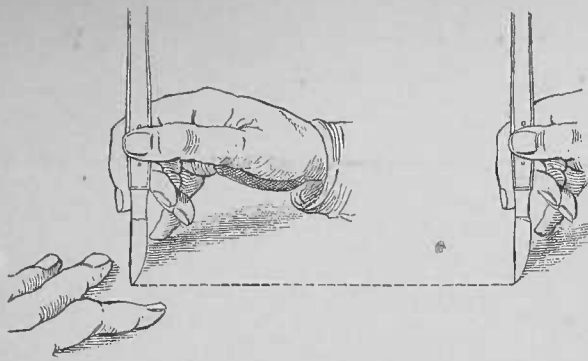


FIG. 2

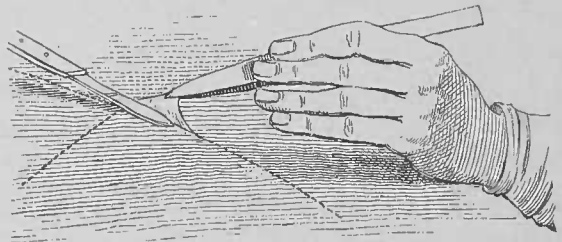


FIG. 3

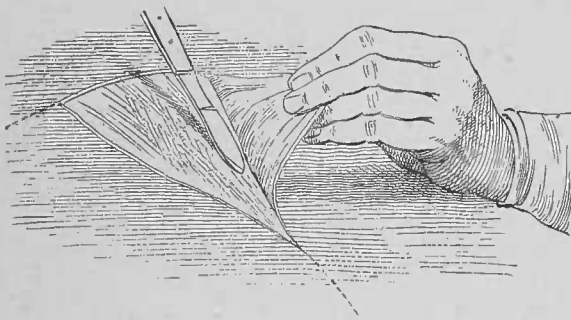


FIG. 4




FIG. 5

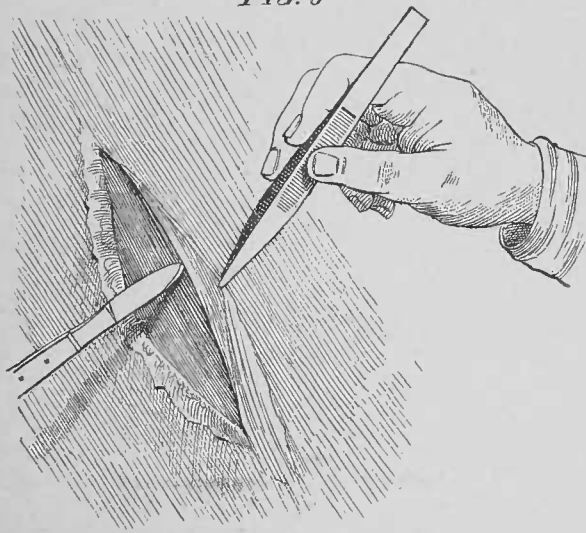



FIG. 5



M. Cohn, ad naturam del.

TRUNK.

FIRST DISSECTION.

MALE PERINEUM.

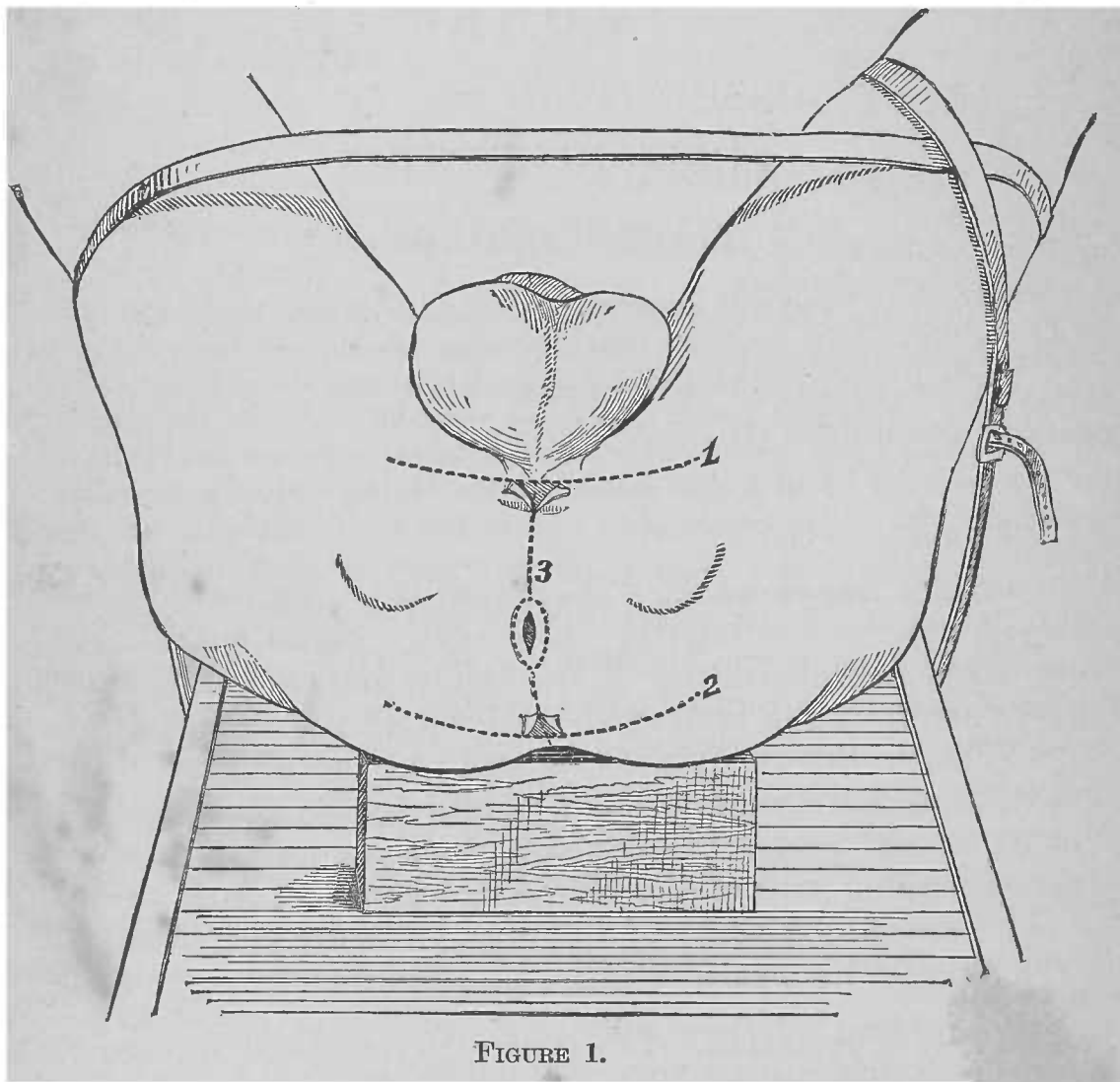
POSITION OF BODY FOR DISSECTION.—Bring the subject to the end of the table, with the lower extremities hanging over; place a block under the pelvis and a second under the shoulders; flex the thighs upon the abdomen and the legs upon the thighs; pass a rope under the table and over the separated limbs, taking a turn around one or both; make the rope taut and tie it (Figure 1, page 14). Pass a steel sound into the bladder and tie the penis and scrotum to it.

Surface Appearances.—The following points are recognized by palpation: posteriorly, the coccyx on the median line; laterally, the tuberosities of the ischia, and extending anteriorly therefrom the rami of the pubic arch; posteriorly to the bis-ischiatic line the anus is located; in the urethral region, on the median line, is a swell formed by the corpus spongiosum of the penis; the exterior of the os pubis lodges the corresponding crus of the corpus cavernosum; from the area of the anterior surfaces of the ossa pubis are suspended the scrotum and the penis.

Terms of Relation.—The general terms (page 2); and the special terms *exterior* and *interior*—relatively to the skin surface and the pelvic cavity, respectively—will be used.

Perineum and its Boundaries, Plate 5.—The perineum includes all the soft parts, which close the inferior outlet of the pelvis or the space bounded by the bones of the pubic arch and the coccyx, and the following ligaments: the inferior pubic, anteriorly, and the right and left great sacro-sciatic, posteriorly and laterally.

Regions of the Perineum.—The perineum is divided by a transverse line, the bis-ischiatic, into a posterior and an anterior region; in the male they are called *rectal* and *wrethral*; in the female *rectal* and *wrethro-vaginal*. The rectal region is bounded by the bis-ischiatic line, anteriorly; the tuberosities of the ischia, the great sacro-sciatic ligaments and the coccyx, laterally and posteriorly. The *wrethral* (male) or



wrethro-vaginal (female) region has the bis-ischiatic line, posteriorly; the rami of the pubic arch—the ascending rami of the ischia and the descending rami and bodies of the ossa pubis—and the inferior pubic ligament, laterally and anteriorly.

Bones and Bone Areas.—The bones are: the coccyx and the pubic arch—parts of the os pubis and ischium of the right and the left os innominatum. To the internal surface and free

borders of a ramus of the pubic arch will be found three lines of fascial attachment, which determine three planes of muscle attachments. The lines are: to the exterior surface and free border, the perineal fascia; to the interior free border and surface, the levator fascia (posterior layer of triangular ligament); to about the middle of the intervening surface between the borders, the triangular ligament (anterior layer). Between the perineal fascia and triangular ligament lines the crus penis or clitoridis and the ischio-cavernosus and superficial transversus perinæi muscles are attached. Between the triangular ligament and levator fascia lines are found the attachments of the deep transversus perinæi and constrictor urethræ muscles. In a plane interior to that of the levator fascia, and interior to the pubic ramus, the levator ani et prostatae (male) or the levator ani et vaginæ (female) muscle presents. The osseous attachments of the compound levator muscle are to the interior surface of the body of the os pubis, anteriorly; the spine of the ischium, laterally; and the border of the coccyx near its apex, posteriorly. The coccygeus muscle is attached to the spine of the ischium and to the interior of the coccyx. The tip of the coccyx and its exterior surface afford attachment, respectively, to the sphincter ani and gluteus maximus muscles.

DISSECTION.—Make the skin incisions marked 1, 2, and 3, Fig. 1, and reflect flaps, laterally, beyond the tuberosities of the ischia, in which positions they may be fixed by thumb-pins.

1. Subcutaneous Tissue, Plate 6.—A plane of thick subcutaneous tissue, containing more or less fat, underlies the skin: it is continuous with that on the thighs and buttocks.

DISSECTION.—Clean the surface of the sphincter ani muscle, exposing its entire contour.

2. Sphincter Ani Muscle.—This muscle is in the subcutaneous plane surrounding the anus. It forms an oval muscle mass attached posteriorly to the tip of the coccyx; as it passes anteriorly it expands, by the divergence of its fibres, to surround the anus; it converges again in front of the anus, and terminates at the tendinous centre of the perineum.

DISSECTION.—Incise the subcutaneous tissue on the median line, anterior to the anterior attachment of the sphincter ani muscle, down to a layer of fascia, the perineal; then diverge incisions along the external borders of the

muscle to the coccyx. Reflect flaps of subcutaneous tissue, similar to those of the skin; seek a subcutaneous nerve on the fascia lata, external to the ramus of the pubic arch.

3. Inferior Pudendal Nerve.—This nerve is a branch of the lesser sciatic, that becomes subcutaneous by piercing the fascia lata, external to the tuberosity of the ischium; it continues anteriorly, external to the urethral region, to distribute to the skin of the external and posterior surfaces of the scrotum. A branch perforates the perineal fascia to communicate with the anterior superficial perineal nerve.

DISSECTION.—Dig out the fat external to the anterior half of the sphincter ani muscle (by scratching through it with the point of the closed curved scissors and picking out the detached portions with the forceps), so as to determine the posterior edge of the perineal fascia.

4. Perineal Fascia.—This fascia constitutes the third plane of the urethral region. It is continued anteriorly from its base line, the bis-ischiatic fascial junction, over the subpubic portion of the penis, and is attached laterally to the exterior surface and free border of the ramus of the pubic arch. Beyond the urethral region it is continued into the dartos tunic of the scrotum. In the dissection of the inguinal region, the scrotum and the penis, we shall find this plane of fascia continued, superiorly, from the scrotum (dartos tunic), as the deep layer of the subcutaneous tissue of the groin and also as a dartos sheath of the penis.

DISSECTION.—Dig out the remaining fat from the ischio-rectal fossa. All strokes, whether of scratching or cutting, should be made at a right angle to the median line, as vessels and nerves, which cross the fossa from its ischial to its rectal wall, would otherwise be severed. Expose the inferior edge of the gluteus maximus muscle. In clearing the fat from the anterior portion of the levator fascia, be careful not to cut through it, but scrape the fat from it so as to preserve its attachment to the bis-ischiatic fascial junction.

5. Gluteus Maximus Muscle, Plate 7.—The inferior edge of this muscle passes from the side of the coccyx, across to and over the exterior surface of the tuberosity of the ischium. Over the muscle edge vessels and nerves (small sciatic branches and the fourth sacral nerve) curve to its exterior surface, for subcutaneous distribution.

6. Ischio-Rectal Fossa.—The fossa is located between the

ischium, externally, and the rectum, internally. Its actual walls are, externally, the inferior portion of the obturator fascia, covering the interior of the obturator internus muscle; internally, the levator ani portion of the levator fascia, covering the exterior of the levator ani portion of the levator ani et prostatae muscle. Its superficial limits are, posteriorly, the inferior border of the gluteus maximus muscle; anteriorly, the base of the perineal fascia. Its shape is that of a wedge with its base at the skin, its sloping sides at the obturator and the levator fascia, respectively, while the junction of the two fasciæ forms the apex of the wedge and the bottom of the fossa.

7. Inferior Hemorrhoidal Artery, Plate 7.—This artery (vena comes), sometimes two, springs from the internal pudic artery in the external wall of the fossa; it bridges the fossa and breaks up into branches, which distribute to the levator and sphincter ani muscles and the skin about the anus.

8. Inferior Hemorrhoidal Nerve.—This nerve, sometimes two, arises from that portion of the pudic nerve which is located in the external wall of the fossa; it crosses the fossa and distributes to the sphincter ani muscle and the skin of the rectal region.

9. Obturator Fascia.—The inferior portion of this fascia forms the external wall of the ischio-rectal fossa, lining the interior surface of the obturator internus muscle, which, in turn, lies upon the interior of the ischium.

10. Levator Fascia.—The levator ani portion of this plane of fascia (*anal fascia* of authors) covers the exterior of the levator ani portion of the levator ani et prostatae muscle, at the internal wall of the ischio-rectal fossa. This fascia is given off from the interior surface of the obturator fascia, which lines the ischio-pubic portion of the pelvic wall. It is attached anteriorly at the bis-ischiatic fascial junction, at the base of the triangular ligament.

DISSECTION.—Introduce the finger upon the obturator fascia, and distinguish beneath the same, on the obturator internus muscle, the pudic vessels and nerve as they pass anteriorly to the urethral region of the perineum. Follow the hemorrhoidal artery or nerve to the external wall of the fossa and incise the obturator fascia so as to expose the pudic vessels and nerve.

11. Pudic Nerve.—This nerve lies exteriorly to the artery, giving off the inferior hemorrhoidal nerve as described above. Posteriorly to the tuberosity of the ischium it gives off the posterior superficial and anterior perineal nerves, which pierce the perineal fascia, anteriorly to its base line of junction with the triangular ligament, that they may distribute, beneath the fascia, in and beyond the urethral region. The trunk of the nerve continues, anteriorly, interiorly to the triangular ligament.

12. Pudic Artery.—This artery (*vena comes*), having re-entered the pelvic cavity from the exterior of the spine of the ischium, runs in the external wall of the ischio-rectal fossa, where it lies interiorly to the pudic nerve, and passes, anteriorly, into the urethral region, interiorly to the triangular ligament. In its transit in the wall of the fossa, it gives off the inferior hemorrhoidal artery; posteriorly or at times internally to the tuberosity of the ischium, it bifurcates into the superficial and the deep perineal arteries.

DISSECTION.—Section the perineal fascia (Plate 6), and reflect flaps of the fascia (Plate 7). Determine the superficial vessels, nerves, and muscles, interiorly to the perineal fascia.

13. Bischiatic Fascial Junction, Plate 7, and Fig. 3, Plate 8.—This is located along the posterior border of the superficial transversus perinæi muscle. It is formed by the junction of the base of the perineal fascia, and the levator fascia, with the base of the triangular ligament.

14. Superficial Perineal Artery, Plate 7.—This artery (*vena comes*), a branch of bifurcation of the pudic, enters the urethral region of the perineum at its posterior external angle, sometimes posteriorly to the base of the triangular ligament, perforating the perineal fascia, at others interiorly to the triangular ligament, perforating it and the perineal fascia. It passes anteriorly, giving off the transverse perineal artery and muscle branches; it also distributes to the scrotum.

15. Superficial Perineal Nerves.—The posterior superficial and the anterior superficial perineal nerves are branches of the pudic nerve; they enter the ischio-rectal fossa and reach their plane of distribution by perforating the perineal fascia close to its base line. They supply the skin of the urethral region

and scrotum. The posterior perineal nerve gives off branches for muscle distribution, and to supply the bulb of the corpus spongiosum.

16. Superficial Transversus Perinæi Muscle.—This muscle extends from the internal surface of the tuberosity of the ischium to the tendinous centre of the perineum.

17. Accelerator Urinæ Muscle.—This muscle is attached to the tendinous centre of the perineum and to a fibrous raphé on the median line. From this raphé its fibres pass externally and anteriorly, moulding themselves upon the half of the corpus spongiosum of the penis. Externally, it is attached to the exterior surface of the triangular ligament; anteriorly, its fibres pass, over the side of the corpus cavernosum of the penis, for attachment on the dorsum of the same.

18. Tendinous Centre of the Perineum, Plate 7, and Fig. 3, Plate 8.—This is a fibrous tissue centre, determined by the convergence of muscles and fasciæ, viz.: the sphincter ani, the superficial and deep transversi perinæi, the acceleratores urinæ and the levatores ani et prostatæ muscles; the right and left perineal fasciæ, the triangular ligament, and the right and left levatores fasciæ.

19. Ischio-Cavernosus Muscle (Erector penis), Plate 7.—This muscle is attached to the internal surface of the tuberosity of the ischium and to the crus of the corpus cavernosum of the penis.

DISSECTION.—Section the superficial perineal artery and nerves, and the inferior pudendal nerve (Plate 7), and reflect them anteriorly upon the scrotum. Section the ischio-cavernosi, superficial transversi perinæi, and acceleratores urinæ muscles (Plate 7), and reflect the portions of each. The tendinous centre of the perineum is not to be cut away.

20. Corpus Spongiosum of the Penis, Plate 8.—The subpubic portion of the corpus spongiosum of the penis occupies the median line of the urethral region. Its posterior portion, which expands into what is called the *bulb*, lies exterior to the triangular ligament and is invested by the acceleratores urinæ muscles; its anterior portion, or *body*, continues inferior to the corpora cavernosa; it forms the inferior longitudinal cylinder of the penis, and expands into the glans penis.

21. Crus of the Penis, Plate 7, and Fig. 3, Plate 8.—This is attached to the free surface of the pubic arch; it extends anteriorly, and internally, upon the exterior of the descending ramus and body of the os pubis. At the median line, exterior to the symphysis pubis, the right and left crus unite to form the corpora cavernosa of the penis, which are the superior longitudinal cylinders of that organ.

DISSECTION.—Hook the bulb of the corpus spongiosum internally and clear the surface of the triangular ligament, respecting vessels and nerves, which perforate the same.

22. Triangular Ligament, Fig. 1, Plate 8.—This ligament is a triangular sheet of dense fibrous tissue, attached to the rami of the pubic arch (see Bone Areas, p. 14). It occupies a plane interior to the muscles, described above, the corpus spongiosum and the crura of the penis. Its base has an attachment to the tendinous centre of the perineum, and with the perineal and levator fasciæ forms the bis-ischiatic fascial junction. It is pierced, near its base, externally, at times, by the superficial perineal artery, internally, by the artery of the bulb; toward its apex, by the deep perineal artery or its terminal branches; and by the dorsalis penis nerve and vein.

DISSECTION.—Cut one of the crura, from its attachment to the pubic arch, and hook it internally across the corpus spongiosum, then clear the vessels and nerve, that come through the triangular ligament.

23. Artery to the Corpus Cavernosum, Figs. 1 and 2, Plate 8.—This artery (vena comes) is the largest branch of bifurcation of the deep perineal; it divides into branches, which enter the deep surface of the crus of the corpus cavernosum.

24. Deep Dorsalis Penis Artery.—This artery is the smaller branch of bifurcation of the deep perineal; it passes, anteriorly, between the crus of the corpus cavernosum and the body of the os pubis.

25. Deep Dorsalis Penis Nerve.—This nerve is a continuation of the deep perineal nerve, exterior to the triangular ligament; it accompanies the artery of the same name.

26. Deep Dorsal Vein of the Penis.—The lateral surface of this vein presents, running internal to, and parallel with, the

dorsal artery and nerve, upon the exterior of the body of the os pubis.

DISSECTION.—Section the triangular ligament (Fig. 1, Plate 8), and reflect its portions; laterally, to the pubic arch; posteriorly, so as to retain its continuity with the bis-ischiatic fascial junction; this will display the deep perineal vessels, and a portion of the deep perineal nerve. These elements will be found to lie upon the exterior surface of the deep transversus perinæi and the constrictor urethræ muscles.

27. Deep Perineal Artery, Fig. 2, Plate 8.—This artery (vena comes) is one of the branches of bifurcation of the pudic; it runs parallel with, and internal to, the pubic arch, in a plane interior to the triangular ligament; it bifurcates into the artery of the crûs and the dorsalis penis artery, as described above.

28. Artery of the Bulb.—This artery (vena comes) is a branch of the deep perineal, which passes internally and anteriorly, to perforate the triangular ligament and distribute to the corpus spongiosum. As it enters the part it bifurcates into a posterior branch to the bulb and an anterior branch to the body.

29. Artery to Cowper's Gland.—In its course the artery of the bulb gives off a branch, which passes, internally and posteriorly, to a point posterior to the bulb of the corpus spongiosum, where it pierces the deep transversus perinæi muscle to distribute to the gland, which lies interior to the muscle.

30. Deep Perineal Nerve.—This nerve lies between the deep perineal artery and the ramus of the pubic arch; it runs for a portion of its course interior to the pubic arch attachments of the deep transversus perinæi and constrictor urethræ muscles; it is the branch of the pudic nerve, which continues the trunk into the urethral region; piercing the triangular ligament, it becomes the dorsalis penis nerve, as described above.

DISSECTION.—Section the deep perineal artery (Fig. 2, Plate 8), and reflect it and its branches internally across the corpus spongiosum; clear the surface of the muscles upon which the artery lies.

31. Deep Transversus Perinæi Muscle.—This muscle consists of transverse fibres, which run, parallel with and anterior to the base of the triangular ligament, from the tuberosity of

the ischium, externally, to the tendinous centre of the perineum, internally.

32. Constrictor Urethræ Muscle.—This muscle is formed of transverse fibres, which are attached, externally, to the free surface of the pubic arch, anterior to the attachment of the preceding muscle; internally, at the median line, they meet at a, more or less well marked, raphé, the fibres of the muscle of the opposite side, and surround the membranous portion of the urethral canal.

DISSECTION.—Unhook the crus and the corpus spongiosum; restore the crus to its normal position; hook the bulb of the corpus spongiosum a little anteriorly; expose Cowper's glands, by dissecting off the fibres of the deep transversus perinæi muscles, as they converge to the tendinous centre of the perineum.

33. Cowper's Glands, Fig. 3, Plate 8.—These are two bodies, located in the urethral region of the perineum, interiorly to the fibres of the deep transversi perinæi muscles; their ducts run, superiorly, parallel with, and exteriorly to, the wall of the urethra, to open at the floor of the bulbous section of the spongy portion of the urethral canal (page 2; Fig. 2, Plate 55).

DISSECTION.—Section the gluteus maximus muscle (Plate 7) and reflect the flap inferiorly. Section the constrictores urethræ and deep transversi perinæi muscles, antero-posteriorly, and reflect the portions, laterally; the pubic arch attachment may be cut away. In removing this plane of muscle be careful not to injure a subjacent plane of fascia.

34. Great Sacro-Sciatic Ligament, Fig. 3, Plate 8, and Plate 9.—The inferior edge and a portion of the exterior surface of this ligament are brought into view; the ligament extends from the border of the coccyx to the tuberosity of the ischium, in a plane interior to the gluteus maximus muscle.

35. Fourth Sacral Nerve.—This nerve perforates the great sacro-sciatic ligament, to wind over the inferior border of the gluteus maximus muscle, near the coccyx, for distribution to the skin of the coccygeal region.

36. Levator Fascia (anal fascia and posterior layer of the triangular ligament), Fig. 3, Plate 8.—This fascia, already partially shown in Plate 7, now presents as a plane of fascia common to both the rectal and urethral regions of the perineum.

It will be recognized as including, in one continuous fascia, the so-called *anal fascia* of the rectal region and the so-called *posterior layer of triangular ligament* of the urethral region. As the fascia covering the obturator muscle is called *obturator fascia*, this plane of fibrous tissue may be called *levator fascia* as it invests the exterior surface of the levator ani et prostatae muscle. The levator fascia, externally, is given off as an *internal process from the obturator fascia*, inferior to the obturator fascia attachment of the levator ani et prostatae muscle. It is thus given off inferior to "the white line" or the splitting of the pelvic fascia—from the interior of the body of the os pubis, anteriorly, to the spine of the ischium, posteriorly—into the obturator and recto-vesical fasciæ. From its external attachment it spreads to the median line, exterior to the levator ani et prostatae muscle.

In the rectal region, the *levator ani portion* of this plane of fascia (*anal fascia*) forms the internal wall of the ischio-rectal fossa; it passes from its attachment to the obturator fascia and the spine of the ischium, externally; to the median line anterior to the anus—it is here attached to the tendinous centre of the perineum—to the wall of the rectum, to the median line between the anus and the coccyx, and to the coccyx, internally. Its posterior limit is at the inferior edge of the coccygeus muscle.

Continued from the obturator fascia on the interior of the pubic arch, the *levator prostatae portion* of the levator fascia (*posterior layer of triangular ligament*) occupies the urethral region of the perineum; externally, it lines the interior surface, and springs from the interior lip of the internal free border, of the ramus of the pubic arch; internally, it reaches the median line, where it meets its fellow of the opposite side, and the two surround and give transit to the prostatic end of the membranous urethra. At its median line limit it attaches itself to the portion of the recto-vesical fascia which forms the prostatic capsule; and to the tendinous centre of the perineum. *At the bis-ischiatric fascial junction the levator fascia is attached, which attachment divides it into its levator ani and levator prostatae portions.*

37. Membranous Portion of the Urethra, Plates 10, 11, and 12.—This portion of the urethral canal is located in the interval between the bulb of the corpus spongiosum, exteriorly,

and the anterior extremity or apex of the prostate, interiorly; it is included between two planes of fascia, the triangular ligament (anterior layer), exteriorly, and the levator prostatae portion of the levator fascia (posterior layer of triangular ligament), interiorly; it is surrounded by muscle tissue, contributed by the junction of the right and left constrictor urethrae muscles.

DISSECTION.—Dissect the levator fascia from the exterior surface of the levator ani et prostatae muscle, leaving a rim of the fascia at the circumference of the pelvic outlet (Plate 9); distinguish the two portions of the muscle, and the convergence of the muscles, the right and the left, at their median-line raphe, posteriorly and anteriorly to the anus.

38. Levator Ani et Prostatae Muscles, Plates 9, 45, and 46.

—These muscles, the right and the left, close the outlet of the bony pelvis. A muscle, of a side, is attached, antero-posteriorly, as follows: externally, to the interior surface of an os pubis (levator prostatae), to the open angle of the splitting of the pelvic fascia (into the recto-vesical and the obturator fasciæ), and to the spine of the ischium (levator ani); internally, to a median line raphe and to the tendinous centre of the perineum (levator prostatae), to the wall of the rectum (levator ani), and to the coccyx. The *prostatae* portions of the muscles present a subpubic interspace, which gives transit to the urethra, and then join to form a sling for the prostate. Their *ani* portions are separated for the outlet of the rectum, the *anus*.

The *levator ani portion of the muscle* plane occupies the rectal region of the perineum; externally, it is attached, antero-posteriorly, to the inferior open angle—the “white line”—of splitting of the pelvic fascia—from the interior of the body of the os pubis to the spine of the ischium—and to the spine of the ischium; internally, its fibres are attached, antero-posteriorly, to the tendinous centre of the perineum, to the wall of the rectum, to a median line raphé from the anus to the coccyx, and to the coccyx itself.

The *levator prostatae part of the muscle* plane is formed by its anterior portion. It is attached, anteriorly, to the interior of the body of the os pubis, from which the fibres pass, posteriorly, parallel with the median line, to a point opposite the interval between the urethra and the anus; the fibres then curve to a median line raphé, which in turn is attached to the tendinous centre of the perineum. This median line junction of

the right and left muscle is located inferior to the prostate, thus slinging it and elevating it when in action.

39. Coccygeus Muscle, Fig. 3, Plate 8, and Plates 9 and 10.—Only a limited portion of the inferior border of this muscle is brought into view, bridging between the spine of the ischium, externally, and the coccyx, internally. It lies in a plane interior to the sacro-sciatic ligament, and is met, anteriorly by the posterior border, of the levator ani portion, of the levator ani et prostatae muscle.

DISSECTION.—The relations of the pelvic viscera, at the outlet of the pelvis, may now be determined, by sectioning the levatores ani et prostatae muscles (Plate 9). Remove the internal portions of the opposite muscles, leaving a fringe of muscle (Plates 10 and 11), projecting external to the sphincter ani muscle (thus left, its attachment to the rectum can be appreciated, when the latter is specially dissected).

40. Recto-Vesical Fascia, Plates 10 and 46.—This fascia is situated interiorly to the levator ani et prostatae muscle. It is given off as an internal process from the pelvic fascia at “the white line” or antero-posterior splitting of the pelvic fascia into recto-vesical and obturator fasciæ; it covers the exterior surfaces of the rectum and bladder, forming a sling for their support at the outlet of the pelvis; it forms the lateral and anterior true ligaments of the bladder, and surrounds the rectum inferior to the pelvic portion of the peritoneum.

DISSECTION.—To expose the portions of the viscera at the outlet of the pelvis, located exterior to the peritoneum, place a hook in the bulb of the corpus spongiosum and pull the prostate and bladder anteriorly; dissect the rectum from the recto-vesical fascia septum and reflect it, posteriorly, until the entire contour of the prostate is exposed.

41. Recto-Vesical Fascia Septum, Plate 11.—The recto-vesical fascia projects a septum between the rectum, posteriorly and inferiorly, and the prostate, bladder, etc., anteriorly and superiorly.

DISSECTION.—Drag the prostate and bladder still more anteriorly, pull the rectum further out of the pelvic cavity, by dissecting it from the base of the bladder and reflecting it posteriorly. Dissect off the vesical layer of the recto-vesical fascia from the prostate (to which it will be found intimately adherent, as a fibrous capsule); reflect the fascia as a flap, posteriorly, from the prostate and the base of the bladder, upon the rectum, exposing the vasa deferentia, the vesiculæ seminales, and a venous plexus external to the latter.

At the base line of the vesiculæ seminales, recognize a thin fibrous tissue, peritoneum, bridging from the bladder to the rectum. In reflecting the flap of fascia, it will be found but loosely adherent to the base of the bladder; at the line of the vas deferens, the fascia splits to include this duct and the vesicula seminalis; external to the vesicula the fascia again becomes single, investing the venous plexus and bladder. Its investiture of both bladder and rectum stops at the peritoneal cul-de-sac.

42. Prostate, Plate 12.—The inferior convex surface of this organ presents—having the shape of a heart on a playing-card—its apex anteriorly; its base, posteriorly, with a cleft in it, for entrance of the ejaculatory ducts.

43. Peritoneal Recto-Vesical Cul-de-sac.—At the superior limit of the exposed portions of the rectum and bladder, the peritoneum will be seen to be reflected from one to the other, forming the bottom of a pouch of peritoneum, located between the two organs.

44. Trigone.—This name is given to a triangular area on the exterior surface of the base of the bladder—bounded by the peritoneal cul-de-sac at its base, the vasa deferentia laterally, and the cleft in the base of the prostate at its apex—because it is opposite the trigone area of the interior of the organ. Giving the same name to the two surfaces facilitates the appreciation of their relations.

45. Vasa Deferentia.—These ducts form the lateral limits of the exterior trigone area; they pass from the apices of the base line of the trigone, to the cleft in the base of the prostate. As they enter the prostate they receive the ducts of the vesiculæ seminales; the joining of the two ducts, on either side, form the two ejaculatory ducts.

46. Vesiculæ Seminales.—These organs lie external to, and parallel with, the vasa deferentia; they are club shape, with their clubbed ends, posteriorly, at the base line of the trigone; they converge, anteriorly, to the cleft in the base of the prostate, where, as seen above, they present ducts, which join the vasa deferentia.

47. Venous Plexus.—A plexus of veins presents, on either side, external to, and parallel with, the prostate and vesiculæ seminales; they are united by a transverse vein or veins along

the base of the prostate, and they receive the dorsal veins of the penis. They are situated between the recto-vesical fascial septum and the bladder.

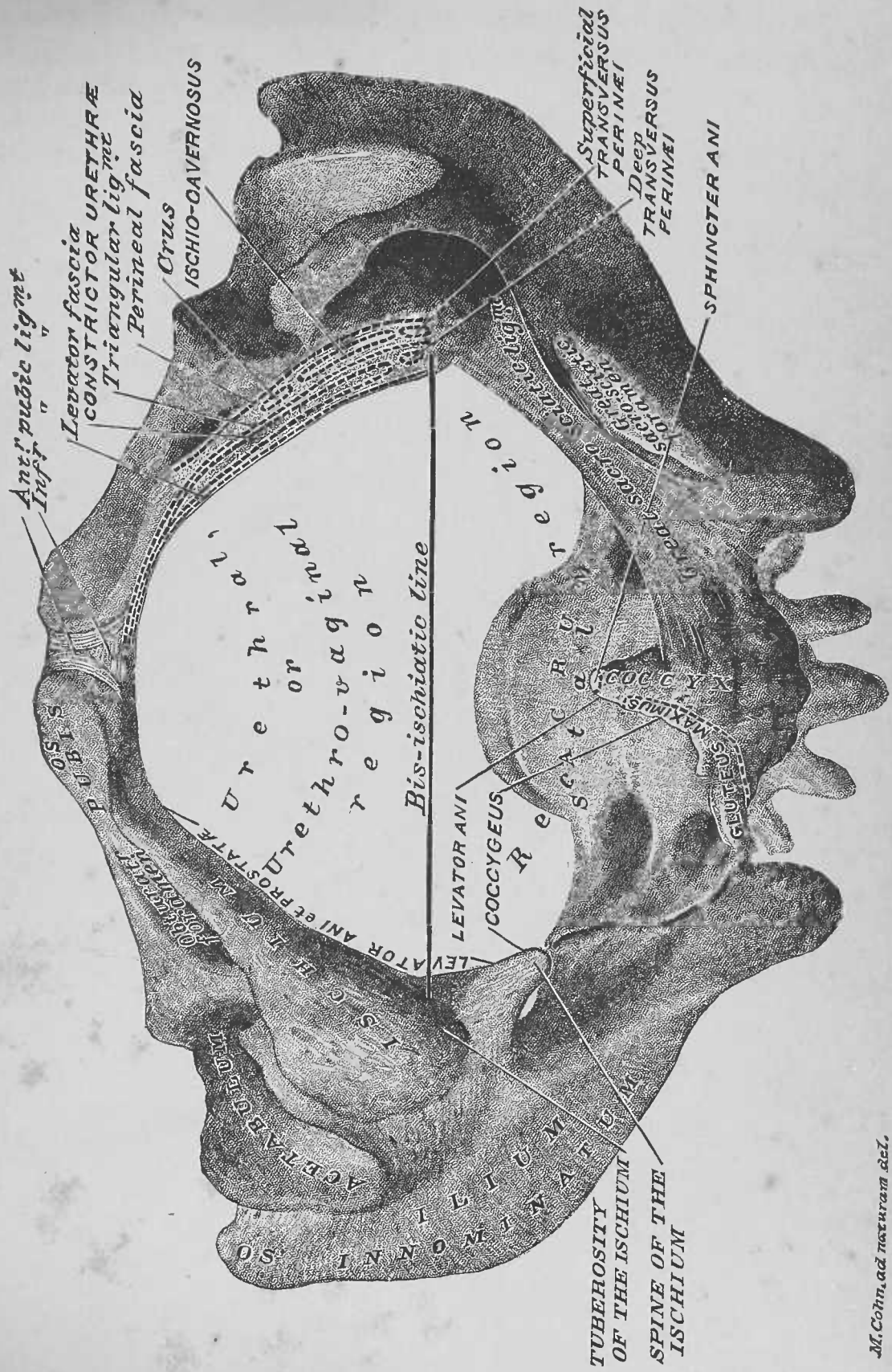
48. Rectum, Plates 11 and 12.—The third, and the anterior surface of the inferior part of the second, portions of the rectum are brought into view in the exposure of the viscera at the outlet of the male pelvis. The third portion is projected from the apex of the coccyx to the anus; it is surrounded by areolar tissue and fat, which are lodged, as we have seen, in the right and left ischio-rectal fossæ (page 16; Plate 6). A triangular, complex mass of tissue exists between the anterior surface of the third portion of the rectum, posteriorly, and the inferior surface of the prostate and the membranous portion of the urethra, anteriorly: the apex of the space is at the junction of the prostate and the rectum; its base is at the skin area between the anus and the scrotum; this portion is called the *surgical perineum*, as it is involved in perineal operations. The antero-superior surface of the second portion of the rectum is in contiguity with the prostate, the vesiculæ seminales, the vasa deferentia, and the bladder. The wall of the rectum presents longitudinal muscle-fibres for the entire circumference of the canal; as pulled out from the pelvis it appears, in the plates, much too broad at its superior end, thereby distorting it as to length.

49. Middle Hemorrhoidal Arteries, Plate 12.—The terminal branches of these arteries, the right and the left, are seen to distribute to the gut at its lateral surfaces.

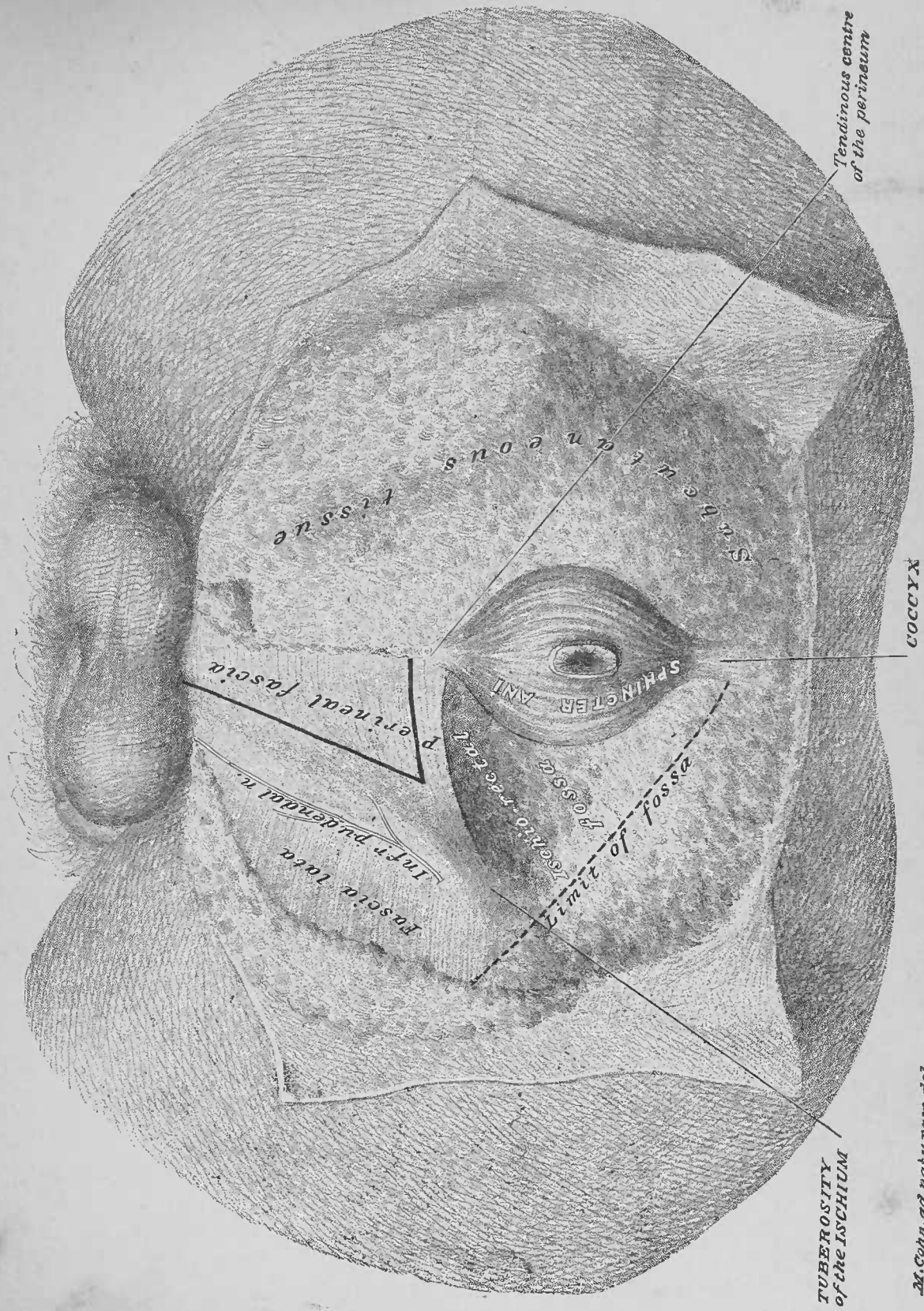
50. Male and Female Inferior Pelvic Outlets.—The inferior outlet of the male pelvis (Plates 9 to 12 inclusive) presents a marked contrast to the same outlet of the female pelvis (Plates 17, 18 and 19). The short transverse diameter and the narrow arch of the ossa pubis in the male give the effect of a greater antero-posterior diameter for the male; this, however, is not the case. Plate 5 represents the inferior outlet of a female pelvis; this selection was purposely made, because the female pelvic outlet is of more practical importance than the male, while it illustrates, for both sexes, the bone areas affording attachments to muscles and fasciæ. Of the muscle attach-

ments in Plate 5 those given for the levator ani et prostatae are also those for the levator ani et vaginae.

DISSECTION.—The dissection of the perineum, the sub-peritoneal viscera, and portions of viscera, at the outlet of the pelvis, being now completed, the viscera should be returned to the pelvic cavity; the skin-flaps of the perineum should be brought together at the pelvic outlet, and the same sutured, by the continued suture, along the median line.



M. Cohn, ad naturam del.



**TUBEROSITY
of the ISCHIUM**

**Tendinous centre
of the perineum**

COCCYX

M. Cohn, ad naturam del.

Post? superficial perineal n.
Ant? "
Superficial perineal art.
Inf? pudendal n.

Tendinous
centre of the
perineum

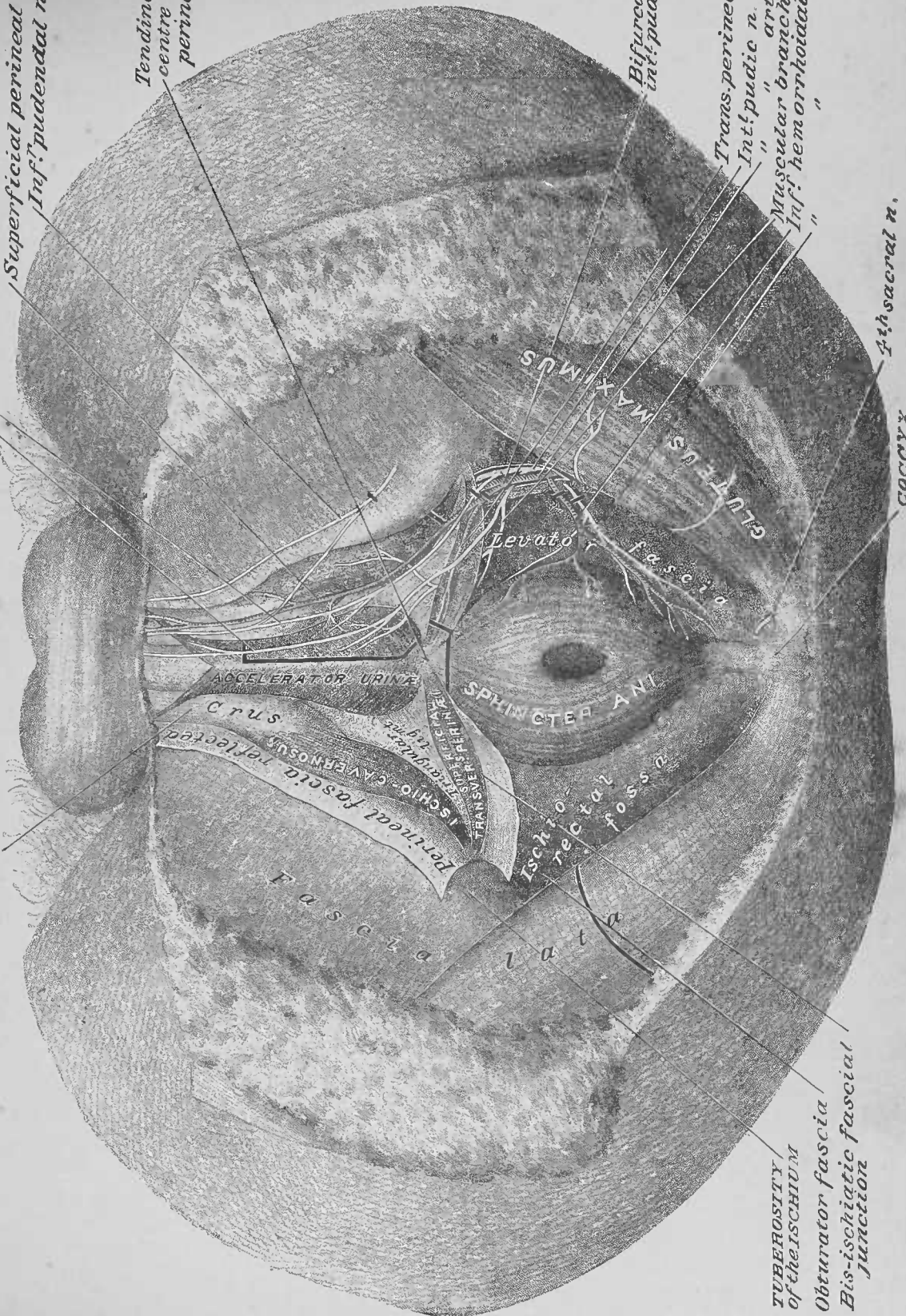
Bifurcation of
int? pudic art.

Trans. perineal art.
Int? pudic n.
Muscular branch
Inf? hemorrhoidal art.
" "

4th sacral n.

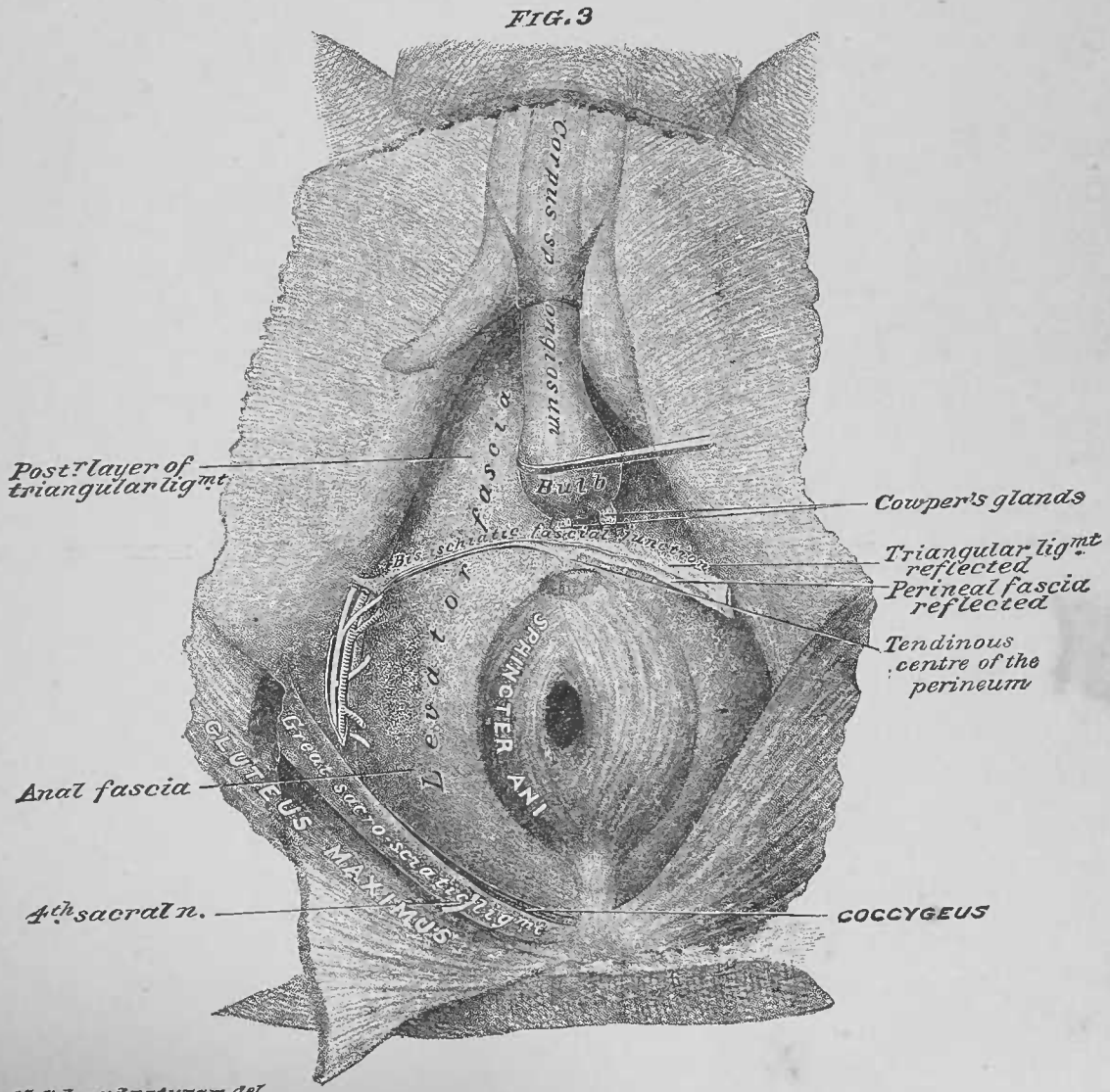
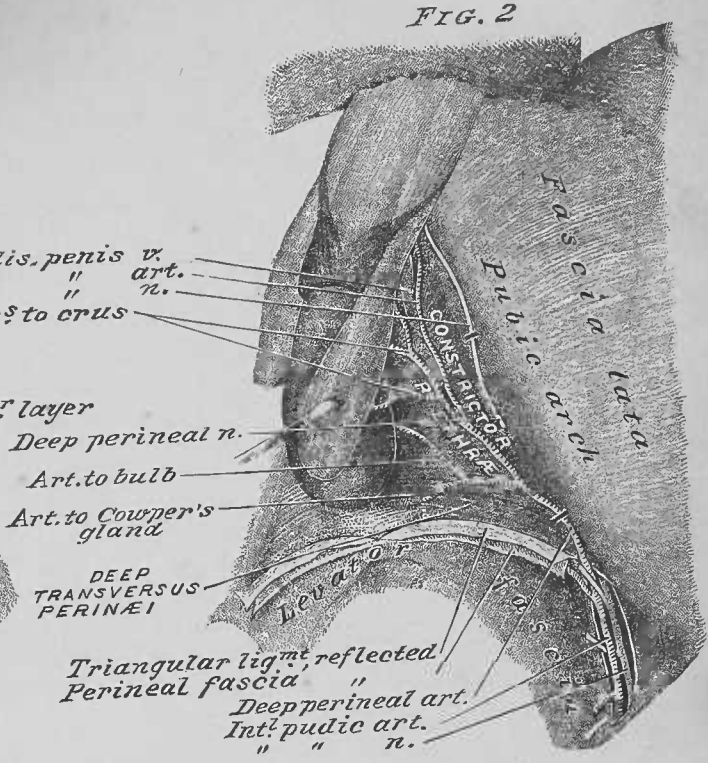
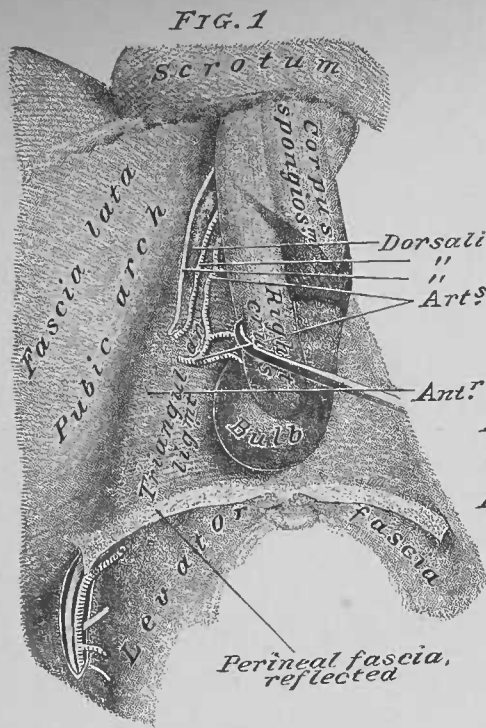
COCCYX

Corpus cavernosum

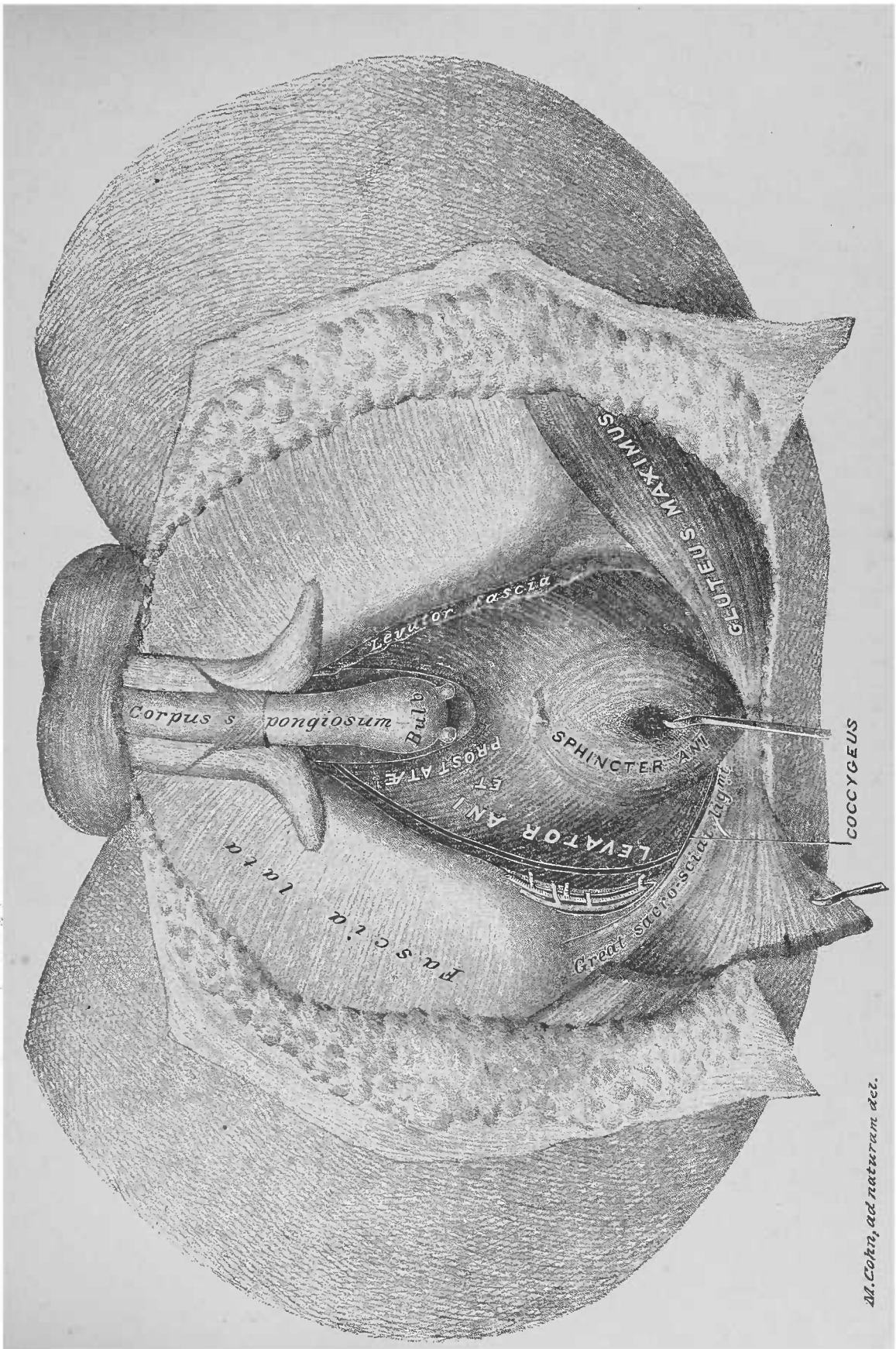


TUBEROSITY
of the ISCHIUM
Obturator fascia
Bis-ischiatic fascial
JUNCTION

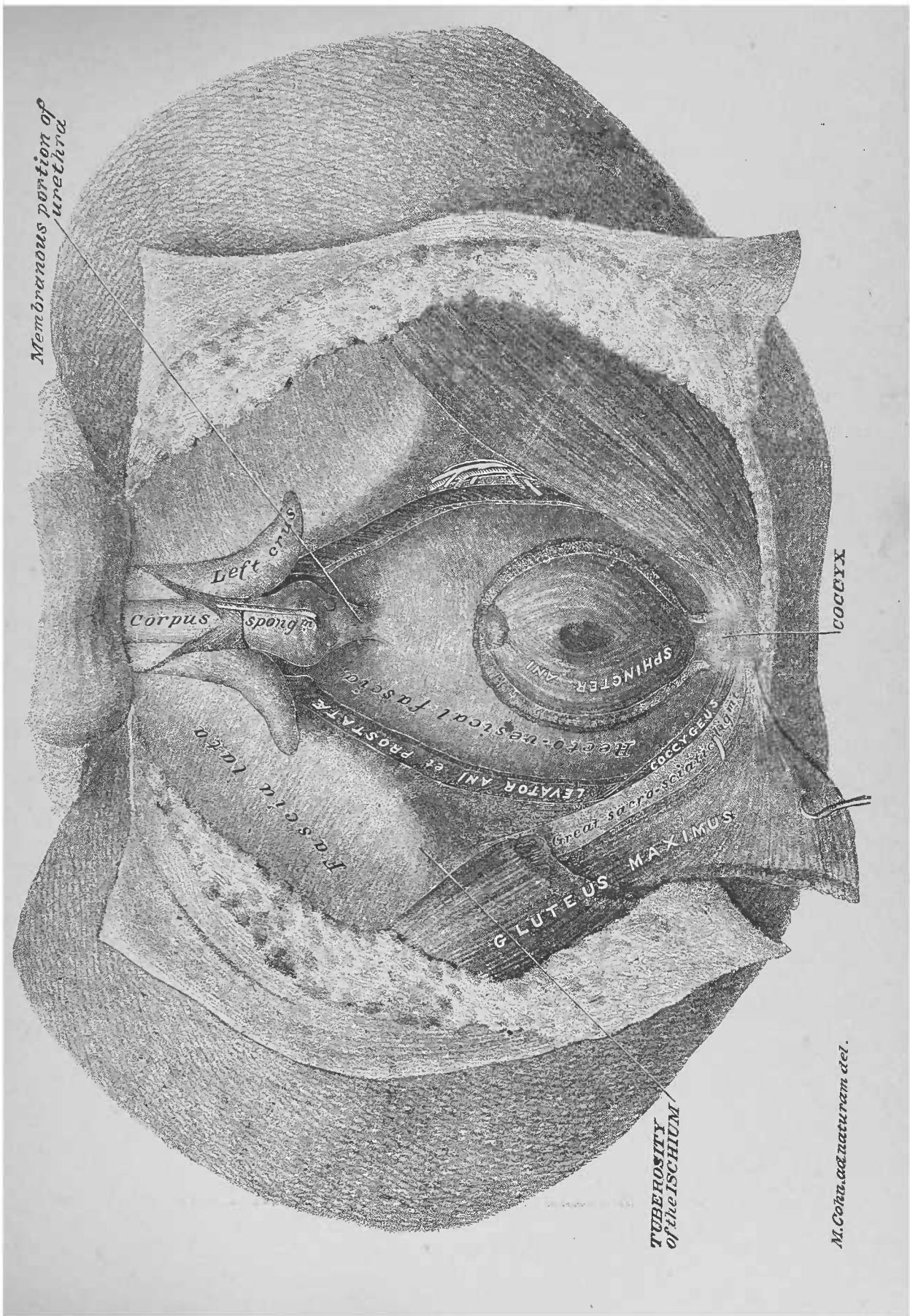
M. Cohn, ad naturam del.

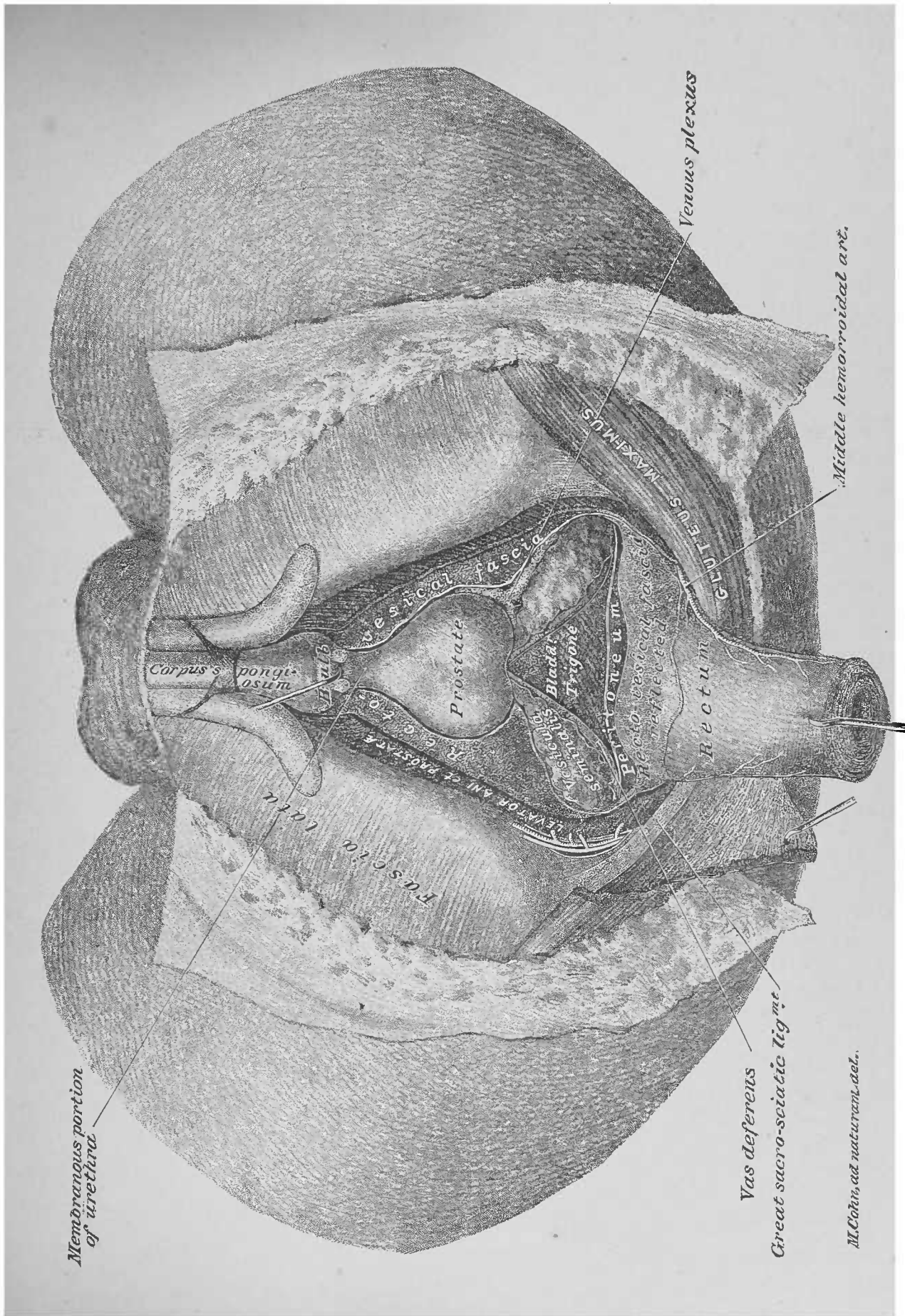


M. Cohn, a.d. naturam del.



M. Cohn, ad naturam del.





SECOND DISSECTION.

FEMALE PERINEUM.

POSITION OF THE BODY FOR DISSECTION, Figure 2 (page 31).—Place the subject in the same position as for dissection of the male perineum, page 13.

Regional Appearances.—Palpation recognizes the same bone contours as in the male; see Male Perineum, page 13. As compared with the male, the region presents the following differences: in the greater diameters of the pelvic outlet; in the anus being located nearer the coccyx; and in the external genitalia.

Terms of Relation.—See Male Perineum, page 13.

Perineum and its Boundaries, Plate 5.—The female perineum includes all the soft parts, closing the outlet of the pelvis. It is bounded by bones and ligaments, as in the male; see Male Perineum, page 13.

Regions of the Female Perineum.—The transverse or bischiatic line of the pelvic outlet divides the female perineum into the *rectal* region, posteriorly, and the *urethro-vaginal* region, anteriorly; see Male Perineum, page 14.

Bone-Areas.—See Male Perineum, page 14.

External (exterior) Genitalia.—These parts occupy the urethro-vaginal region of the perineum and the anterior surfaces of the ossa pubis; they collectively form the *pudendum*, which presents, antero-posteriorly, the *uro-genital furrow*. They include: *a*, Mons veneris; *b*, Labia majora; *c*, Clitoris; *d*, Labia minora; *e*, Vestibule; *f*, Meatus urinarius; *g*, Vaginal orifice; *h*, Orifices of the ducts of the vulvo-vaginal glands; *i*, Fourchette; *j*, Fossa navicularis; *k*, Vulvo-vaginal glands and their ducts (described page 38).

a. Mons Veneris.—This is the area upon the exterior surface of the symphysis pubis and the bodies of the ossa pubis; it is a cushion of adipose tissue, covered by skin; in the adult the skin presents a growth of hair.

b. Labia Majora.—These are two antero-posterior lips, analogues of the halves of the male scrotum, which are divided, on the median line, by the *uro-genital furrow*. Posteriorly, the labia are joined to form the *posterior commissure*; anteriorly, they are approximated only, and are, respectively, continued into the inguinal region of a side. Externally, a labium is covered by skin, which, in the adult, is furnished with hair; internally, or in the uro-genital furrow, its surface is covered, exteriorly, by skin, and interiorly, by mucous membrane. The skin lining of the furrow is richly supplied with sebaceous glands; the mucous-membrane lining is continued into the vagina, urethra, and ducts of the vulvo-vaginal glands.

c. Clitoris.—This is located at the anterior of the uro-genital furrow; it is the analogue of the male penis, from which it differs in size, and in not being tunnelled by the urethra.

d. Labia Minora.—These are two folds of mucous membrane, which form the analogue of the skin and prepuce of the male penis. Anteriorly, they join upon the anterior of the clitoris, to form its prepuce; posteriorly, they diverge into two labia, which merge into the anterior halves of the uro-genital-furrow surfaces of the labia majora.

e. Vestibule.—This is a triangular area of mucous membrane at the middle of the floor of the uro-genital furrow; it has: the clitoris, at its apex, anteriorly; the vaginal orifice, at its base, posteriorly; the labia minora, at its sides.

f. Meatus Urinarius.—This, the outlet of the urethra, presents on the median line of the vestibule, anteriorly to its base.

g. Vaginal Orifice.—This is located: posteriorly to the vestibule; anteriorly to the posterior commissure of, and between the posterior halves of, the labia majora. It may be occluded by a membrane—the *hymen*—or rimmed by the remnants of the same—the *carunculæ myrtiformes*.

h. Orifices of the Ducts of the Vulvo-Vaginal Glands.—These openings are located exterior to the plane of the hymen or carunculæ myrtiformes, upon the internal surfaces of the labia majora, about opposite the middle of the antero-posterior diameter of the vaginal orifice.

i. The Fourchette.—This is a band of mucous membrane, which bridges between the labia majora, exteriorly to the posterior border of the vaginal orifice.

j. The Fossa Navicularis.—This is a depression, located between the fourchette and the posterior commissure of the labia majora.

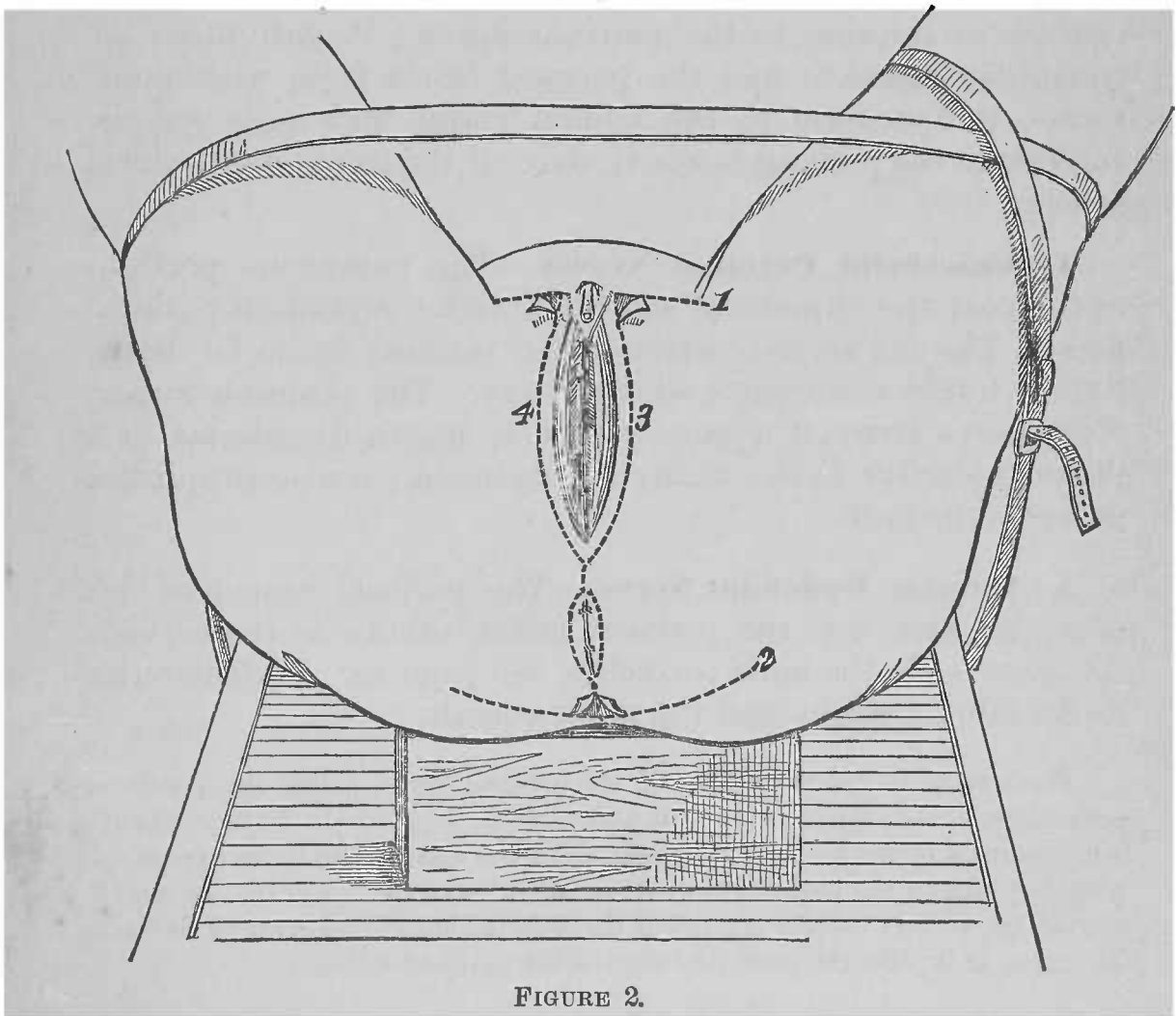


FIGURE 2.

DISSECTION.—Distend moderately the rectum and vagina, by stuffing them with oakum. Close the labia majora, posterior to the clitoris, by six or eight interrupted sutures; also, the anus by two or three sutures. Make the skin incisions 1, 2, 3, and 4, indicated in Fig. 2; reflect flaps of skin over the tuberosities of the ischia, pinning them to the thighs.

1. Subcutaneous Tissue.—A plane of subcutaneous tissue presents as in the male (Plate 6), but containing more fat.

DISSECTION.—Clear the surface of the sphincter ani muscle. Expose the superficial perineal artery and nerves in the urethro-vaginal region; also, the inferior pudendal nerve, external to the region.

2. Sphincter Ani Muscle, Plate 13.—The muscle presents as in the male, except that the muscle mass, constituted by the right and left halves, is more circular, making it shorter antero-posteriorly; it is located nearer the coccyx.

3. Superficial Perineal Artery.—This artery (*vena comes*) differs from the same vessel in the male, in that it is exterior, instead of interior, to the perineal fascia; it perforates the triangular ligament and the perineal fascia from within outwards, to distribute to the labium majus and mons veneris. Interior to the perineal fascia it gives off the transverse perineal artery.

4. Superficial Perineal Nerves.—The cutaneous portions of the posterior superficial and the anterior superficial perineal nerves, like the artery, perforate the perineal fascia for distribution to the same parts as the artery. The posterior superficial nerve gives off a muscle branch, which distributes in a plane exteriorly to the triangular ligament; it also supplies a nerve to the bulb.

5. Inferior Pudendal Nerve.—The perineal branch of this nerve is exterior to the perineal fascia, otherwise the nerve is the same as in the male perineum, see page 16. It distributes to the labium majus and the mons veneris.

DISSECTION.—Clear the surface of the perineal fascia, noting the points of perforation of the superficial vessels and nerves. Dig out the fat from the anterior portion of the ischio-rectal fossa, as in the male (Plate 6), to expose the posterior edge of the perineal fascia; see Male Perineum, page 16. In removing the fat, be very careful not to cut through the anterior portion of the levator fascia, as it joins the posterior edge of the perineal fascia.

6. Perineal Fascia.—See Male Perineum, page 16. In the female, this fascia, in addition to the lateral and posterior attachments of the male, forms a layer of the labium majus, and passes, anteriorly, into the inguinal region, to be continuous with the deep layer of its subcutaneous tissue. Upon the

labium it presents dartos muscle fibres, thus bearing out the analogy of a labium to the half of the male scrotum. Its posterior border, as it forms the anterior superficial boundary of the ischio-rectal fossa, will be noticed to dip more posteriorly than in the male, for attachment to the tendinous centre of the perineum.

DISSECTION.—Section the superficial perineal artery and nerves, also the inferior pudendal nerve posteriorly, and reflect them anteriorly. Complete the removal of the fat from the ischio-rectal fossa, as in the male perineum, see page 16.

7. Gluteus Maximus Muscle.—See Male Perineum, page 16.

8. Ischio-Rectal Fossa.—This fossa, in the female, is broader and less deep than in the male; therefore its shape is less that of a wedge. See Male Perineum, page 16.

9. Inferior Hemorrhoidal Artery and Nerve.—See Male Perineum, page 17.

10. Obturator Fascia.—The portion of this fascia that forms the external wall of the ischio-rectal fossa, has less depth than in the male. See Male Perineum, page 17.

11. Levator Fascia (levator ani portion or anal fascia).—In the female, this fascia is less vertical than in the male, and it has a larger area. See Male Perineum, page 17.

12. Pudic Nerve and Artery.—These parts are similarly located, and may be exposed in the same way as in the male. See Male Perineum, pages 17 and 18.

DISSECTION.—Section and reflect the perineal fascia (Plates 13 and 14).

13. Bis-Ischiatic Fascial Junction, Plates 14 and 17, and Fig. 3, Plate 16.—This transverse line of meeting of the fasciæ of the perineum differs from the male, in that, it extends more posteriorly for attachment to the tendinous centre of the perineum. See Male Perineum, page 18.

14. Superficial Transversus Perinæi Muscle, Plate 14.—See Male Perineum, page 19. It differs in the female in being much less developed, and passes more posteriorly to reach the tendinous centre of the perineum.

15. Sphincter Vaginæ Muscle.—This muscle is the analogue of the accelerator urinæ muscle in the male. Examining one-half of this (so-called) sphincter, it will be found to extend from a broad posterior extremity, at the angle of continuity of the bases of the perineal fascia and triangular ligament; at the median line, posteriorly, some of its fibres converge with its fellow of the opposite side, to the tendinous centre of the perineum. Passing anteriorly, it forms a plane of the labium majus, at the side of the vaginal orifice, and narrows as it advances; finally, it winds over the lateral surface of the corpus cavernosum of the clitoris, on the dorsum of which it is attached. The relations of the halves of the sphincter vaginæ muscle to the clitoris determine its being the analogue of the accelerator urinæ muscle. See Male Perineum, page 19.

16. Tendinous Centre of the Perineum.—This point is situated more posteriorly in the female; it is, as in the male, the common point of convergence of the muscles and fasciæ of the perineum. See Male Perineum, page 19.

17. Ischio-Cavernosus Muscle (Erector Clitoridis).—It is less developed than its analogue in the male, otherwise it is similar to it. See Male Perineum, page 19.

DISSECTION.—Section the ischio-cavernosus muscle (Plate 14) at its ischial attachment, and reflect it anteriorly.

18. Crus of the Clitoris.—Same attachments and course as the crus of the male penis, though much smaller. See Male Perineum, page 20.

DISSECTION.—Section the superficial transversus perinæi muscle (Plate 14) and reflect it over the ischial tuberosity. Expose the muscular branch of the superficial posterior perineal nerve beneath the muscle.

19. Muscle Branch of the Superficial Posterior Perineal Nerve.—This branch is given off as the trunk of the nerve passes to its superficial plane of distribution. It distributes: exteriorly to the triangular ligament, to the superficial transversus-perinæi, sphincter vaginæ, and ischio-cavernosus muscles; interiorly to the triangular ligament, to the deep transversus perinæi, and the constrictor urethræ muscles.

DISSECTION.—Section the halves of the sphincter vaginæ muscle (Plate 14) and reflect them anteriorly, preserving their anterior extremities in relation

with the corpora cavernosa of the clitoris. Take out the three anterior sutures of the labia; dissect off the mucous membrane from the vestibule; cut away the labia minora from the labia majora and from the clitoris; cut away the anterior halves of the labia majora.

20. Bulb of the Vagina, Fig. 1, Plate 15.—This presents in two lateral portions, one on either side of the vaginal orifice; they are nearly as broad as the halves, respectively, of the sphincter vaginæ muscle; they extend to about the middle of the antero-posterior diameter of the vaginal orifice; they lie between the sphincter vaginæ muscle and the triangular ligament. The portions are broad posteriorly, narrowing as they advance anteriorly, to where they unite in the submucous plane of the vestibule of the pudendum, forming what is known as the pars intermedia. This vestibular portion of the bulb surrounds the meatus of the urethra, reaching to the vaginal margin of the vestibule. In the position in which the clitoris is fixed, in the illustration, the vestibular portion would seem to continue along the inferior surface of the corpora cavernosa of the clitoris, and to cap the same at their extremities, thereby forming a glans clitoridis. (The portion of the bulb which passes from the pars intermedia to the glans clitoridis, is not, strictly speaking, continuous in structure with the bulb, but it presents a number of vessels, which continue from the pars intermedia to the glans.) The bulb of the vagina is the analogue of the male corpus spongiosum. In the female it is perforated by the urethra in its vestibular portion, and bears somewhat similar relations to the clitoris as does the corpus spongiosum to the penis.

DISSECTION.—Hook half of the bulb of the vagina and the corresponding crus of the clitoris (the latter having been detached from the pubic arch) across the median line, so as to expose one-half of the triangular ligament; note the vessels and nerves that perforate the ligament.

21. Triangular Ligament, Figs. 1 and 2, Plate 15.—This ligament is attached as in the male; see Male Perineum, page 20. It has a much larger area in the female, owing to the greater space between the rami of the pubic arch. Anteriorly, it is perforated by the urethra, as in the male; posteriorly, by the vagina, to which it is attached, interior to the plane of the bulb of the vagina. Posterior to the vaginal orifice, its base line, at the bis-ischiatic fascial junction, is in continuity

with the perineal and levator fasciæ ; it is attached to the tendinous centre of the perineum ; at the latter joint it is more posterior than in the male.

22. Artery of the Bulb, Fig. 2, Plate 15 ; Fig. 3, Plate 16.—This artery (vena comes) perforates the triangular ligament, to distribute as its name implies.

23. Deep Perineal Artery, Fig. 2, Plate 15, and Plate 17.—This artery (vena comes) pierces the triangular ligament, passes anteriorly, and bifurcates into the artery of the corpus cavernosum and the deep dorsalis clitoridis artery.

24. Artery of the Corpus Cavernosum, Fig. 2, Plate 15.—This artery (vena comes) enters the interior surface of the crus clitoridis ; it sends a branch to the vicinity of the meatus urinarius.

25. Deep Dorsalis Clitoridis Artery, Fig. 2, Plate 15 ; Figs. 2 and 3, Plate 16.—This branch passes, anteriorly, between the crus and the os pubis, to reach the base of the suspensory ligament of the clitoris (page 37).

26. Deep Perineal Nerve, Plate 17.—This nerve pierces the triangular ligament to become, exteriorly, the deep dorsalis clitoridis nerve, which accompanies the last-described artery.

DISSECTION.—Restore the crura, the bulb, and the sphincter vaginæ muscles to their normal position ; apply a hook into the free end of the clitoris, and extend it horizontally. Make a median-line incision through the skin of the dorsum of the clitoris and the mons veneris ; then reflect skin flaps.

27. Superficial Dorsalis Clitoridis Vessels and Nerves, Fig. 1, Plate 16.—These vessels and nerves are located on the dorsum and lateral surfaces of the clitoris, in its subcutaneous plane. A superficial dorsalis clitoridis artery (vena comes) is a branch of a superior external pudic artery. A superficial dorsalis clitoridis nerve is contributed by an ilio-hypogastric nerve.

DISSECTION.—Remove the superficial dorsal vessels and nerves of the clitoris ; trace the anterior tendinous extremities of the sphincter vaginæ muscles to the dorsum of the clitoris, then cut them away and expose the elastic suspensory ligament and sheath of the clitoris.

28. Sphincter Vaginæ Muscles, Plate 14.—The anterior tendinous ends of these muscles wind over the external surfaces of the corpora cavernosa of the clitoris, for attachment to the dorsum of that organ.

29. Elastic Suspensory Ligament and Elastic Sheath of the Clitoris, Figs. 1 and 2, Plate 16.—This triangular, elastic-tissue ligament is attached to the symphysis pubis, from which it suspends the clitoris; it is continued upon it as an elastic sheath.

DISSECTION.—Make a dorsal, median-line, incision through the elastic sheath of the clitoris. Reflect lateral flaps of the same, exposing the deep dorsalis clitoridis arteries, vein, and nerves. Trace these vessels and nerves to the base of the organ.

30. Deep Dorsalis Clitoridis Artery.—This artery emerges upon the dorsum of the clitoris, by a lateral opening in the base of the suspensory ligament; it is lodged between the elastic sheath and a corpus cavernosum of the organ.

31. Deep Dorsalis Clitoridis Vein.—This single vein is lodged in the furrow between the corpora cavernosa; it leaves the dorsum of the clitoris by a middle opening in the base of its suspensory ligament.

32. Deep Dorsalis Clitoridis Nerve.—A deep nerve reaches the dorsum of one side of the clitoris, by the same lateral opening in the base of the suspensory ligament as does an artery; it advances upon a corpus cavernosum, parallel with the artery, to distribute to its glans and prepuce.

DISSECTION.—Detach the suspensory ligament and cut the vessels and nerves as they enter its base; cut away the clitoris and bulb of the vagina. Replace the stumps of the deep vessels and nerves of the clitoris upon the exterior of the ossa pubis (Fig. 3, Plate 16). Make transverse sections of the clitoris and compare its structure with that of the penis, of which it is the analogue, viz.: the cylinders of the corpora cavernosa; and the vessels and tissue occupying the place of the corpus spongiosum and glans of the male penis (page 98; Fig. 2, Plate 56). Section the triangular ligament, as the perineal fascia was sectioned (Plate 13); reflect a flap posteriorly, which should preserve its junction with the perineal fascia and the tendinous centre of the perineum (Fig. 3, Plate 16); reflect the other two flaps to the pubic arch and the vaginal wall, respectively.

33. Artery of the Bulb, Fig. 3, Plate 16.—This artery (vena comes), is a branch of the deep perineal, as it lies (in the female) in a deeper plane. It perforates the constrictor urethræ, as well as the triangular ligament, to reach its distribution. This branch, in turn, gives off the *artery to the vulvo-vaginal gland*.

34. The Deep Perineal Artery and Nerve.—These perforate the constrictor urethræ muscle from an interior plane.

DISSECTION.—Clear the subjacent muscles of the urethro-vaginal region.

35. Deep Transversus Perinæi Muscle.—See Male Perineum, page 21.

36. Constrictor Urethræ Muscle.—See Male Perineum, page 22. Its external attachment is as in the male; the anterior portion bridges from one ramus to the other, as a fold of muscle anterior to the urethral canal; a second portion converges to the urethral canal at the meatus, and to the vaginal wall.

DISSECTION.—Remove the remaining sutures from the posterior portion of the labia majora. Find the orifice of the duct of the vulvo-vaginal gland upon the internal surface of the posterior half of the labium majus, and pass a fine probe into it; then track the probe to the gland, which in turn may be exposed by cutting away a portion of the deep transversus perinæi muscle.

37. Vulvo-vaginal Glands.—These glands (*k*. External genitalia, page 29) are the analogues of Cowper's glands of the male. A gland (the size of a small white bean) is located in the plane between the deep transversus perinæi muscle and the levator fascia (page 39), externally to the posterior extremity of the bulb of the vagina; its duct passes, internally, to its opening at the internal surface of the posterior half of a labium majus, exteriorly to the orifice of the vagina.

DISSECTION.—Section and reflect a flap of the gluteus maximus muscle, as in the dissection of the male perineum, see page 22.

38. Great Sacro-Sciatic Ligament.—See Male Perineum, page 22.

39. Fourth Sacral Nerve.—See Male Perineum, page 22.

DISSECTION.—Section the fibres of the deep transversus perinæi and constrictores urethræ muscles, and reflect them to the urethra and vagina, internally, and the pubic arch, externally. Preserve the attached portions of the

perineal fascia and the triangular ligament at the bis-ischiatic fascial junction, and also the tendinous centre of the perineum.

40. Deep Perineal Artery, Plate 17.—This artery (*vena comes*) is located interiorly to the ramus of the pubic arch and the plane of the deep transversus perinæi and constrictor urethræ muscles.

41. Deep Perineal Nerve.—This nerve accompanies the last-described artery.

42. Levator Fascia (*Levator ani* portion or *anal fascia*, and *levator vaginæ* portion or *posterior layer of the triangular ligament*).—This plane of fascia is analogous to that of the male (see Male Perineum, page 22); it differs from it in that the fascia is perforated, on the median line, by the vagina, to the circumference of which it is attached. In the female, the meeting of its two portions, at the bis-ischiatic fascial junction, is located more posteriorly than in the male.

DISSECTION.—Dissect off the levator fascia, and the tissues forming the bis-ischiatic fascial junction, from the muscle plane interiorly to it (Plate 18), tracing the fascia to the obturator fascia; section and cut away the deep perineal artery and nerve. Dissect away the tendinous centre of the perineum, so as to display the median-line raphe between the muscles interiorly to it.

43. Levator Ani et Vaginæ Muscles, Plate 18.—These muscles, right and left, are the analogues of the levator ani et prostatæ muscles of the male (page 24, Plate 9). The *ani* portions or the middle and posterior parts of the muscles are the same as in the male (page 24). The *vaginæ* portions or the anterior parts of the muscles are attached to the interior surfaces of the bodies of the ossa pubis; they are projected posteriorly, being separated by a subpubic interval, which gives transit to the urethra and the vagina; their fibres run parallel until they approach the interval between the vaginal and rectal outlets, when they curve, internally, to be attached to a fibrous, median line, raphe—the exterior of the raphe is attached to the tendinous centre of the perineum. The levator vaginæ portions of the muscles support the posterior wall of the vagina, at its outlet, as the levator prostatæ supports the prostate.

DISSECTION.—Section the levator ani et vaginæ muscle (Plate 18) and reflect its internal portion to the median line—anteriorly and posteriorly to the rectum—and to the coccyx ; at these points the muscle may be cut away. The part of the muscle, that converges to the rectum, may be disposed of as in the male (page 25).

44. Coccygeus Muscle.—See Male Perineum, page 25.

45. Recto-vesical Fascia, Plate 19.—This plane of fascia is nearly the same as in the male (page 25 ; Plate 10). The right and left portions of the fascia form, as in the male, a sling, at the outlet of the pelvis, to support the viscera there presenting. In the female it differs from the male, in that it is perforated by the vagina.

DISSECTION.—Section the recto-vesical fascia upon the rectal and vaginal walls, and reflect it, externally, to the pubic arch and the ischium. Note the close union of the rectal and vaginal outlets ; also, the same of the urethral and vaginal outlets. Display the areolar tissue and vessels between the fascia and the presenting viscera. Dissect the visceral outlets apart sufficiently to demonstrate the three canals : urethral, vaginal, and rectal.

46. Outlets of the Pelvic Viscera and the Perineal Body, Plates 13 to 19, inclusive.—The urethra, vagina, and rectum present in order, antero-posteriorly (Plate 19). The situation of the *so-called perineal body*, between the vaginal and rectal outlets, is occupied by the parts which converge to form the tendinous centre of the perineum (Plates 13 to 17, inclusive), and the raphe between the *vaginæ* portions of the levatores ani et vaginæ muscles (Plate 18). Interiorly to these parts the outlets of the vagina and rectum are intimately approximated.

DISSECTION.—Remove the oakum from the vagina and rectum. Put a hook into the urethra and drag it anteriorly ; dissect the antero-superior wall of the vagina from it, inferiorly ; once started the separation of the two canals is easily effected. As the separation progresses drag upon the urethra, anteriorly, and the vagina, posteriorly, until the base of the bladder is brought into view.

47. Urethra, Fig. 1, Plate 20.—The female urethra or urinary canal is about one inch and one-half long ; it forms a nipple-like projection from the bladder. The canal may be dilated with the finger, so as to enter the bladder.

48. Bladder.—The base of this organ is quite thin, as compared with the opposed vaginal wall ; the two will have been

found loosely adherent by the intervention of a delicate areolar tissue. Its lateral surfaces present some small arterial branches.

49. Ureters.—These ducts will be seen to enter the bladder, approaching the same obliquely from without inwards and forwards; their points of entrance are about one inch and one-half apart. Before entering the bladder they are located between the superior wall of the vagina and the base of the bladder.

50. Superior Wall of the Vagina.—The wall of this canal is thick and smooth, and its muscle structure evident; at its lateral borders are the vaginal arteries.

DISSECTION.—Restore the bladder, urethra, and superior wall of the vagina to their normal positions. Insert a hook into the posterior part of the circumference of the vaginal outlet, and pull the same anteriorly; dissect off the opposite rectal wall. For a distance of about one inch and one-half, interiorly to the tendinous centre of the perineum, the vagina and rectum are intimately adherent, allowing of no sliding of their applied walls upon each other. Beyond their exterior adherent portions the two canals are loosely held together by areolar tissue, thus admitting of the sliding of one canal wall upon the other. As the dissection progresses the vagina should be pulled anteriorly, the rectum posteriorly and out of the pelvis. When about five inches of the superior wall of the rectum have been exposed, a septum of membrane, peritoneum, will be seen reflected from the rectum to the vagina. Note, on either side of the interior portion of the exposed rectum, the middle hemorrhoidal arteries; also, the vaginal arteries at either side of the vagina.

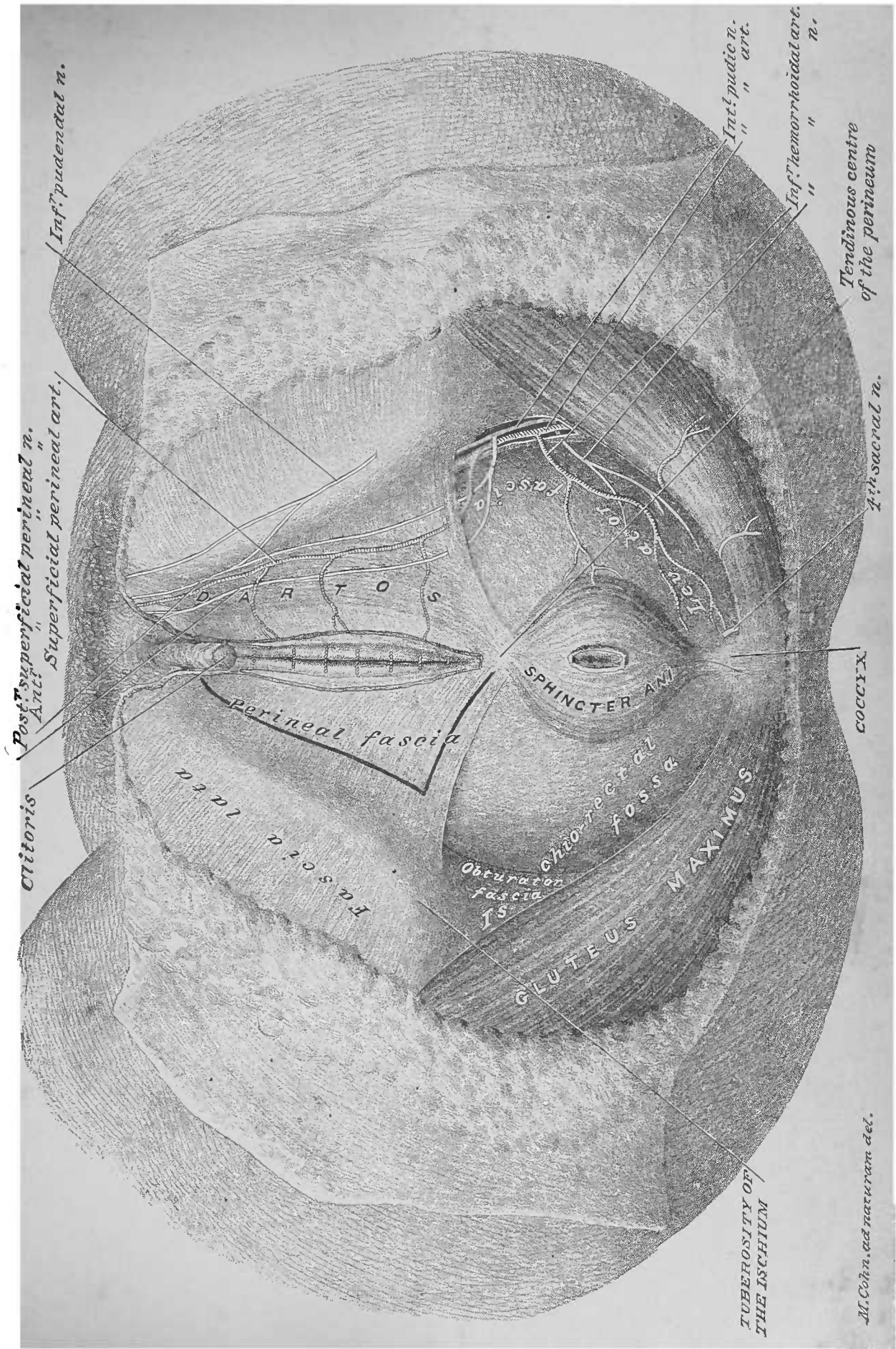
51. Inferior Wall of the Vagina, Fig. 2, Plate 20.—This wall of the vagina presents little difference from the superior, except that a larger number of veins ramify in its substance.

52. Rectum (Superior wall).—This wall of the rectum presents the peculiar muscular structure of this portion of the large intestine, namely, that of longitudinal fibres; it is quite thick, though not as thick as the opposite vaginal wall.

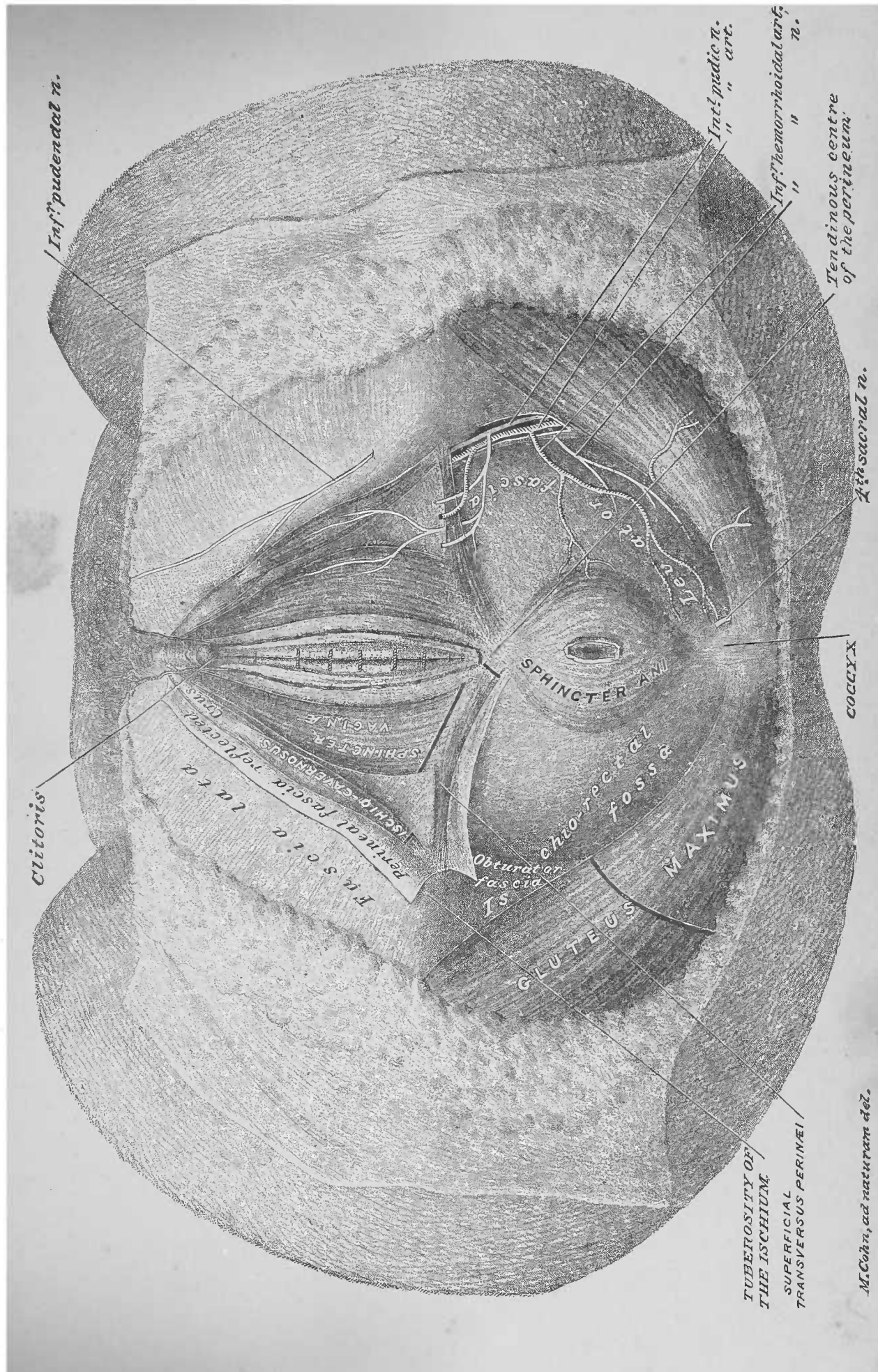
53. Recto-Vaginal Cul-de-Sac of Peritoneum.—The membranous cul-de-sac, brought into view, interiorly, at the upper part of the exposed portions of the rectum and vagina, is formed by the peritoneum; it is the bottom of the recto-vaginal or Douglas' cul-de-sac. By passing the finger into the vagina,

the reflection of the peritoneum from the vaginal to the rectal wall, one inch or more below the attachment of the vagina to the posterior surface of the uterus, is demonstrable; if the peritoneal cul-de-sac be opened, and a finger of the other hand introduced at the opening, the two fingers will be separated by peritoneum, inferiorly, and vaginal wall, superiorly.

DISSECTION.—The organs should be crowded back into the pelvic cavity; the skin flaps of the perineum approximated and sewed together on the median line.



M. Cohn, ad naturam del.



Inf. pudendal n.

Int. medic n.

Inf. hemorrhoidal art. n.

Tendinous centre of the perineum

4th sacral n.

Clitoris

SPHINCTER ANI

ischio-rectal fossa

Obturator fascia

GLUTEUS MAXIMUS

COCYX

Int. s. c. t. a.
perineal fascia reflected
ischio-externalis
SPHINCTER
VAGINAE
Ext. s. c. t. a.

TUBEROSITY OF THE ISCHIUM
SUPERFICIAL TRANSVERSUS PERINEI

M. Cohn, ad naturam del.

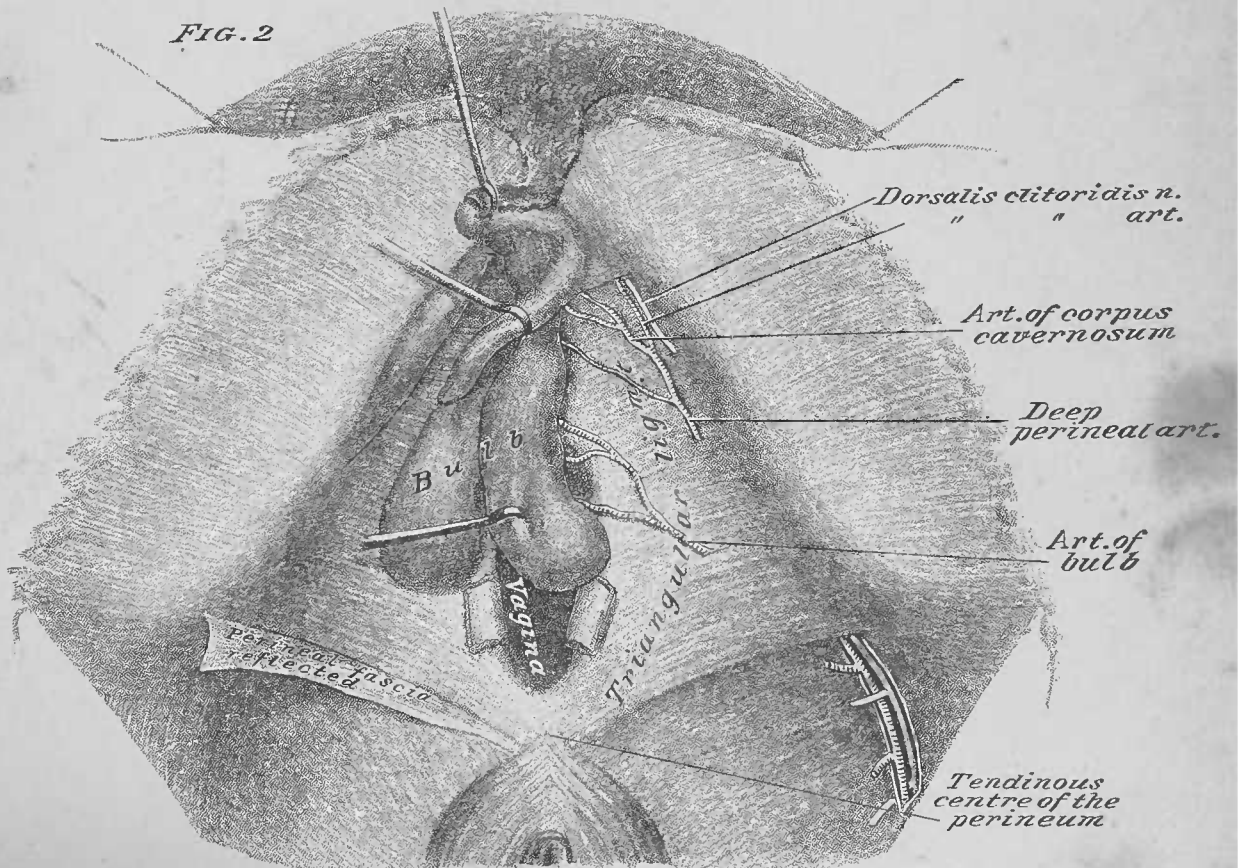
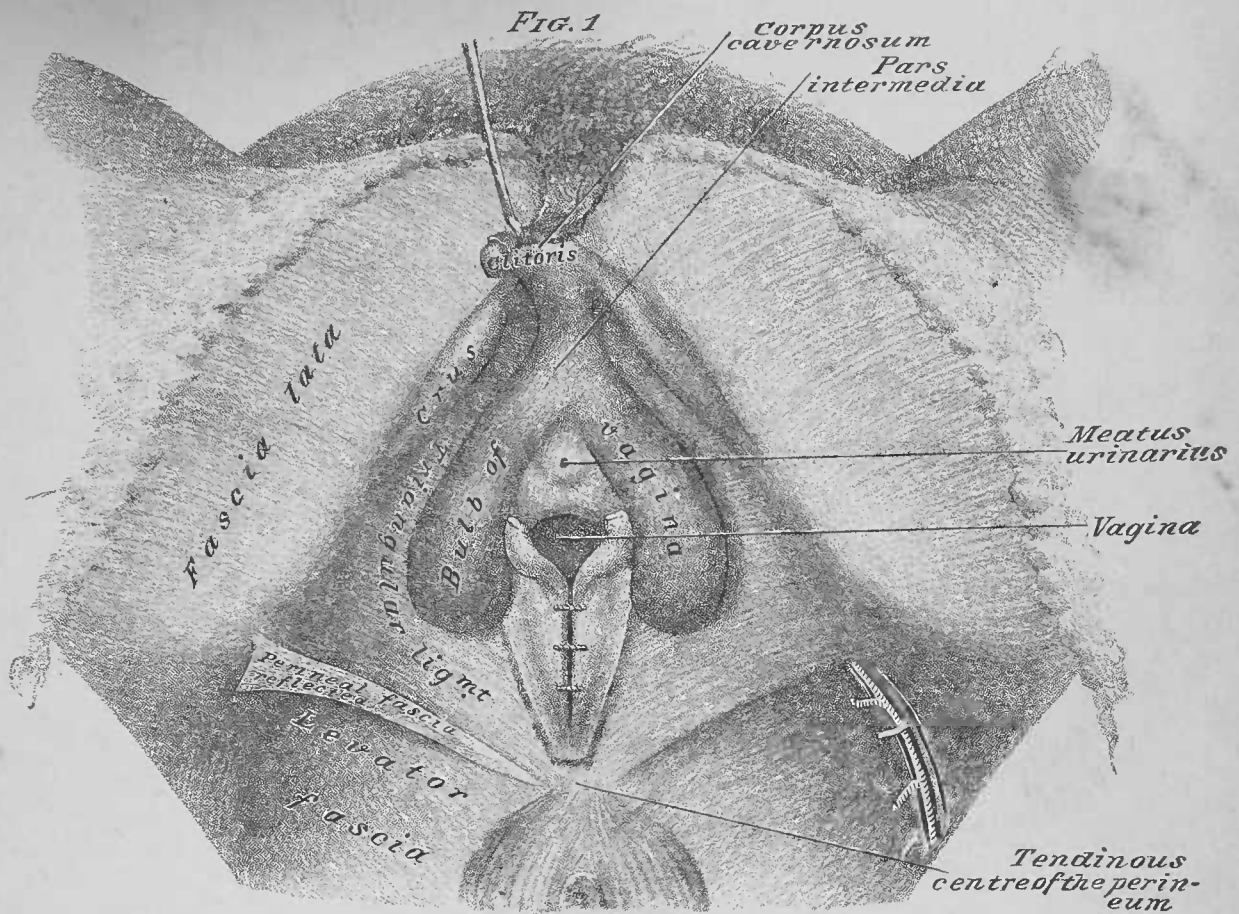


FIG. 1

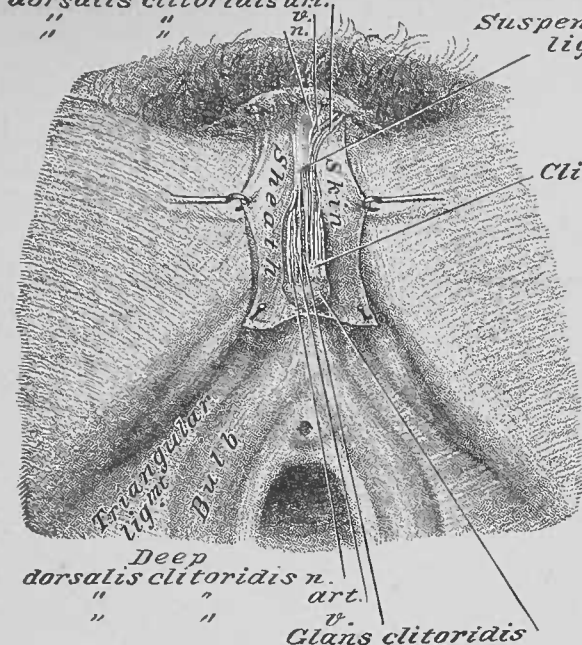


FIG. 2

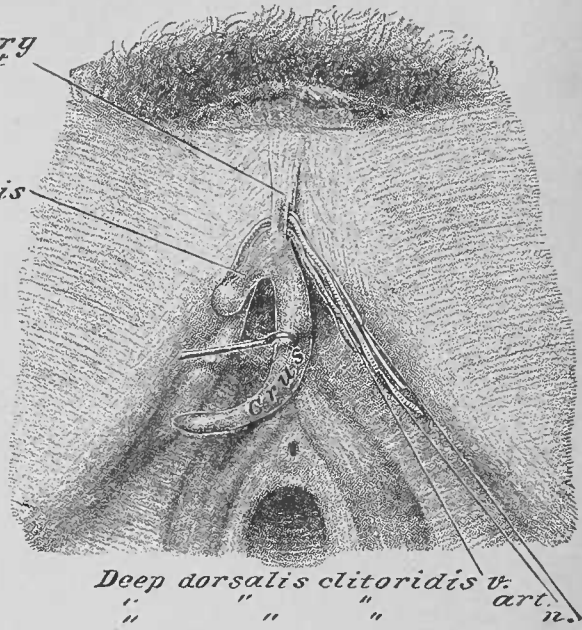
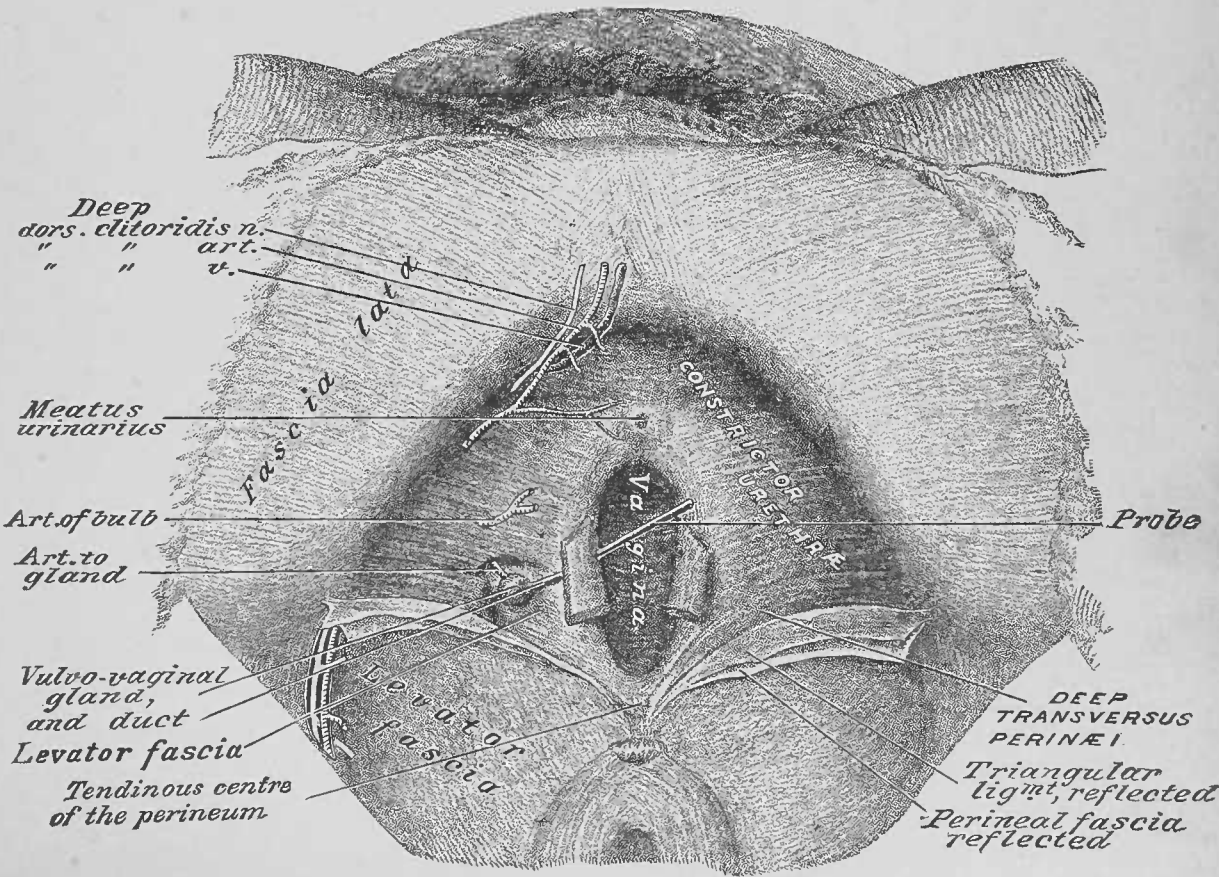
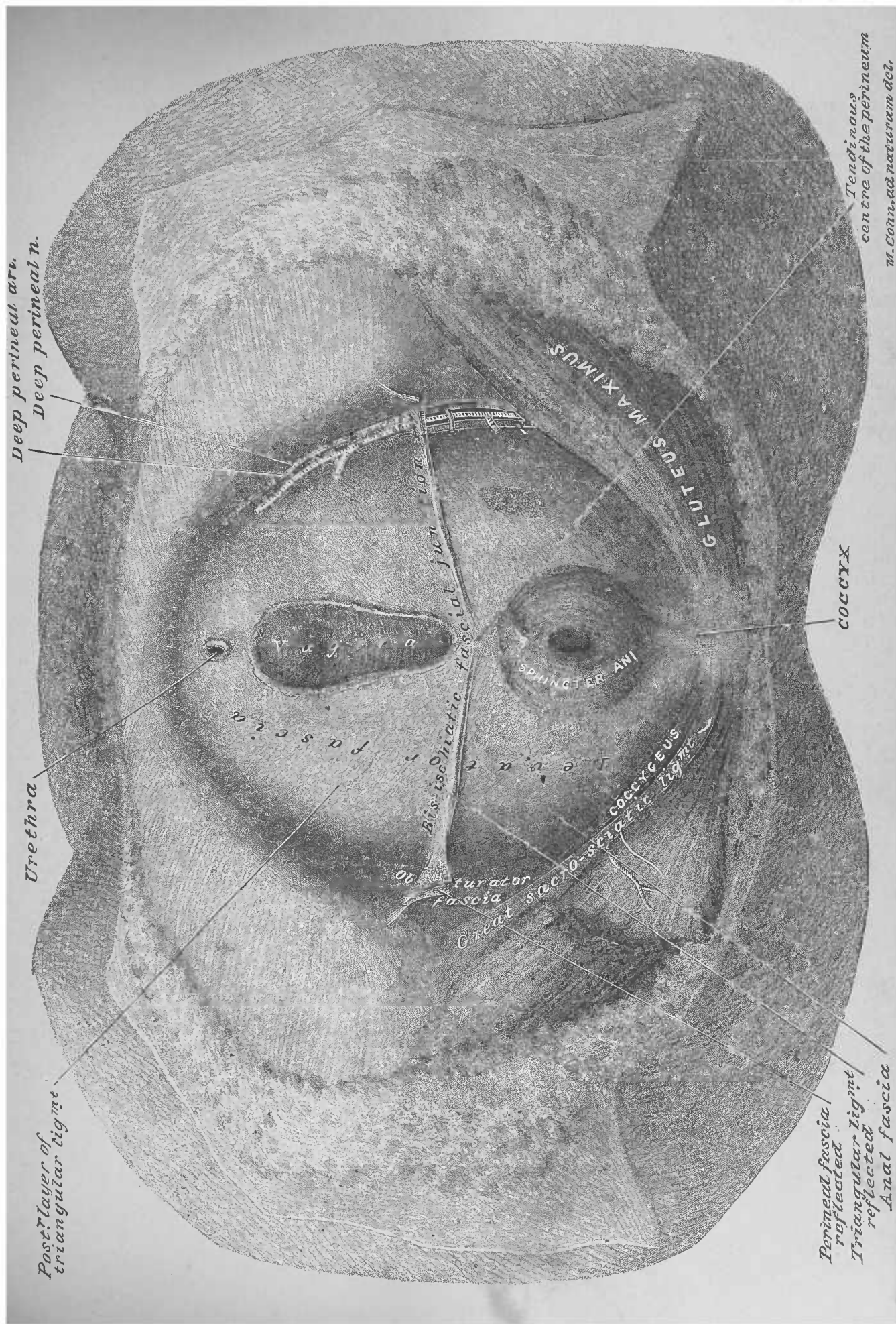


FIG. 3



M. Cohn, ad naturam del.



Deep perineal art.
Deep perineal n.

Urethra

Post. layer of
triangular ligmt

fascia

Bis-ischiatic fascial Jun

Obturator
Fascia

Great sacro-sciatic ligmt

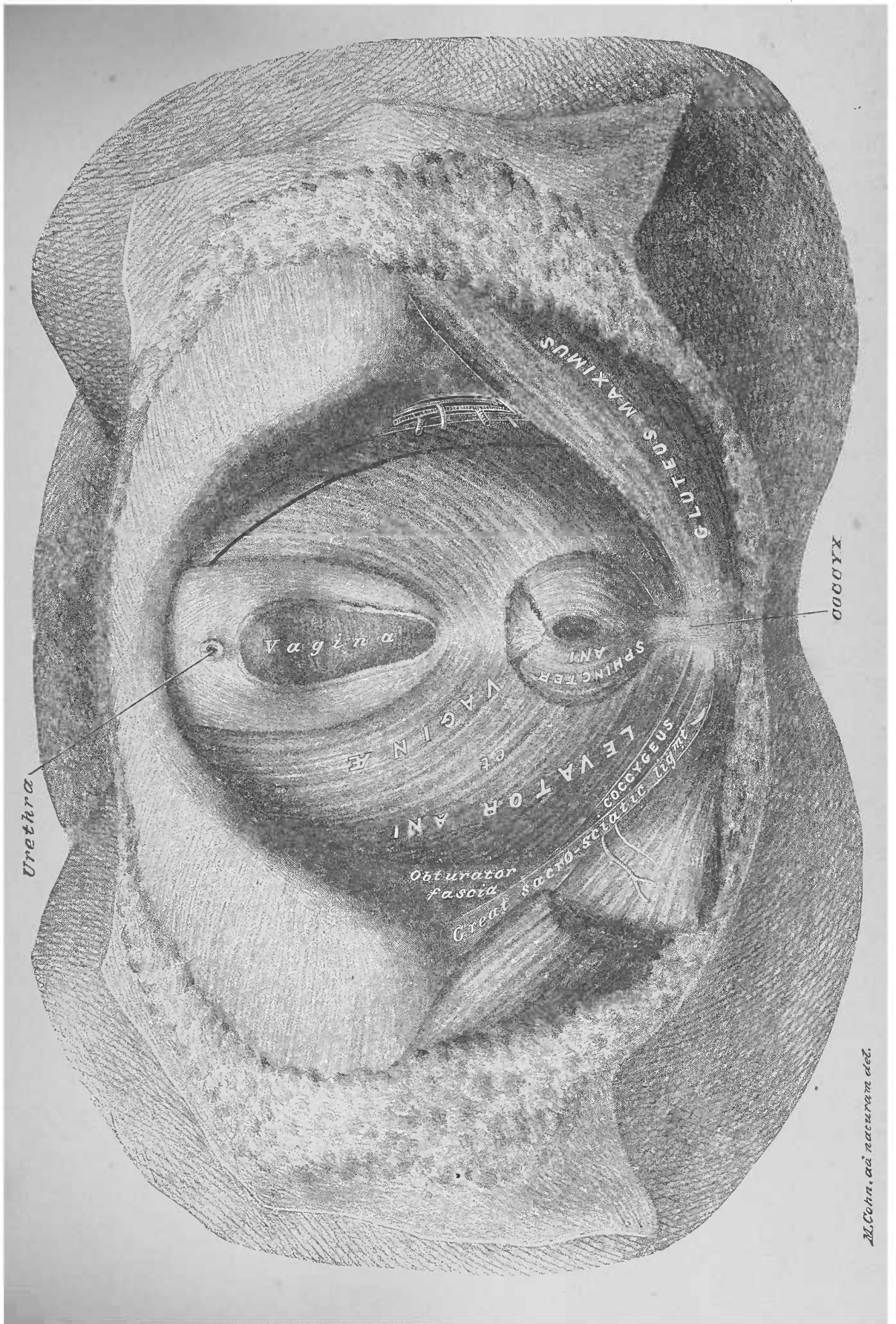
SPHINCTER ANI

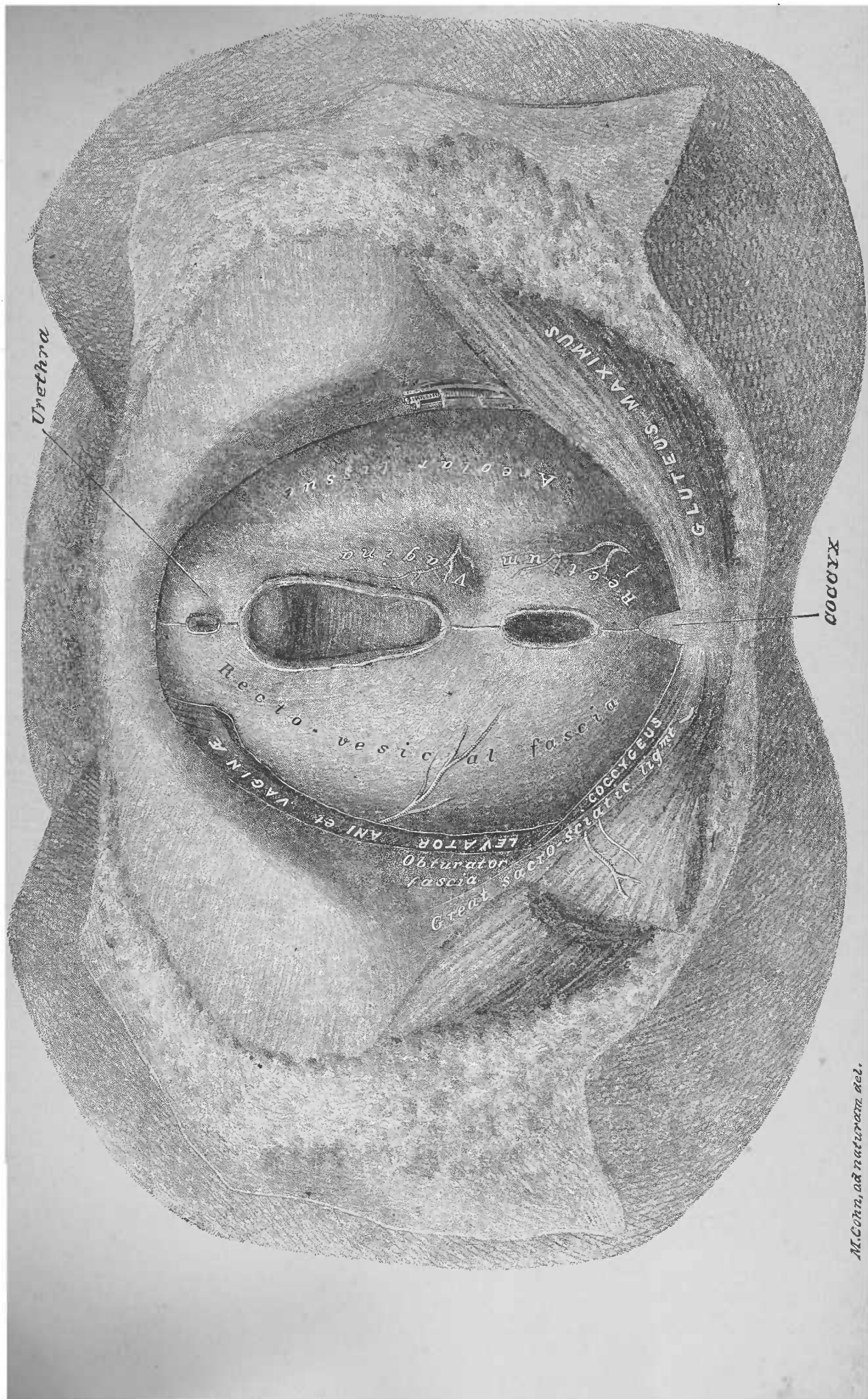
GLUTEUS MAXIMUS

COCCYX

Perineal fascia
reflected
Triangular ligmt
reflected
Anal fascia

Tendinous
centre of the perineum
M. Conn. ad naturam del.





M. Cohn, ad naturam del.

FIG. 2

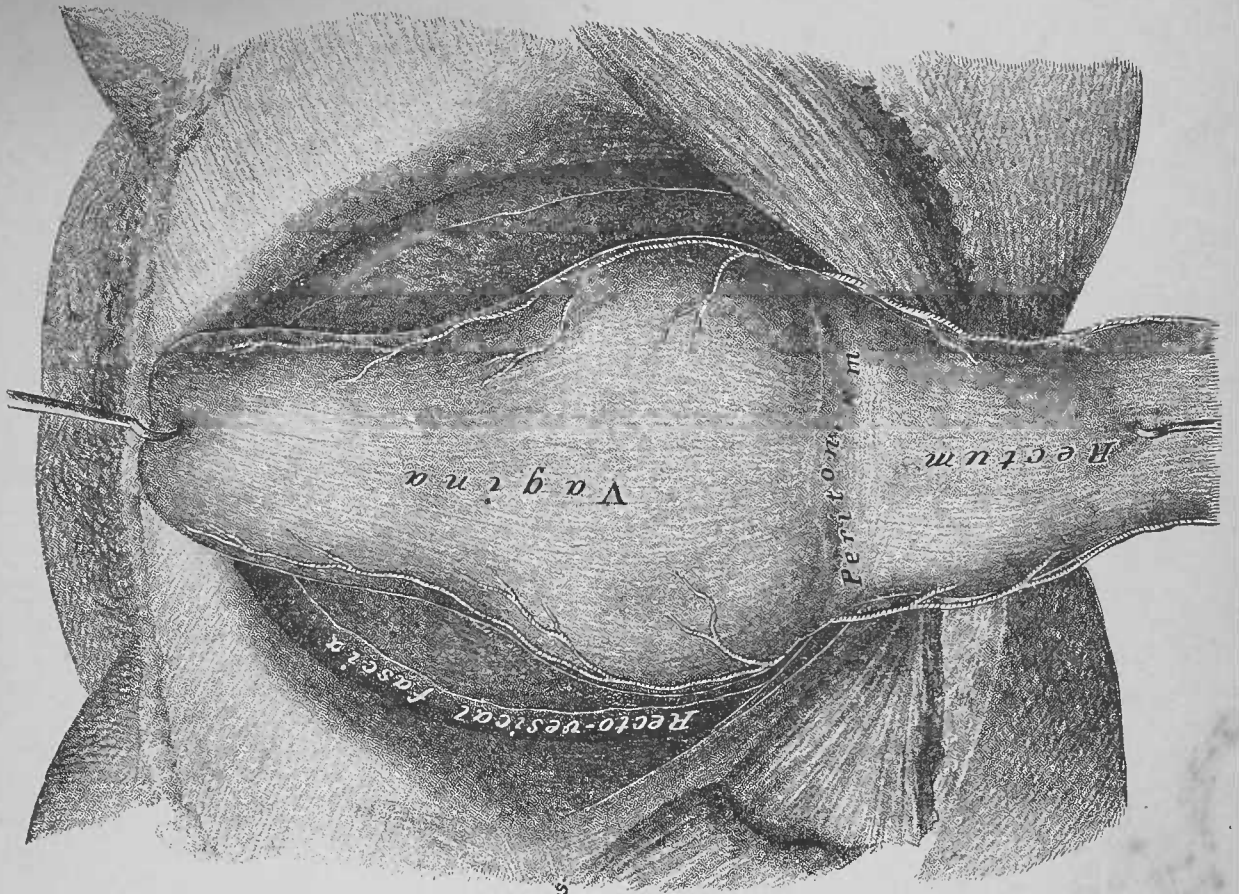
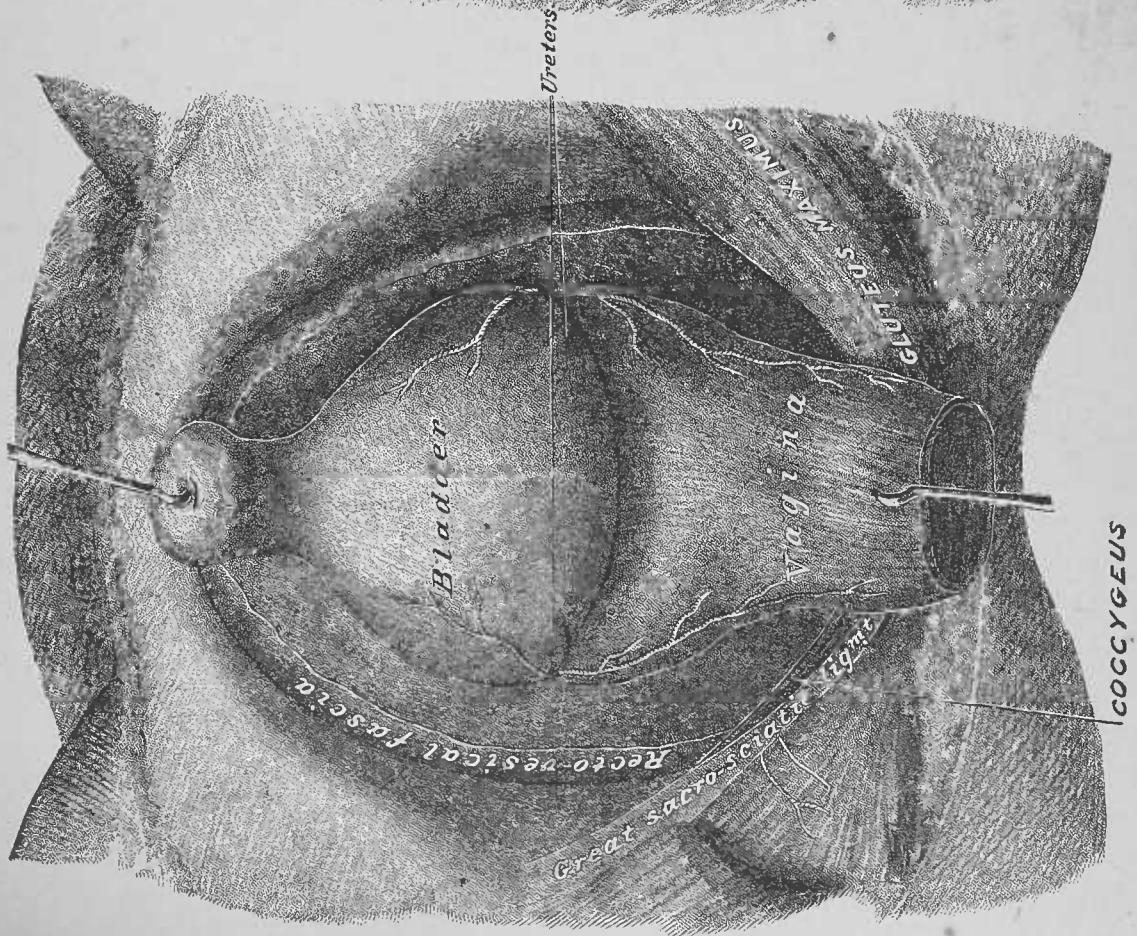


FIG. 1



THIRD DISSECTION.

ANTERO-LATERAL AREAS OF THE ABDOMINAL PARIETES.

DISSECTION.—The body should be placed lying upon the back, with a block under the shoulders and one under the pelvis.

Terms of Relation.—The following terms will be used to designate the *Areas* of the abdominal wall: *Anterior*, *Lateral* and *Antero-Lateral*. The words *Interior* and *Exterior* will indicate proximity to the abdominal cavity, and to the skin, respectively.

Bones and Cartilages, Plates 21 and 42.—The anterior halves of, and the cartilages of, the six inferior ribs (right and left), the ensiform cartilage of the sternum, the crest of the ilium and the superior surface of the ossa pubis of the right and the left os innominatum, form the osseous framework of this dissection. All these bones and cartilages afford attachments to muscles.

DISSECTION.—Extend the penis horizontally by fixing a hook into the prepuce; then fix the other two hooks, of the chain-hooks, into the lower limbs. Make the skin incisions, 1 and 2 of Fig. 3; skin incision 1 will be referred to as the *Bis-Iliac Incision*; skin incision 2 as the *Median-Line Incision*. Reflect a skin flap, inferiorly, upon the thigh, to which it may be pinned. This form of flap, from this region, will be called an *Inguinal Flap*. Hook the skin sheath of the penis, externally.

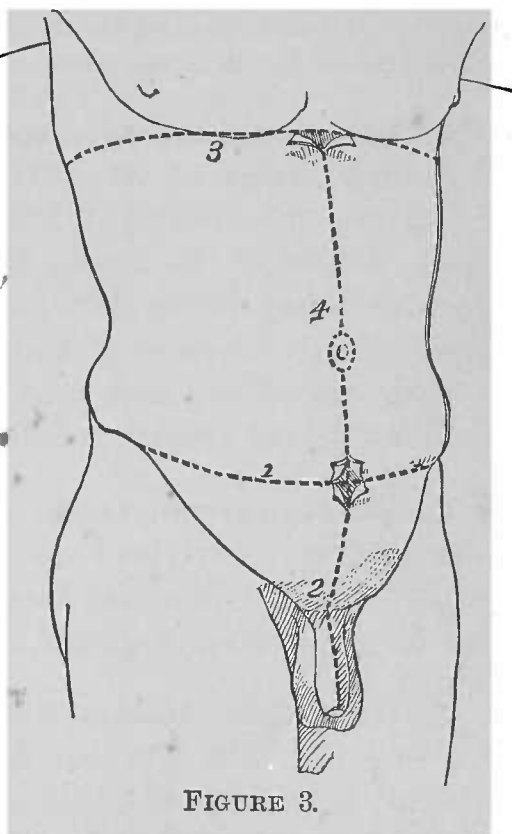


FIGURE 3.

This form of flap, from this region, will be called an *Inguinal Flap*. Hook the skin sheath of the penis, externally.

1. Subcutaneous Tissue, Plate 22.—The subcutaneous tissue is more or less loaded with fat. This plane of tissue passes continuously to contribute to the dartos sheath of the penis and the dartos tunic of the scrotum. The inguinal area of the subcutaneous tissue of the abdominal wall may be easily divided into two layers, the superficial and the deep, between which vessels ramify. Note, the perforation of the superficial layer, external to the root of the scrotum and penis, by the superficial penile and scrotal branches of the superficial external pudic vessels; also, the perforation of the same, superior to the root of the penis, by the superficial penile branches of the ilio-hypogastric nerve.

DISSECTION.—Make the bis-iliac incision on one side, and the median-line incision down to the root of the penis, through the superficial layer of the subcutaneous tissue. Reflect an inguinal flap of the superficial layer, being careful to preserve the perforating penile and scrotal vessels and nerves, by slitting through the layer, so as to retain their continuity from their trunks to their distributions; carry the flap from the face of the anterior superior region of the thigh, so as to expose the saphenous opening in the fascia lata. The vessels between the superficial and deep layers will be found a guide to the separation of the two planes of tissue. Note, the continuity of the superficial layer with the subcutaneous tissue of the thigh, the dartos tunic of the scrotum and the dartos sheath of the penis. Pin the flap to the thigh with the skin.

2. Subcutaneous Arteries of the Inguinal Region.—Between the layers of the subcutaneous tissue of the inguinal region are the recurrent branches from the femoral artery, which perforate the fascia lata, below the line of the groin: the superficial circumflex iliac, extending superiorly and externally over the crest of the ilium; the superficial epigastric, running superiorly and internally; the superior external pudic, curving internally to the root of the penis or clitoris.

3. Subcutaneous Veins of the Inguinal Region.—The venæ comites of the above arteries may be traced to where they empty into the internal saphenous vein, before its entrance into the saphenous opening in the fascia lata.

4. Superficial Dorsal Vessels and Nerves of the Penis.—Between the skin and the dartos sheath of the penis the superficial dorsalis penis artery, branch of the superior external pudic, runs longitudinally upon the dorsum of the penis, from the base to the glans. The vena comes, sometimes quite large,

anastomoses with the deep dorsalis penis vein, and continues to the superior external pudic vein. The ilio-hypogastric nerve distributes dorsal branches to the organ.

DISSECTION.—Section the superficial dorsalis penis vessels and nerves at the root of the penis, and dissect them off of the dartos sheath.

5. Dartos Sheath of the Penis.—This sheath is in continuity with the superficial and deep layers of the inguinal subcutaneous tissue; it is also continuous with the dartos tunic of the scrotum. It differs from the inguinal subcutaneous tissue planes, in being free of fat and in having involuntary muscular fibres in its structure. It is separated by loose areolar tissue from the subjacent elastic tissue sheath of the organ, thus allowing of its sliding upon the latter.

DISSECTION.—Expose the suspensory ligament of the penis; make a median-line incision on the dorsum of the penis, through the dartos sheath, and reflect a flap externally; follow the suspensory ligament to the penis.

6. Suspensory Ligament and Sheath of the Penis.—This so-called ligament, composed of elastic tissue, is attached to the median line of the pubes. It passes, inferiorly, upon the body of the penis, to which it contributes an elastic sheath, which is thickest around the root of the organ.

DISSECTION.—Make a median-line incision on the dorsum of the penis, through the elastic sheath, from the glans to the base of the organ; dissect off the sheath, so as to expose the deep dorsalis penis vessels and nerves, and show their relations to the openings at the attached base of the ligament.

7. Deep Dorsalis Penis Artery.—The artery, of a side, has been described in a part of its course (see Male Perineum, page 20). In the dissection of the male perineum it was left, passing, anteriorly, between the exterior surface of the body of the os pubis and the crus of a corpus cavernosum (Figs. 1 and 2, Plate 8). It enters upon the dorsum of the penis, through the attached base of the suspensory ligament, by an opening at the side of the median line; thence it runs, longitudinally forward, upon the dorsum of the organ, distributing branches to the corpus cavernosum and the glans.

8. Deep Dorsalis Penis Nerve (see Male Perineum, page 2).—This nerve accompanies the last-described artery to the suspensory ligament; it enters upon the dorsum of the penis by

the same opening in the suspensory ligament; it continues to the glans, to the mucous membrane of which it is distributed.

9. Deep Dorsalis Penis Vein.—This vein (sometimes two) is lodged on the median line of the dorsum of the penis, passing from the glans to the suspensory ligament, where it enters a middle opening. It then continues, posteriorly, upon the exterior of the os pubis; it enters the pelvic cavity by perforating the triangular ligament; it then bifurcates, the branches emptying respectively into the venous plexus, right and left, at the sides of the prostate and base of the bladder.

DISSECTION.—Make the bis-iliac and median-line incisions through the deep layer of the subcutaneous tissue; reflect an inguinal flap, inferiorly, upon the thigh, carrying the superficial inguinal vessels with it; pin the flap to the thigh.

10. Deep Layer of the Subcutaneous Tissue of the Inguinal Region.—This plane of tissue continues below the line of Poupart's ligament, to be attached to the fascia lata, at an oblique line from the anterior superior spinous process of the ilium to the scrotum; the attachment runs between Poupart's ligament and the saphenous opening. In the male, it is continuous with the dartos tunic of the scrotum and penis; in the female, with that of the labium majus. This plane of tissue is continued from the perineal fascia of the perineum; advancing, anteriorly, the latter becomes the dartos tunic of the scrotum (posterior and anterior surfaces) or of the labia majora (female); from the dartos tunic of scrotum or labium it is directly continuous with the layers of the subcutaneous tissue of the inguinal region.

DISSECTION.—Make skin incisions 3 and 4 of Fig. 3 (page 43), and reflect a flap of the skin, externally, well off the lateral area of the abdomen. Incision 4, with 2, completes the median-line incision.

11. Subcutaneous Tissue, Plate 24.—The superior antero-lateral area of the subcutaneous tissue presents but a single layer. It is in this plane of the parietes that the subcutaneous nerves of the abdomen ramify.

DISSECTION.—Make incision 3 and median-line incision 4, of Fig. 3, in the subcutaneous tissue plane, and reflect lateral flaps corresponding to those of the skin; preserve, as long as possible, the cutaneous nerves and vessels at their points of emergence.

12. Cutaneous Nerves of the Abdominal Parietes, Plate 23.—These nerves, from the inferior intercostal nerves, perforate the superficial fascia. They become subcutaneous at the following points: laterally, at the rib attachments of the obliquus externus muscle; anteriorly, toward the median line. The lateral nerves bifurcate into posterior and anterior branches. The anterior present two rows of emergence: the external divide as do the lateral; the internal do not divide.

13. Superficial Fascia.—This plane is a very thin layer of fibrous tissue upon the exterior of the obliquus externus muscle; it is continued from the thoracic parietes, superiorly; it is attached, inferiorly, to the crest of the ilium, Poupart's ligament and the body of the os pubis. In the inguinal region it is strengthened by loops of fibrous tissue, with their convexities directed toward the pubes, the arciform or intercolumnar fibres.

DISSECTION.—Dissect off the superficial fascia from the obliquus externus muscle, being careful to preserve the portion of it that springs from the pillars of the opening in the aponeurosis of the muscle, to invest the spermatic cord. Trim away the inguinal flaps of subcutaneous tissue along the line of the groin.

14. Fibrous Tissue Markings of the Abdominal Parietes, Plate 24.—These markings are: the linea alba, at the median line, from the symphysis pubis to the ensiform cartilage of the sternum—upon this line is the umbilicus; the lineæ semilunares, curving, superiorly, from opposite the spines of the ossa pubis to the anterior extremities of the cartilages of the tenth ribs; the lineæ transversæ cross between the linea alba and the lineæ semilunares, at, and superior to, the umbilicus.

15. Obliquus Externus Muscle, Fig. 1, Plate 21 and Plate 24.—This forms the exterior muscle plane of the antero-lateral area of the abdominal parietes. Superiorly, it is attached to the exterior surfaces of the lateral area of the seven or six inferior ribs; the superior four or five attachments interdigitate with digitations of the serratus magnus muscle; the inferior three attachments interdigitate with digitations of the latissimus dorsi muscle. From the two inferior ribs the muscle fibres pass, inferiorly, to the crest of the ilium; from its superior four or five rib attachments, the fibres pass inferiorly and

internally. The latter portion of the muscle forms an aponeurosis at the anterior area of the abdomen, which continues as a single plane to the linea alba, from the sternum to the symphysis pubis. Superiorly, the pectoralis major muscle—its inferior portion—is attached to the exterior of the aponeurosis. The inferior edge of the aponeurosis bridges from the anterior superior spinous process of the ilium to the spine of the os pubis, forming Poupart's ligament; it is also attached to the linea ilio-pectinea—on the superior surface of the horizontal ramus of the os pubis—external to the spine of the os pubis, forming Gimbernat's ligament. External and superior to the pubic attachment to the spine of the pubis, a deficiency presents in the aponeurosis—a slit-like opening—the *pubic* (external) abdominal ring. This opening has a superior and an internal border, and an inferior and external border, known as the pillars of the ring. A little superior and internal to the pubic ring the aponeurosis is perforated by the ilio-hypogastric nerve (Plate 23).

16. External Spermatic (Intercolumnar) Fascia.—From the pillars or borders of the pubic (external) abdominal ring, the superficial fascia upon the exterior of the obliquus externus muscle projects this fascial investiture upon the spermatic cord (male) or round ligament of the uterus (female).

DISSECTION.—Incise and open the external spermatic fascia upon the cord, exposing the subjacent investiture of the same.

17. Spermatic Cord (male) or Round Ligament of the Uterus (female).—The cord or ligament with its investments passes through the pubic (external) abdominal ring, also the ilio-inguinal nerve.

DISSECTION.—Incise the aponeurosis of the obliquus externus (Plate 24) by the median-line and bis-iliac incisions (2 and 3, Figure 3; page 43); reflect an inguinal flap of the same (Plate 25).

18. Pubic (External) Abdominal Ring, Plate 25.—The interior surface of this so-called ring shows its true character, viz.: a splitting or separation of the fibres of the aponeurosis of the obliquus externus. The pillars of the ring are well de-

DISSECTION.—Incise the obliquus externus muscle (Plate 24) as follows : at its lateral area, from the eleventh rib to the ilium, and along the crest of the ilium ; at its rib attachments, dissect out its digitations from the interdigitations of the serratus magnus muscle. Reflect a flap of the superior antero-lateral area of the muscle, internally, to a line beyond the linea semilunaris ; fold the portion of the muscle into a longitudinal roll at the side of the median line (Plate 25).

19. Intermuscular Septum.—A thin layer of fibrous tissue separates the obliquus externus from the obliquus internus muscle.

20. Ilio-hypogastric Nerve.—This nerve emerges through the obliquus internus muscle, internal to the anterior superior spinous process of the ilium ; it continues exterior to the muscle, internally, to where it perforates the aponeurosis of the obliquus externus muscle, as before shown.

21. Ilio-inguinal Nerve.—This emerges through the obliquus internus muscle ; it runs upon the muscle, parallel with and nearer to Poupart's ligament than the last named nerve. It emerges at the pubic (external) abdominal ring, with the spermatic cord (male) or round ligament of the uterus (female).

DISSECTION.—Clear the intermuscular fibrous tissue from the surface of the obliquus internus muscle.

22. Obliquus Internus Muscle, Fig. 1, Plate 21, and Plate 25.—This forms the second antero-lateral muscle plane of the abdominal parietes. It is attached : posteriorly, to the lumbar aponeurosis ; inferiorly and externally, to the anterior two-thirds of the mid-space of the crest of the ilium and to the external half of Poupart's ligament ; superiorly, to the cartilage of the twelfth rib, the eleventh rib, and the cartilages of the eleventh, tenth, and ninth ribs ; internally, to the linea alba by the aponeurosis of the muscle—this splits at the linea semilunaris, to sheath the rectus, and then unites at the linea alba. Its middle Poupart ligament fibres are attached to the exterior of the tendon of the transversalis, externally to the inferior of the linea semilunaris. Its inferior Poupart ligament fibres (male) loop, inferiorly, to invest the spermatic cord upon its antero-external surfaces, returning, superiorly, to be attached to the anterior surface of the body of the os pubis. These looped

fibres form what is called the *cremaster muscle*. In the female the looping of these inferior fibres of the obliquus internus muscle does not occur; the muscle fibres simply separate to give transit to the round ligament of the uterus, and pass, internally, to be attached to the conjoined tendon and the os pubis.

DISSECTION.—Dissect the ilio-hypogastric and ilio-inguinal nerves superiorly and reflect them externally. Make an incision through the fibres of the obliquus internus muscle from the anterior superior spinous process of the ilium to the linea semilunaris, a second through its fibres, attached to Poupart's ligament (Plate 25). Reflect the included inguinal portion of the muscle to the linea semilunaris. In the male trace the middle Poupart ligament fibres to the exterior of the conjoined tendon portion of the transversalis abdominis muscle; and the inferior fibres as they form the cremasteric loops upon the spermatic cord. In the female note the absence of cremasteric loops and the unbroken plane of the muscle. Incise the muscle as follows: from the eleventh rib to the ilium, and along its crest attachment; also below its attachments to the eleventh rib and its cartilage. Reflect a flap, internally, of the superior antero-lateral portion of the muscle to the linea semilunaris; throw the flap over the reflected obliquus externus muscle. The guides to the plane of intermuscular fibrous tissue, separating the obliquus internus from the transversalis abdominis muscle, are the vessels and nerves ramifying between these muscles. Remove the fibres of the obliquus internus to the conjoined tendon, noting, that they are inserted into the exterior surface of the transversalis portion of the tendon. Dissect off the cremasteric loops from the spermatic cord.

23. Intermuscular Septum.—A plane of fibrous tissue forms a septum between the obliquus internus and the transversalis abdominis muscles, in which vessels and nerves ramify.

DISSECTION.—Differentiate the nerves and arteries in the fibrous tissue plane, and dissect off the latter from the antero-lateral area of the transversalis abdominis muscle.

24. Deep Vessels and Nerves of the Parietes, Plates 26 and 27.—These vessels and nerves are the terminal branches of the four inferior intercostal arteries and nerves, which continue to the median line; they may be traced, internally, to where they penetrate the sheath of the rectus abdominis muscle. They supply the antero-lateral muscles and skin of the abdominal parietes. The ilio-hypogastric and ilio-inguinal nerves, branches of the first lumbar nerve, also present.

25. Deep Circumflex Iliac Artery, Plate 27.—This artery (*vena comes*) is a branch of the external iliac. It per-

forates the transversalis abdominis, near the anterior superior spinous process of the ilium, to wind, externally and superiorly, over the crest of the ilium, exteriorly to the muscle.

26. Transversalis Abdominis Muscle, Plates 27 and 42.—This forms the third antero-lateral muscle plane of the abdominal parietes. Its attachments are: to the interior surfaces of the cartilages of the six inferior ribs—interdigitating with digitations of the diaphragm; to the lumbar aponeurosis, by which it is attached to the transverse processes of the lumbar vertebræ; to the anterior three-fourths of the interior portion of the crest of the ilium; to the external third of Poupart's ligament; to the linea alba, by the aponeurosis of the muscle, which commences at the linea semilunaris; and to the os pubis by the conjoined tendon.

27. Conjoined Tendon.—This is formed by the converging of the inferior Poupart ligament fibres of the transversalis abdominis muscle and the middle Poupart ligament fibres of the obliquus internus muscle, to a common point of attachment on the linea ilio-pectinea, externally and interiorly to the spine, and to the superior surface of the body, of the os pubis. The fibres of the obliquus internus are attached to the exterior of the aponeurosis of the transversalis. The tendon is located externally to the inferior end of the linea semilunaris, in a plane interiorly to the spermatic cord (male) or round ligament of the uterus (female), as it passes through the pubic (external) abdominal ring; at its linea-ilio-pectinea attachment it lies interiorly to Poupart's and Gimbernat's ligaments.

DISSECTION.—Replace the flaps of the obliquus internus and externus muscles; make an incision parallel with, and midway between, the linea alba and the linea semilunaris, through the aponeurosis of the obliquus externus and the exterior layer of the splitting of the aponeurosis of the obliquus internus. Reflect lateral flaps to each linea, respectively, exposing the rectus abdominis and the pyramidalis abdominis muscles.

28. Pyramidalis Abdominis Muscle, Plates 28 and 42.—This small, triangular, muscle lies exteriorly to the inferior portion of the rectus abdominis, at the side of the median line. At its base it is attached to the superior border of the body of the os pubis; its fibres pass, superiorly, to its apex, at the

linea alba, where it is attached about a third or a half of the distance from the symphysis pubis to the umbilicus.

29. Rectus Abdominis Muscle.—This muscle, as its name implies, is straight fibred; it is attached, inferiorly, to the superior surface of the body of the os pubis from the symphysis to the spine; superiorly, to the exterior surfaces of the ensiform cartilage of the sternum, and the cartilages of the seventh, sixth and fifth ribs. The muscle fibres are intersected at and above the umbilicus by three fibrous portions, which determine the lineæ transversæ; the latter are attached to the exterior layer of the sheath of the muscle.

30. Sheath of the Rectus Abdominis Muscle, Plate 28.—This invests the abdominal portion of the muscle, between its pubic and thoracic attachments. It is formed by the aponeuroses of the antero-lateral muscles of the abdominal parietes. The aponeurosis of the obliquus externus continues to the linea alba from the ensiform cartilage to the symphysis pubis. The aponeurosis of the obliquus internus splits at the linea semilunaris into two layers for the superior three-quarters of the muscle portion; one layer passes exteriorly to the muscle and interiorly to the aponeurosis of the obliquus externus; the other layer passes interiorly to the muscle. Internally to the muscle the two layers reunite at the linea alba. For the inferior quarter of the abdominal portion of the rectus abdominis muscle, the aponeurosis of the obliquus internus does not split, but, as a single layer, passes to the linea alba, exteriorly to it. The aponeurosis of the transversalis abdominis, for the superior three-fourths of the abdominal portion of the muscle, continues to the linea alba, interiorly to the muscle and the interior layer of the split aponeurosis of the obliquus internus; for the inferior quarter of the muscle portion, it passes to the linea alba exteriorly to the muscle. The exterior portion of the sheath of the rectus is formed thus: from without inward, for its superior portion, by the aponeurosis of the obliquus externus and the exterior layer of the obliquus internus; for the inferior quarter, of its abdominal portion, by the aponeuroses—in single layers of each—of the obliquus externus and internus, and the transversalis abdominis muscles. The interior portion of the sheath is deficient at the inferior quarter of the abdominal portion of the muscle; for

the superior three-quarters, it is formed—from without inward—by the interior layer of the aponeurosis of the obliquus internus and the aponeurosis of the transversalis abdominis muscle. The interior layer of the sheath is attached, superiorly, to the inferior borders of the seventh and eighth costal cartilages and the ensiform cartilage of the sternum.

31. Linea Semilunaris, Plates 23, 24, 25 and 28.—This fibrous line is formed to by the fusion of the superposed aponeuroses at the external edge of the rectus abdominis muscle.

32. Linea Alba, Plates 24 and 28.—This line is formed by the fusion of the intersecting aponeuroses of the three pairs of antero-lateral muscles, at the median line, from the symphysis pubis to the ensiform cartilage of the sternum, between the internal borders of the recti muscles.

DISSECTION.—Remove the pyramidalis abdominis muscle. Trace the nerves exterior to the transversalis abdominis muscle into the substance of the rectus abdominis muscle (Plate 26). Trace the deep epigastric artery and its branches, superiorly, through the rectus abdominis muscle, and determine their anastomoses with the superior epigastric branch of the internal mammary; preserve these arteries within the sheath, by cutting away the substance of the muscle tissue between them (Plate 28). Note the course of the spermatic cord, or of the round ligament of the uterus between the inferior edge of the transversalis abdominis muscle (Plate 27) and Poupart's ligament, upon the portion of the transversalis fascia there presenting. Cut away the obliquus externus and internus muscles, external to the lineæ semilunares; trim the aponeurotic flaps of the exterior portions of the sheaths of the recti muscles close to the lineæ semilunares and the linea alba. Cut the intercostal nerves and vessels close to their emergence from between the ribs. Cut the circumflex iliac arteries at their points of penetration of the transversalis abdominis muscles. Section the transversalis abdominis muscle: along the inferior border of the eleventh rib and the borders of the cartilages of the three lower ribs; from the eleventh rib to the ilium; along the crest of the ilium; and at its Poupart ligament attachment. Reflect an antero-lateral flap of the transversalis abdominis muscle, internally, to the linea semilunaris, where it may be cut away.

33. Transversalis Fascia, Plate 28.—This fascia lines the transversalis muscle; it is thick and well defined at its inguinal portion, but much less so superiorly; it continues, internally, to the linea alba, interiorly to the sheath of the rectus abdominis muscle.

34. Iliac (internal) Abdominal Ring.—This so-called ring is the point of emergence through the transversalis fascia of the

spermatic cord or of the round ligament of the uterus ; it is situated superior to the middle of Poupart's ligament. A process of the transversalis fascia is projected, like the tube of a funnel, inferiorly, upon the cord or the ligament, as the *internal spermatic (infundibuliform) fascia*.

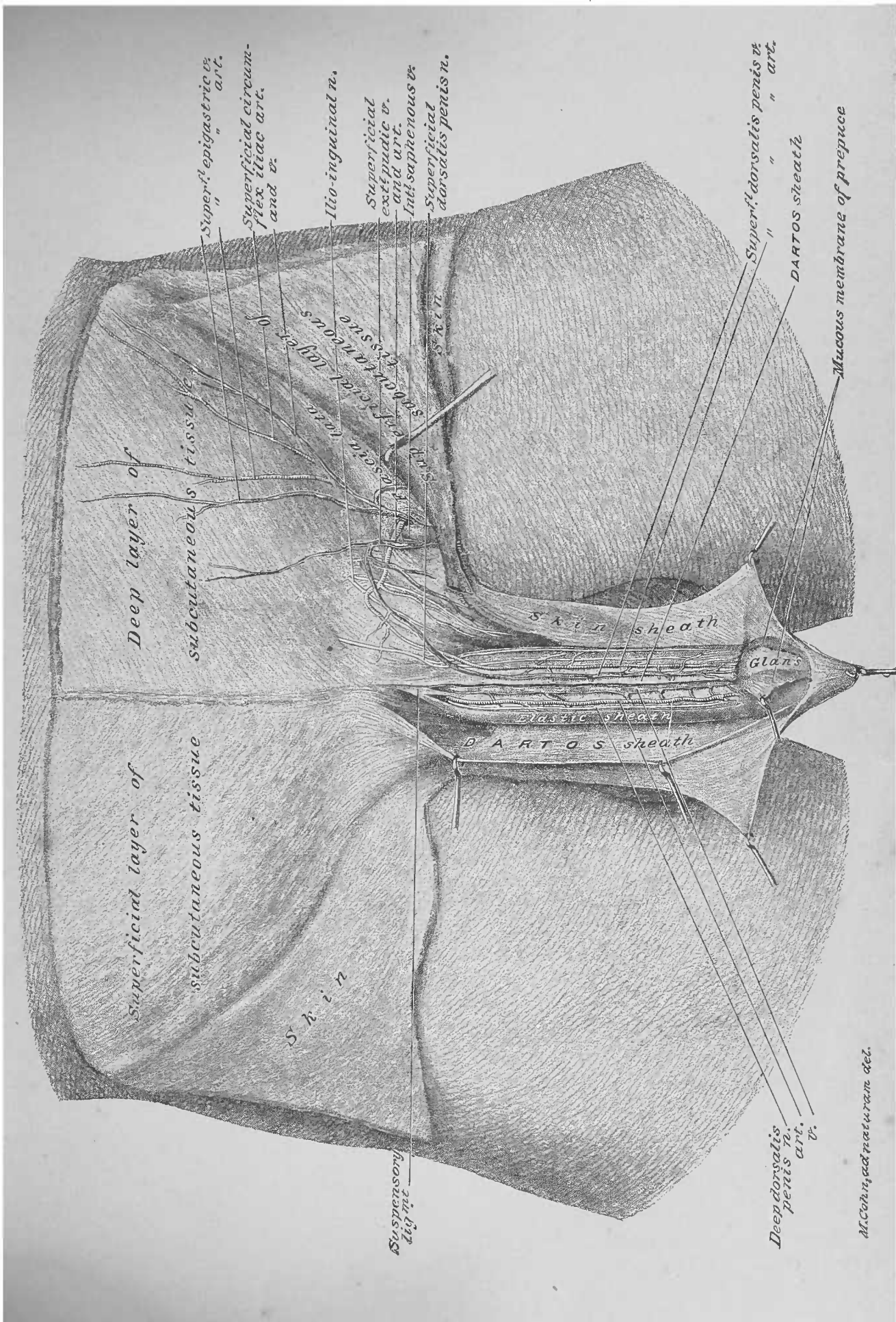
DISSECTION.—Make an incision through the transversalis fascia from the anterior superior spinous process of the ilium to the linea semilunaris. Reflect a partial inguinal flap, so as to expose the interior of the iliac (internal) abdominal ring. The guide to the reflection of this flap of fascia is the deep epigastric artery, which lies in the plane of the subserous areolar tissue between the fascia and the peritoneum. Note the transit of the elements of the spermatic cord into the funnel tube process (internal spermatic fascia) upon the cord.

35. Subserous Areolar Tissue.—This is a plane of loose fibrous tissue, between the transversalis fascia and the peritoneum. Inferior to the umbilicus, it allows the peritoneum to be readily separated from the transversalis and iliac fasciæ ; superior to the umbilicus, it is very little developed, thereby rendering the separation of the peritoneum much more difficult.

36. Deep Epigastric Artery.—This artery (vena comes) is a branch of the external iliac, which reaches the anterior parietes of the abdomen through the subserous tissue exterior to the peritoneum. It runs internal to the iliac (internal) abdominal ring, superiorly and internally, to where it enters the sheath of the rectus abdominis muscle—about on the bis-iliac line. Within the sheath it passes superiorly, through the contained muscle, and anastomoses with the superior epigastric artery ; the latter artery is one of the terminal branches of the internal mammary artery, which enters the superior part of the rectus muscle, from the thorax.

DISSECTION.—Slit up the internal spermatic (infundibuliform) fascia (Plate 28), so as to expose the spermatic cord. Distinguish the elements of the spermatic cord, and trace the same beneath the peritoneum into the iliac fossa.

37. Elements of the Spermatic Cord.—These are : the vas deferens, a hard, well-defined duct ; the spermatic veins, arteries and nerves. The vas deferens winds abruptly, internally, behind the deep epigastric artery, to pass into the pelvic cavity beneath the peritoneum ; the vessels and nerves continue, superiorly, between the peritoneum and the iliac fascia.



Deep layer of subcutaneous tissue

Superficial layer of subcutaneous tissue

S k i n

S k i n sheath

D A R T O S sheath

Glans

Superf. epigastric v. art.

Superficial circumflex iliac art. and v.

Ilio-inguinal n.

Superficial ext. pudic v. art. and v.

Int. saphenous v. Superficial dorsalis penis n.

Superf. dorsalis penis v. art.

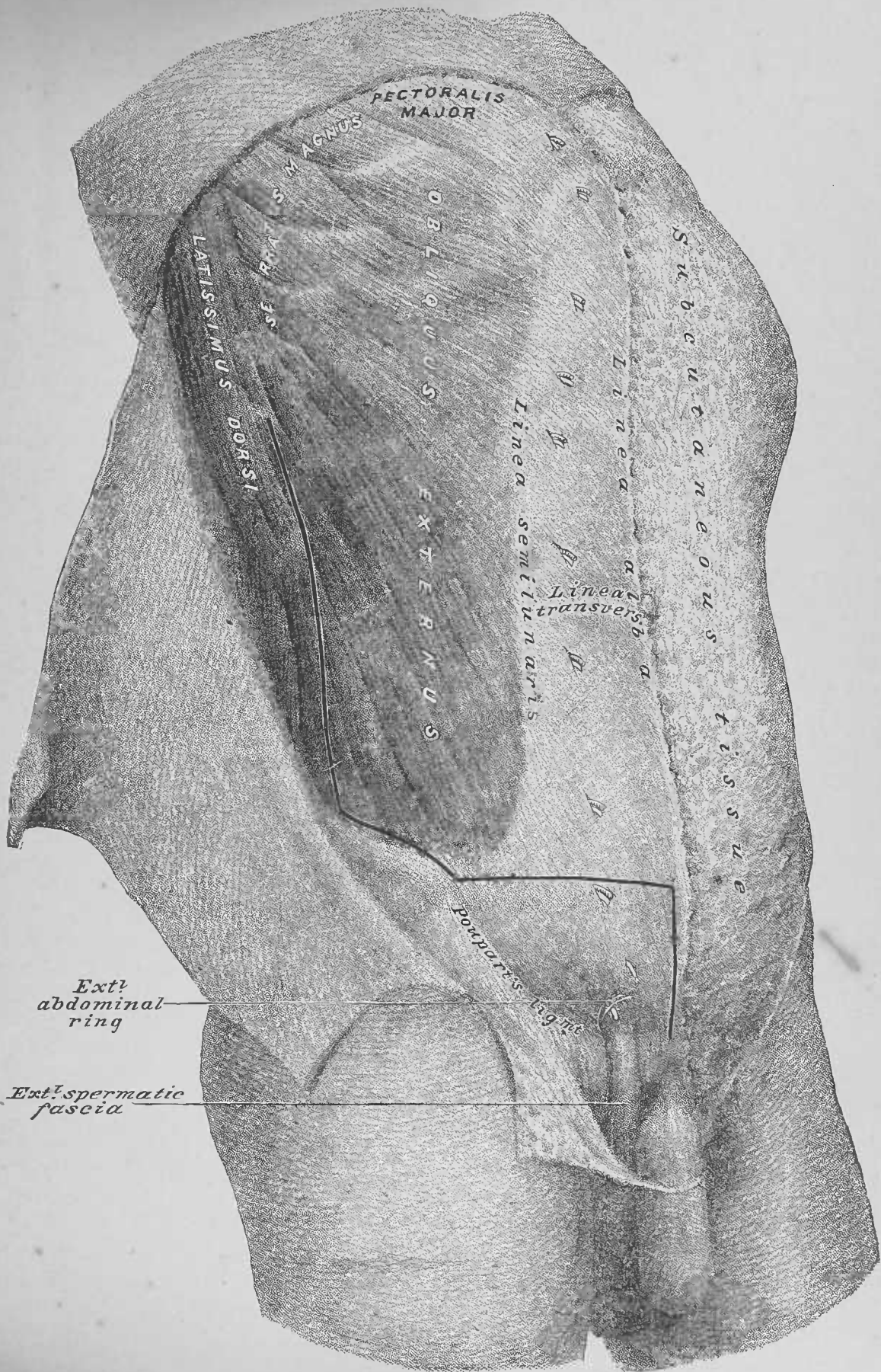
DARTOS sheath

Mucous membrane of prepuce

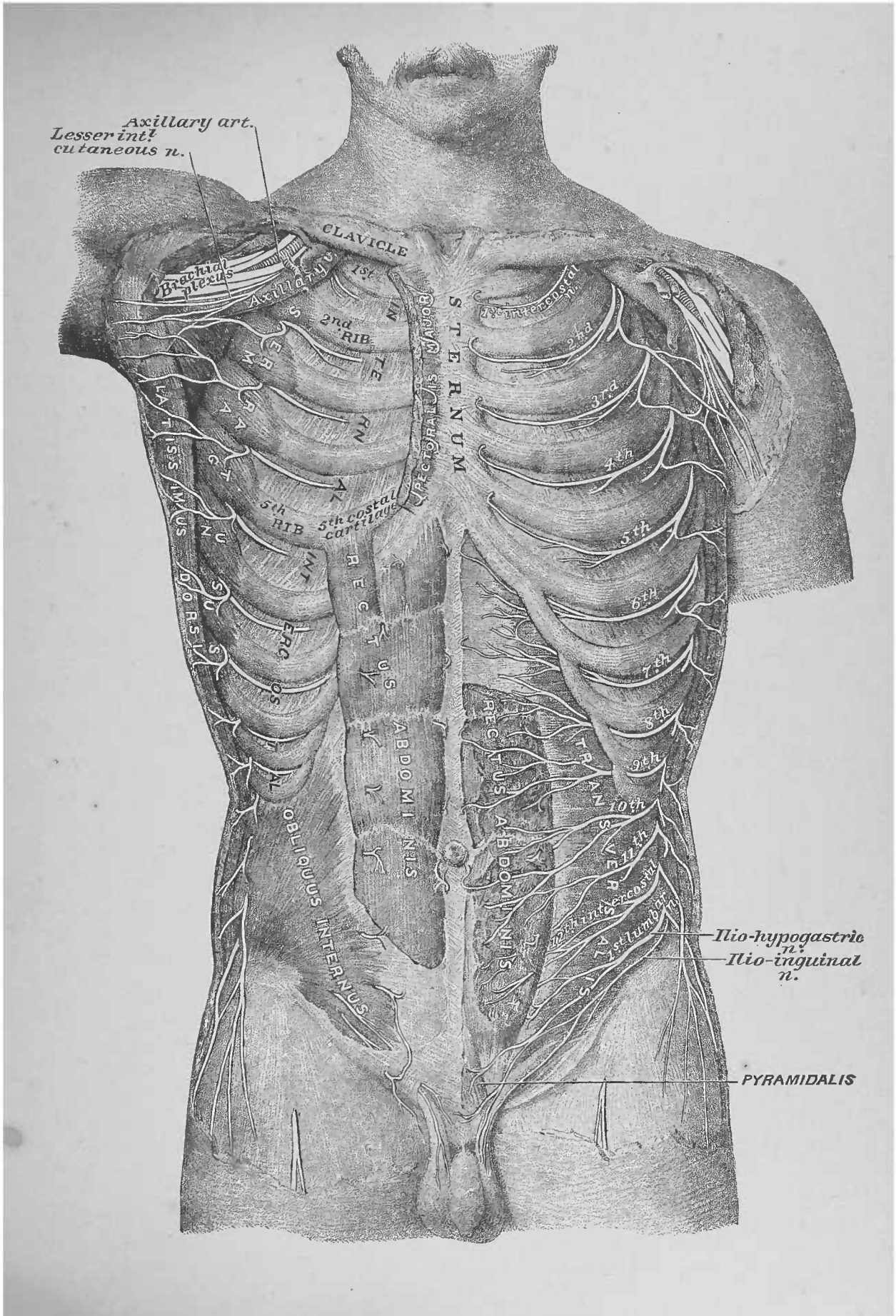
Deep dorsal v. art. n.

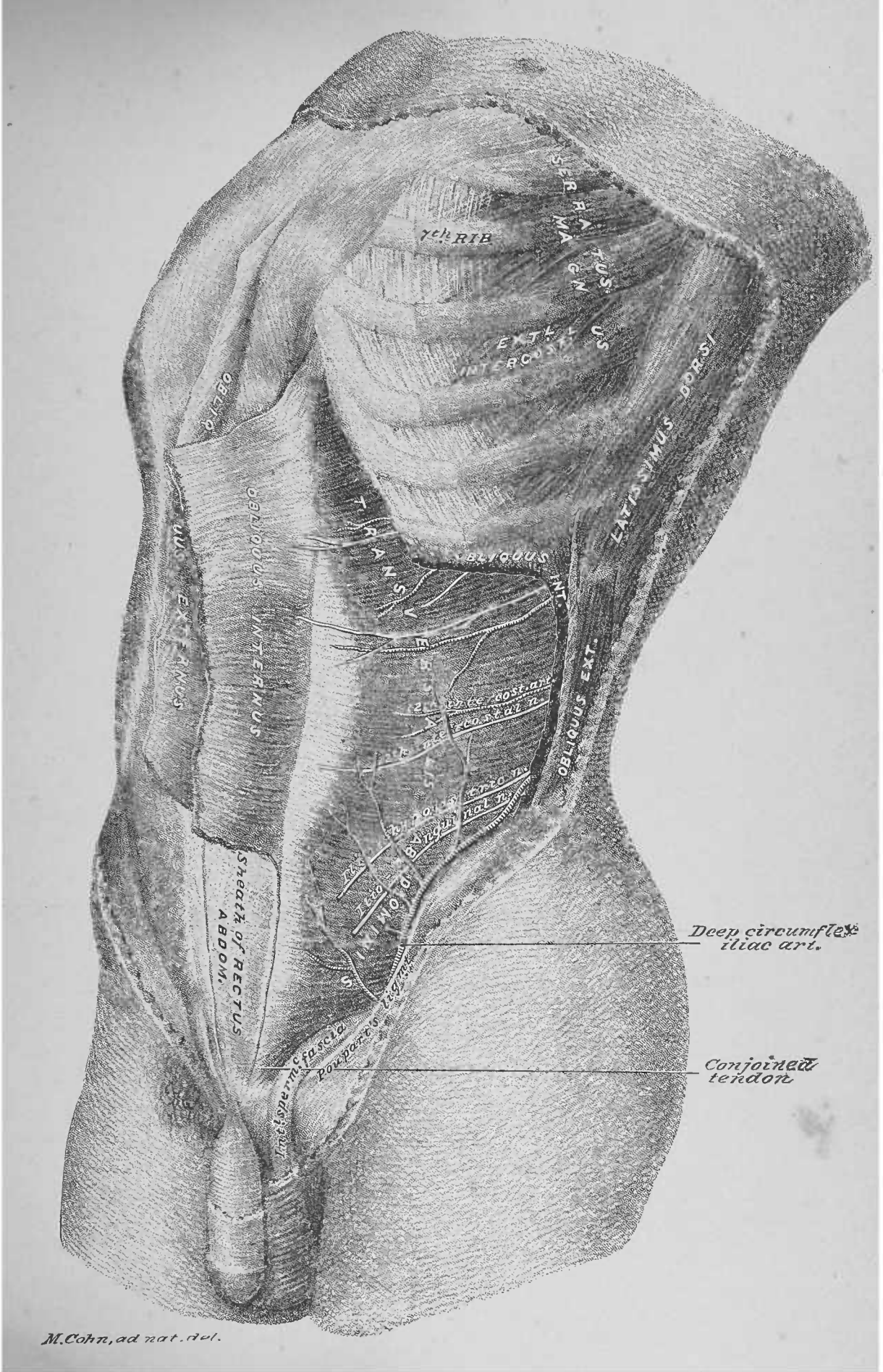
Deep dorsal v. art. n.

M. Cohn, ad naturam del.

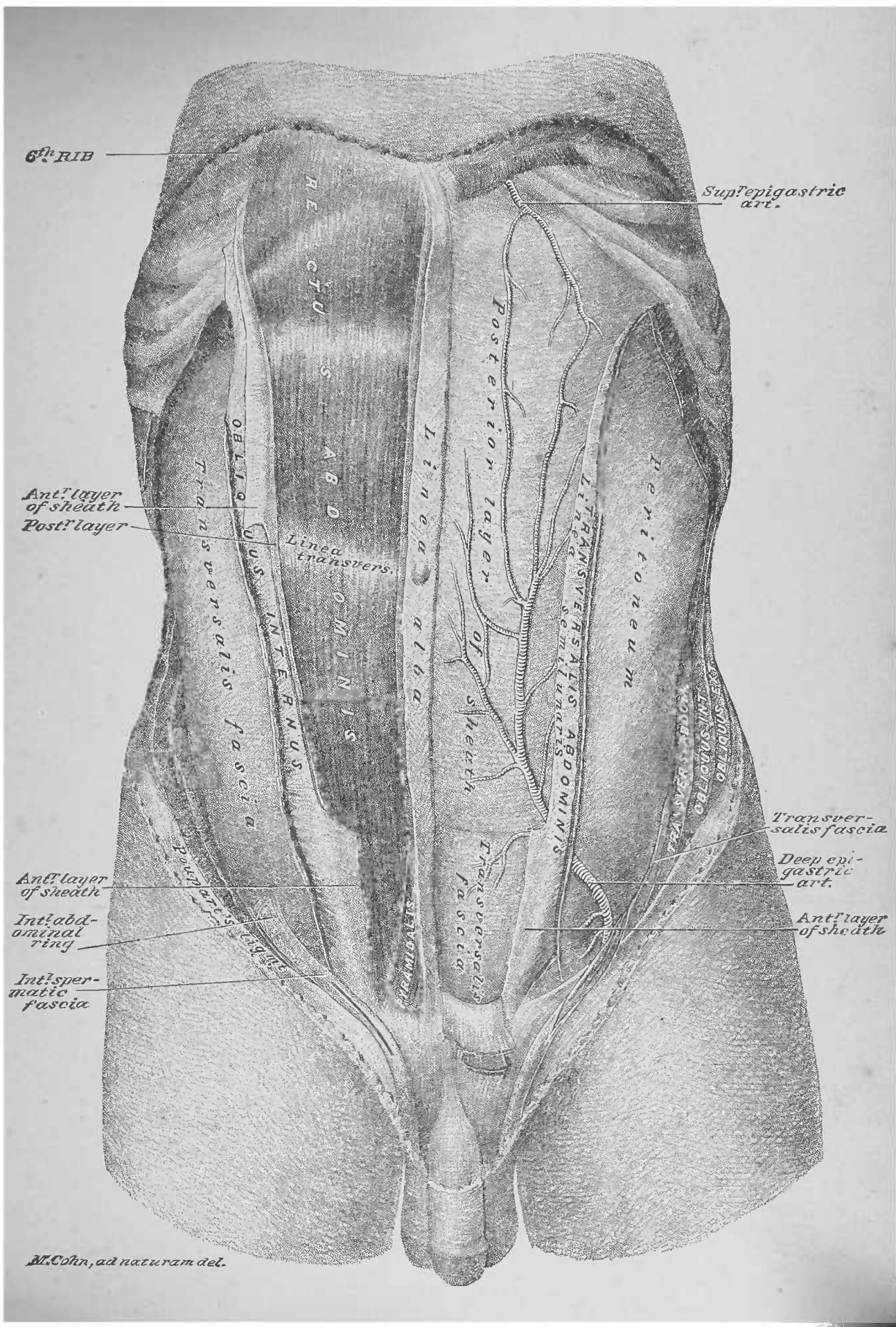


M. Cohn, ad naturam del.





SERRATUS ANTERIOR
 TRAPAZIUS
 LATISSIMUS DORSI
 OBLIQUUS INTERNUS
 OBLIQUUS EXTERNUS
 TRANSVERSARIUS
 OBLIQUUS INTERNUS
 OBLIQUUS EXTERNUS
 RECTUS ABDOMINIS
 SHEATH OF RECTUS ABDOM.
 DEEP CIRCUMFLEX ILLIAC ART.
 CONJOINED TENDON



6th RIB

Sup^repigastric art.

Ant^r layer of sheath
Post^r layer

Linea transvers.

Posterior layer of sheath

Transversalis fascia

Deep epigastric art.

Ant^r layer of sheath

Int^r abdominal ring

Int^r spermatie fascia

Ant^r layer of sheath

M. Cohn, ad naturam del.

FOURTH DISSECTION.

ABDOMINAL VISCERA IN SITU.

DISSECTION.—Clear the antero-lateral areas of the parietal layer of the greater peritoneum, by removing the interior portion of the sheath of the rectus abdominis muscle, right and left, and the transversalis fascia. Be careful in dissecting off the transversalis fascia from the peritoneum, that the latter be not torn into; indeed, the superior portion of the fascia may be left upon the peritoneum. Dissect out and preserve, *in situ*, the obliterated foetal vessels and duct, which lie between the transversalis fascia and the peritoneum.

1. Obliterated Urachus, Plate 29.—This is located along the median line from the umbilicus to the fundus of the bladder, in the plane of the subserous areolar tissue exterior to the peritoneum. In adult life it is a fibrous cord, which serves the purpose of a superior ligament to the bladder.

2. Obliterated Hypogastric Arteries.—These are located in the same plane of subserous tissue; they diverge from the umbilicus, right and left, inferiorly, to the hypogastric region, where they dip into the pelvic cavity, exterior to the peritoneum, to become continuous with the superior vesical branches, right and left, of the anterior trunks of the internal iliac arteries.

3. Greater and Lesser Peritoneum, Plates 29, 30 and 31.—These are two distinct serous membranes, which form two distinct serous cavities, which invest the sub-diaphragmatic portions of the digestive apparatus, etc., to insure their mobility upon each other in performing their respective functions and in their induced motions by respiration, etc.

DISSECTION.—Section the antero-lateral or parietal layer of the greater peritoneum (Plate 29), to the left of the median line, from the ensiform cartilage of the sternum to a point just below the umbilicus; make a second section, transversely, to the left, from the inferior end of the first; reflect the flap upon the exterior of the left lower ribs, to which it may be pinned. Demonstrate the cavity of the greater peritoneum by passing the hand and arm into it:

to the right, superiorly, recognize the broad and round ligaments of the liver ; at the middle and to the left is the stomach, with the spleen capping its fundus ; inferiorly, is the great omentum, through which the contour of the transverse colon may be felt. Introduce the hand beneath the great omentum and feel—in the middle—the convolutions of the small intestine and the under surface of the transverse colon ; to the right, the ascending colon and cæcum ; to the left, the descending colon and the sigmoid flexure ; inferiorly, the superior contours of the pelvic organs. Return the hand out of the cavity along the interior of the antero-lateral or parietal layer of the greater peritoneum.

4. Greater Peritoneum and Cavity of the Greater Peritoneum, Plates 30, 31, 32, 34, 35, and 37.—The greater peritoneum is spread, and forms its cavity, as follows : it invests the anterior of the inferior concave surface of the diaphragm (Plate 31) ; passes from the diaphragm to the stomach, by the œsophagus, and to the antero-superior surface of the liver—as the broad (Plate 30), the anterior layer of the coronary and the lateral ligaments ; from the anterior of the liver it passes to its postero-inferior surface ; from the latter surface it bridges to the lesser curvature of the stomach, as the antero-superior layer of the anterior portion of gastro-hepatic omentum ; thence it spreads over the anterior surface of the stomach (Plate 31). From the greater curvature of the stomach it bridges to the transverse colon—the anterior of two layers of serous membrane ; from the colon it is dropped (Plate 31), and then returns upon itself—*great omentum*—to the inferior surface of the transverse colon, from which it is projected to the posterior wall of the abdomen (Plate 31). At the right of the posterior wall of the abdomen it covers the duodenum, the ascending colon, and cæcum (Plate 34)—forming the ascending meso-colon and the meso-cæcum. To the left it is projected, from the line of attachment of the *mesentery* (Plate 34), as its right layer, which reduplicates by investing the jejunum and ileum ; it returns upon itself, to its line of attachment, as the left layer of the *mesentery*. To the left of the mesentery attachment it spreads to the descending colon and sigmoid flexure (Plate 35)—forming the descending meso-colon and the meso-sigmoid. From the meso-cæcum, to the right, the meso-sigmoid, to the left, and the mid-portion of the posterior of the abdominal wall, it passes into the pelvic cavity (Plates 35 and 37), covering the superior portions of the pelvic viscera—forming the meso-rectum, and liga-

ments of the uterus and bladder. From the fundus of the bladder (posteriorly to the urachus and the obliterated hypogastric arteries), by the external layer of the meso-cæcum and ascending meso-colon (at the right), and by the external layer of the meso-sigmoid and descending meso-colon (at the left), it is reflected to line the interior of the antero-lateral parietes of the abdomen (Plate 31) and returns thereby to the inferior surface of the diaphragm.

5. Broad Ligament of the Liver, Plate 30.—This, formed by two layers of the greater peritoneum, makes a scythe-shaped ligament, attached as follows: by its base to the anterior convex surface of the liver; by its convexity to the diaphragm and the interior of the right anterior wall of the abdomen; by its apex to the umbilicus; its concavity is a reduplicated free edge, from the umbilicus to the notch at the inferior border of the liver.

6. Round Ligament of the Liver.—This, the obliterated umbilical vein, is lodged, within the reduplicated free edge of peritoneum, at the concavity of the broad ligament, passing into the notch at the inferior border of the liver.

DISSECTION.—Cut the round and broad ligaments at their attachments to the abdominal parietes, and allow them to drop back upon the liver (Plate 30). Section the peritoneum—parietal antero-lateral portion—transversely to the right, and inferiorly along the left of the median line and reflect flaps. Make a transverse cut through the peritoneum between the greater curvature of the stomach and the transverse colon (Plate 30); introduce the hand into the cavity of the lesser peritoneum and feel the following: inferiorly, the transverse colon; posteriorly, the pancreas crossing the vertebral column; superiorly and anteriorly, to the left, the entire postero-inferior surface of the stomach, to the right, the portion of the lesser peritoneum, which forms the postero-inferior layer of the gastro-hepatic omentum (Plate 31). Find the foramen of Winslow (the orifice of communication of the cavity of the lesser with that of the greater peritoneum, the border of the orifice being the line of continuity of the two serous membranes): the left hand in the cavity of the lesser peritoneum, its index finger passed to the postero inferior surface of the liver, and directed transversely, and to the right, at a point posteriorly to the hepatic vessels, will enter the foramen; the right hand in the cavity of the greater peritoneum posteriorly to the right lobe of the liver, its index finger passed to the left, parallel with and posteriorly to the gall-bladder, will enter the foramen or meet the finger of the left hand, before introduced.

7. Lesser Peritoneum and Cavity of the Same, Plate 31.—The lesser peritoneum is spread, and forms its cavity, as follows: its anterior portion invests the postero-inferior surface of the stomach; superiorly to the stomach, it forms the posterior layer of the gastro-hepatic omentum; inferiorly to the stomach, it spreads as the posterior layer of the two layers of serous membrane between the greater curvature of the stomach and the transverse colon; its posterior portion covers the anterior surface of the pancreas and the abdominal vessels; and lines the antero-superior surface of the portion of the greater peritoneum from the inferior of the transverse colon to the posterior wall of the abdomen.

8. Great Omentum or Peritoneal Apron, Plates 30 and 31.—This, reduplication of the greater peritoneum, hangs in the cavity of the greater peritoneum from the transverse colon. It spreads over the small intestine, hanging lower on the left than on the right side. Superiorly, it spreads, to the right and left, upon the ascending and the descending portions of the colon, respectively.

9. Liver, Plate 30.—This organ is located interiorly to the right lower ribs and the end of the sternum, and projects interiorly to the left lower costal cartilages. The lower half of its left lobe bridges between the right and the left ribs in the epigastric region, covering the lesser curvature of the stomach.

10. Gall-Bladder.—The fundus of the gall-bladder presents below the free border of the liver, to the right of the notch, at about the extremity of the cartilage of the right tenth rib.

11. Stomach.—This viscus lies posteriorly to the left lobe of the liver, and interiorly to the left lower ribs and cartilages. Its inferior border projects below the left lobe of the liver.

12. Small Intestines.—Convulsions of this intestine will be found projecting from beneath the inferior border of the out-spread great omentum or peritoneal apron.

DISSECTION.—Raise the great omentum, and reflect it, superiorly, upon the anterior face of the thorax; carry the transverse colon upward with it.

13. Small Intestine, Plate 32.—This, the second portion of the subdiaphragmatic part of the alimentary canal, consists of three divisions: the duodenum, the jejunum and the ileum (respectively, one, eight and twelve feet long). The jejunum and ileum, *in situ*, hang toward the left inguinal region.

14. Transverse Meso-Colon.—This is the projection of peritoneum from the posterior wall of the abdomen to the transverse portion of the colon.

DISSECTION.—Collect the ileal and jejunal portions of the small intestine in the hands, and holding them off from the posterior abdominal parietes, the portion of the greater peritoneum, the mesentery, by which they are swung in the abdominal cavity, is demonstrable. Reflect the ileum and jejunum of the small intestine to the left.

15. Mesentery, Plate 34.—This is formed by two layers, right and left, of the greater peritoneum, which are attached across the interior of the posterior wall of the abdomen, from the left of the body of the second lumbar vertebra to a point opposite the right sacro-iliac articulation: the right layer spreads from its attachment, to its peripheral investment of twenty feet of the small intestine (the jejunum and ileum); the left layer returns from the intestine, narrowing to its attachment. The length of the mesentery between its attachment and the intestine varies from one and a half to six inches. Between the layers of the mesentery are lodged the superior mesenteric artery and its branches to, their venæ comites from, the lymphatic vessels from, and the nerves to, the jejunum and ileum of the small intestine; also, the mesenteric lymphatic glands.

DISSECTION.—Incise the right layer of the mesentery along the line of its attachment, and dissect the same, to the left, from off the superior mesenteric vein; trace the vein and its branches.

16. Superior Mesenteric Vein.—This vein lies to the right of and—with the small intestine swung to the left—anterior to the superior mesenteric artery. It is formed by the veins from the ileal and jejunal portions of the small intestine; the ileo-colic, colica dextra and colica media veins of the large intestine also contribute to it. The trunk, with the mesenteric artery, lies upon the duodenum; both appear between the latter and the body of the pancreas.

DISSECTION.—Cut the mesenteric vein at the trunk and dissect the branches off from the subjacent arteries (leave the stump of the vein as in Plate 34). Include a length of eight or ten inches of the small intestine between two ligatures, and inflate it with the blow-pipe. Trace the branches of the superior mesenteric artery; also the intestinal branches of the sympathetic nerve.

17. Abdominal Portion of the Sympathetic Nervous System, Plate 33.—In the course of the dissection of the arteries in the abdominal cavity, the plexuses and branches of this portion of the sympathetic nervous system will be exposed. (The Plate is introduced here, that the dissector may recognize these nerves as he meets with them upon the arteries; except as a special dissection it is not necessary to preserve them.)

18. Superior Mesenteric Artery, Plate 34.—This artery, branch of the abdominal aorta, emerges from between the pancreas and duodenum and enters between the layers of the mesentery. The trunk is directed obliquely to the right inguinal region, where it terminates by anastomosing with the ileal branch of the ileo-colic artery. From the left of the trunk are given off the intestinal branches to the jejunal and ileal portions of the small intestine; these latter, branching continuously, become the *rami intestini tenuis*, which distribute to the two surfaces of the intestine, whose walls they penetrate.

DISSECTION.—Incise the posterior layer of the peritoneum, forming the transverse meso-colon, inferior to the raised transverse colon—take the plane of the arteries beneath it as the guide of the layer—and dissect off the posterior layer of the meso-colon, exposing the colica media artery, branch of the superior mesenteric.

19. Colica Media Artery.—This artery (*vena comes*) is given off from the right side of the superior mesenteric, near its emergence from between the pancreas and the duodenum; soon after its origin it gives off the colica dextra branch. The trunk bifurcates into a right and left branch, which distribute to the transverse colon; the left branch anastomoses with the colica sinistra artery of the descending colon.

20. Colica Dextra Artery.—This branch (*vena comes*) of the last described artery extends to the right, bifurcating to distribute to the ascending colon. The superior branch anastomoses with the right branch of the colica media.

21. Ileo-colic Artery.—This is the second artery (*vena comes*), given off from the right side of the superior mesenteric trunk. It bifurcates into a superior and an inferior branch: the superior distributes to the commencement of the ascending colon, anastomosing with the inferior branch of the *colica dextra*; the inferior distributes to the *cæcum* and the terminal portion of the ileum, and anastomoses with the trunk of the superior mesenteric artery.

DISSECTION.—Tie the ileum with two ligatures at about four inches from the colon, and section the gut between them; with the straight scissors the ileum and jejunum of the small intestine may be stripped into a basin, by cutting the *rami intestini tenuis* and the mesentery, close to and parallel with the gut; the duodenum reached, apply two ligatures to the superior end of the jejunum, and section the intestine between them. Section the superior mesenteric artery the same length as the vein, and remove its trunk and branches. Trim away the great omentum or peritoneal apron from the transverse colon and the superior portions of the ascending and descending colon, respectively; also from the greater curvature of the stomach. Dissect away the transverse meso-colon (anterior layer) from the transverse colon. Spread the large intestine as in Plate 35. Follow the distribution of the inferior mesenteric artery, by dissecting off the peritoneum from the left side of the posterior wall of the abdomen, and reflecting the anterior layer of the meso of the sigmoid flexure.

22. Large Intestine, Plates 34 and 35.—This portion of the alimentary canal is divided into the *cæcum*, the colon and the rectum. The *cæcum*, lodged in the superior part of the right iliac fossa, and completely invested by peritoneum, is inferior to the ileo-colic opening—the latter at the junction of the *cæcum* and colon. From the *cæcum* is appended a blind tube, the appendix vermiformis, which curls inferiorly and is suspended by a special meso; as located it has two flexures to the left. The colon is subdivided into the ascending, the transverse and the descending; the ascending colon for its first half, is fixed to the interior of the right posterior wall of the flank, by the ascending meso-colon. The superior half of the ascending colon, the transverse colon and the superior half of the descending colon are suspended by the transverse meso-colon and the great omentum and have the greatest possible mobility; the inferior half of the descending colon is fixed to the interior of the left lumbar region by a meso-colon; the sigmoid flexure is a coil of the descending colon, which is suspended by a long meso, by

which it is made susceptible of great mobility and distention. The rectum continues the large intestine into the pelvic cavity.

23. Inferior Mesenteric Artery, Plate 35.—This artery (*vena comes*), a branch of the abdominal aorta, lies to the left of the vertebral column exterior to the peritoneum. Its *colica sinistra* branch distributes to the descending portion of the colon, bifurcating into an ascending and a descending branch: the ascending anastomoses with the left branch of the *colica media* (page 60); the descending anastomoses with the sigmoid branch. The sigmoid branch supplies the sigmoid flexure of the colon; its distribution is similar to that of the *rami intestini tenues* (see page 60, and Plate 34). The superior hemorrhoidal is the terminal portion of the trunk; it distributes to the superior part of the rectum, passing into the pelvic cavity upon the gut, between the layers of the meso-rectum of the pelvic portion of the greater peritoneum.

DISSECTION.—Dissect off the posterior layer of the lesser peritoneum from the anterior surface of the pancreas, trimming it away at the superior edge of the oblique portion of the duodenum; by this the head of the pancreas will be exposed in the curve of the duodenum. Hook up the left lobe of the liver against the costal cartilages and sternum; open the anterior layer of the gastro-hepatic omentum, and cut it away from the lesser curvature of the stomach, and from the opposite posterior inferior surface of the liver. Determine the parts, contained between the layers of the gastro-hepatic omentum.

24. Coeliac Axis, Plates 35 and 36.—This arterial axis presents superior to the lesser curvature of the stomach, where it trifurcates into: the gastric or coronary, which passes to the left and superiorly; the splenic, which is directed to the left and inferiorly; the hepatic, which runs to the right.

25. Gastric or Coronary Artery.—This artery (*vena comes*) distributes to the stomach. Reaching the left of the lesser curvature of that organ, it bifurcates: the left branch distributes to the œsophageal extremity of the stomach, anastomosing with the œsophageal arteries; the right curves along the lesser curvature of the stomach, to anastomose with the pyloric branch of the hepatic.

26. Splenic Artery.—This artery (*vena comes*) disappears posterior to the stomach in the direction of the organs it supplies.

27. Hepatic Artery.—This trunk is directed to the right, superior to the pyloric end of the stomach; it gives off the gastro-duodenal and the cystic (to the gall-bladder) arteries, after which it divides into branches, which enter the transverse fissure of the liver.

DISSECTION.—Trace the cystic artery to the gall-bladder; dissect off the peritoneum from the exposed surface of that organ, from its fundus to its apex; find the cystic duct and follow it to the ductus communis choledochus; clear the surface of the exposed portion of the latter duct. Raise the branches of the hepatic artery and clean the surface of the vena portæ, lodged to the left of the ductus communis choledochus.

28. Cystic Artery.—This artery (vena comes), branch of the hepatic or gastro-duodenal, bifurcates and distributes to the gall-bladder, beneath its investiture of peritoneum.

29. Cystic Duct.—This is a short duct, from the apex of the gall-bladder, to the ductus communis choledochus; it joins the latter at an acute angle.

30. Ductus Communis Choledochus.—The right and left hepatic ducts meet and form the hepatic ducts proper; the latter is joined by the cystic duct, and the two determine the ductus communis choledochus. It courses in the right portion of the gastro-hepatic omentum, and disappears posterior to the first or ascending portion of the duodenum.

31. Stomach.—This organ occupies the left hypochondriac region, extending to the right into the epigastric region. It is swung in the abdominal cavity: to the left, by the œsophagus as the latter pierces the diaphragm, and by a reflection of peritoneum to the diaphragm; to the right, from the liver, by the gastro-hepatic omentum. The mobility and independence of the organ is insured, as before shown, by the cavity of the lesser peritoneum posterior to it. Its œsophageal extremity, or point of continuity with the œsophagus at the diaphragm, is situated superiorly and to the left; its pyloric extremity or the pylorus is to the right and continuous with the duodenum. To the left of the œsophagus is its fundus or larger end, which tilts superiorly against the diaphragm; the pyloric valve guards its communication with the first portion of the duodenum. Its varying calibre and its elevation to the left, superiorly, deter-

mine its superior and inferior curvatures : the former is a concavity directed superiorly and to the right ; the latter is a convexity directed inferiorly and to the left. It will be remembered, that its anterior surface is covered by a layer of peritoneum, contributed by the greater peritoneum, while its posterior surface has a peritoneal investiture, furnished by the lesser peritoneum. At its fundus the spleen is adapted to the right concave surface of the latter ; the peritoneum bridges between the two organs—the gastro-splenic omentum—and invests the free convex surface of the spleen. The peritoneal surface investments of, and the apposition of the spleen to, the stomach—determine the absence of serous membrane at the curvatures and fundus of the organ. It is at these points, that vessels and nerves enter and leave the viscus : along the lesser curvature is the anastomosing arterial loop of the gastric and pyloric arteries ; along the greater curvature is the circuit of the anastomosing gastro-epiploica dextra and sinistra arteries ; the vasa brevia, branches of the splenic artery, are at the fundus. Along this circumferential arterial distribution arteries and nerves enter the walls of the organ ; veins and lymphatics leave them.

32. Duodenum.—This, the first portion of the small intestine, is continued from the pylorus of the stomach. It is somewhat the shape of a fish-hook, with its convexity directed to the right and inferiorly, its concavity open superiorly and to the left. The first or ascending portion of the duodenum—forming the short barbed end of the hook—is directed from the pylorus of the stomach to the right, and is inclined superiorly and posteriorly (in Plates it will be observed to have sagged inferiorly). The second or descending portion—forming the curve of the hook—has a direction obliquely from above downwards and to the left. The third, transverse or oblique portion—forming the shank of the hook—rises obliquely from right to left, crossing the median line just above the bifurcation of the abdominal aorta ; at the left of the vertebral column, it is continued by the jejunum of the small intestine. Its most dependent point lies upon the anterior surface of the inferior half of the quadratus lumborum muscle, a little above the posterior extremity of the crest of the right ilium. *In situ*, the first portion of the duodenum impinges upon the liver and the

gall-bladder; the posterior surface of the descending portion rests upon the right kidney; the concavity of this intestinal segment receives the head of the pancreas; the transverse colon is superposed upon its anterior surface.

DISSECTION.—Inflate the stomach and duodenum by means of the blow-pipe; introduce the latter into the anterior wall of the duodenum. Pull the right half of the stomach superiorly, and to the right, upon the anterior surface of the right costal cartilages and the ensiform cartilage of the sternum. Dissect the first and half of the second portion of the duodenum from the head of the pancreas; in so doing drag upon the stomach, superiorly, by a loop of string around the pylorus, until it and the duodenum assume the position shown in Plate 36. Trace the gastro-duodenal artery and its branches, also the ductus communis choledochus. Pull aside the left inferior costal cartilages. Clear the anterior surface of the pancreas, noting its relations to the duodenum, superior mesenteric vessels, the splenic artery and vein and the spleen itself. Remove the anterior portion of the gastro-splenic omentum; reflect the spleen externally, and note the terminal branches of the splenic artery.

33. Pancreas.—This organ lies transversely and obliquely across the abdomen: its right extremity is included in the concavity of the duodenum; its body rests upon the mesenteric vessels; its tail crosses over the left kidney, the tip of the former impinging upon the spleen. The inferior border of its head overlaps the anterior surface of the commencement of the third or oblique portion of the duodenum. Anteriorly, the stomach and the transverse colon are superposed upon it.

34. Gastro-Duodenal Artery.—This artery (vena comes) is the largest branch of the hepatic. It curves, inferiorly, posterior to the first portion of the duodenum. It gives off the pyloric artery, and bifurcates into the gastro-epiploica dextra and the superior pancreatico-duodenal arteries.

35. Pyloric Artery.—This branch (vena comes) of the gastro-duodenal or the hepatic artery curves to the left, along the lesser curvature of the stomach, and anastomoses with the gastric or coronary artery.

36. Gastro-Epiploica Dextra Artery.—This vessel (vena comes) curves to the left, along the greater curvature of the stomach, anastomosing with the gastro-epiploica sinistra, branch from the splenic artery.

37. Superior Pancreatico-Duodenal Artery, Plate 36.—Curving inferiorly, from its origin, this artery (*vena comes*) passes along the concavity of the duodenum and the head of the pancreas, to anastomose with the inferior pancreatico-duodenal, branch of the superior mesenteric artery.

38. Inferior Pancreatico-Duodenal Artery.—This artery (*vena comes*) passes from the right of the superior mesenteric artery, where its trunk lies posterior to the head of the pancreas. It is directed, inferiorly and to the right, between the pancreas and the oblique portion of the duodenum, to the right of the superior mesenteric vein. Between the pancreas and the duodenum it anastomoses with the last described artery.

39. Spleen, Plates 35 and 36.—For the present, the dissector should determine the location of the spleen as it caps the fundus of the stomach; its relations to the tail of the pancreas; and its lodgment anterior and external to the left suprarenal capsule and the superior half of the left kidney.

40. Splenic Artery.—This trunk, branch of the *cœliac axis*, runs to the left, posterior to the superior border of the body and tail of the pancreas. (In the plate the artery is somewhat displaced above the organ, by the sagging of the pancreas and the raising of the artery to clean it.) In its course the artery distributes branches to the pancreas, and the *gastro-epiploica sinistra* is given off from it. Thence it continues to distribute the splenic branches proper, from which, in turn, the *vasa brevia* or its gastric branches pass to the fundus of the stomach.

DISSECTION:—Hook the superior border of the pancreas anteriorly, to discover the splenic vein; clean the same, noting its contributing branches, etc.

41. Splenic Vein, Plate 48.—This vein will be found posterior to the body and tail of the pancreas, running to the right to meet the superior mesenteric vein to form the *vena portæ*. In its course this vein will be seen to receive the trunk of the inferior mesenteric vein.

42. Gastro-Epiploica Sinistra Artery, Plate 36.—This artery (*vena comes*), branch of the splenic, curves to the right,

along the greater curvature of the stomach to anastomose with the gastro-epiploica dextra, as before shown (page 65).

43. Ductus Communis Choledochus.—This duct, already recognized in a part of its course, can now be followed to where it enters the duodenum; if care be taken, the junction of the pancreatic duct with it—emerging from the head of the pancreas—may be discovered.

DISSECTION.—Restore the stomach and duodenum to their normal positions. Raise the cut distal portion of the sigmoid flexure of the colon out of the pelvic cavity, and pin it into the left iliac fossa, making the rectum taut. Remove with a sponge any fluid, that may be lodged between the pelvic organs.

44. Male Pelvic Organs, *in situ*, Fig. 1, Plate 37.—The superior contours of these organs will be found to include the rectum, to the left, posteriorly, and the bladder anteriorly. Between the two is the recto-vesical cul-de-sac of the peritoneum.

45. Male Pelvic Reflections of the Greater Peritoneum, Plate 29 and Fig. 1, Plate 37.—The greater peritoneum is reflected from the interior of the anterior abdominal parietes—interior to the obliterated urachus and hypogastric arteries—to the middle and sides of the fundus of the bladder (page 55); from the fundus of the bladder it continues, posteriorly, over its superior and lateral contours to its posterior surface; it descends to the base line of the exterior trigone area of the bladder (Male Perineum, page 26, Plate 12), where it is reflected to the anterior surface of the rectum, forming the recto-vesical cul-de-sac. This cul-de-sac is bounded, laterally, by crescentic folds of the peritoneum, the plicæ semilunares, which bridge between the two organs. The serous membrane rises upon the surface of the antero-lateral walls of the rectum—more on its right than its left side. To the right of the rectum—the superior part of its second portion—it is reflected to the posterior wall of the pelvic interior, forming the right portion of the meso-rectum; which continues, laterally and superiorly, upon the right iliac vessels. From the left side of the rectum—the superior part of its second portion—it passes to the left side of the pelvic interior, forming the left portion of the meso-rectum, which in turn continues, superiorly, over the left iliac

vessels into the iliac fossa. The meso-rectum is thus the portion of the greater peritoneum, by which the second portion of the rectum is fixed to the posterior and left lateral walls of the pelvic interior. The first portion of the rectum—from a point opposite the left sacro-iliac articulation to the anterior of the second piece of the sacrum—is swung by the continuation of the meso-sigmoid folds of the greater peritoneum (Plate 35). It is between the latter layers, that the superior hemorrhoidal branch of the inferior mesenteric artery continues to the rectum (Plate 35).

46. Retzius' Space, Plate 31.—The anterior surface of the bladder is not covered by peritoneum; the latter is reflected from the former posterior to the point of continuity of the urachus with the bladder. A space exists bounded, posteriorly, by the anterior surface of the bladder; anteriorly, by the interior surfaces of the symphysis pubis and the os pubis, right and left. This is Retzius' space (Adolph Retzius, a Swedish anatomist); it contains loose areolar tissue, and has, below the level of the inferior border of the symphysis pubis, surrounding the neck of the bladder, a venous plexus, which continues, posteriorly, to the sides of the prostate and vesiculæ seminales.

47. Rectum, Fig. 1, Plate 37.—This portion of the large intestine continues from the sigmoid flexure of the colon, at a point about opposite the left sacro-iliac articulation. Its first and the superior part of its second portion present, *in situ*, as we look into the pelvic cavity from above.

48. Bladder.—This organ varies in its position at different ages: in the child, it is almost an abdominal organ, being located largely above the brim of the pelvis; in the adult, it becomes a pelvic organ, being lodged below the brim of the pelvis. In the adult male—except when distended—it is located between the symphysis pubis and the bodies of the ossa pubis, anteriorly, and the rectum, posteriorly.

49. Female Pelvis, Fig. 2, Plate 37.—As compared with the male, the female pelvic diameters are all much greater; the increased capacity of the pelvic cavity affords lodgment for the internal female genitalia, viz.: the vagina, the uterus, the Fallopian tubes, the ovaries, etc.

50. Peritoneum of the Female Pelvis.—As in the male, the peritoneum reaches the fundus of the bladder from the interior of the anterior parietes of the abdomen, guided thereto by the obliterated urachus (Plate 29). From the fundus of the organ it passes to its posterior surface, from which it is reflected to the body of the uterus. This reflection determines the vesico-uterine cul-de-sac of the peritoneum. The peritoneum upon the anterior surface of the uterus spreads laterally therefrom—forming the anterior layer of the broad ligament—to the interior of the lateral wall of the pelvis. Folding over the fundus of the uterus it covers its posterior surface and continues inferiorly upon the posterior surface of the inferior wall of the vagina, from which it is reflected to the anterior surface of the superior wall of the rectum, forming the recto-vaginal or Douglas' cul-de-sac of the peritoneum (Female Perineum, page 41). From the postero-inferior surface of the uterus and vagina the peritoneum spreads laterally, as the posterior layer of the broad ligament of the uterus, to the interior of the lateral walls of the pelvis; from this posterior layer of the broad ligament the right and left ovaries swing free. Continuing upon the rectum, the peritoneum invests it as in the male (page 67).

51. Female Internal Genitalia.—These are the uterus, the Fallopian tubes, the round ligaments—included between the two layers of the right and left broad ligaments—and the ovaries—hanging from the posterior surfaces of the broad ligaments. They are all lodged in the pelvis between the bladder, anteriorly, and the rectum, posteriorly. The uterus projects superiorly, supported upon the vagina; the Fallopian tubes, the right and the left, curl posteriorly and internally, posterior to the uterus, enclosing the right and the left ovary, respectively; from out of the pelvic cavity the right and the left round ligaments of the uterus rise over the brim of the pelvis, anterior to the uterus, to reach the right and left iliac or internal abdominal rings (Abdominal Parietes, page 53).

52. Female Bladder.—In the female the bladder is broader than in the male; in other respects the organs are alike (page 68). The special relation of the organ in the female is to the uterus posteriorly; at the anterior surface of the supra-

vaginal portion of the neck of the uterus the bladder is attached by connective tissue; it is separated from the body of the uterus by the vesico-uterine cul-de-sac of the greater peritoneum.

53. Female Rectum.—This is located so much like the male rectum, that the description of the lodgment of the latter (page 68) will answer for both.

DISSECTION.—Drag down the stomach from the left; apply a ligature at its œsophageal extremity and cut above the ligature. Turn out the stomach and the spleen from the left. Dissect loose the pancreas and duodenum on their posterior surfaces. Replace the stomach, duodenum, pancreas and spleen. Follow up the vena cava inferior to the posterior surface of the right lobe of the liver; apply a ligature to it above the renal veins, and cut the vessel. Drag down the liver from the right; determine the antero-superior layer of the coronary and the two lateral ligaments of the liver; with the curved scissors cut these ligaments close to the diaphragm. Continuing to drag on the liver, recognize with the finger the vena cava, as it pierces the diaphragm at the caval opening; pass a ligature around it and cut the vessel below it. Cut the remaining postero-inferior layer of the coronary ligament with the curved scissors, close to the diaphragm. Cut the trunk of the cœliac axis, and the stump of the superior mesenteric artery. Remove the stomach, duodenum, pancreas and liver, *en masse*. Remove the peritoneum from the abdominal aorta, the common, the external and the internal iliac arteries; in so doing note the nerves of the plexuses of the sympathetic (Plate 33), which ramify upon the arteries.

54. Abdominal Aorta, Plate 38.—This arterial trunk enters the abdominal cavity opposite the body of the twelfth dorsal vertebra, between the crura of the diaphragm; the latter are applied to its lateral surfaces. It continues on the vertebral column to the fourth lumbar vertebra, where it bifurcates into the right and the left common iliac arteries. In its course it gives off distributing branches: the two phrenic, the cœliac axis, the two suprarenal, the superior mesenteric, the two renal, the two spermatic or the two ovarian, the inferior mesenteric, the four pairs of lumbar and the sacra media.

55. Cœliac Axis.—This arterial axis springs from the anterior face of the aorta, and trifurcates as before described (page 62).

56. Suprarenal Arteries.—These arteries (*venæ comites*) branch, right and left, to the respective suprarenal capsules.

DISSECTION.—Clear the surfaces of the right and left suprarenal capsules.

57. Suprarenal Capsules.—These organs are lodged upon the surfaces of the right and left crus of the diaphragm, respectively. They are triangular in shape, their apices tilted to the median line, their bases capping the superior convex ends of the kidneys.

58. Superior Mesenteric Artery.—This, like the cœliac axis, is a median-line branch of the abdominal aorta; it distributes as before described (page 60).

DISSECTION.—Clear the surface of the vena cava from its origin, inferiorly, to its point of section, superior to the renal veins. Note the veins, that it receives in its course; follow the renal veins from the kidneys.

59. Vena Cava Inferior.—This venous trunk lies to the right of the vertebral column; it is formed by the junction of the right and left common iliac veins, at the right of the fifth lumbar vertebra; it receives the sacra media, the lumbar, the right spermatic or the right ovarian, the renal, the suprarenal, the phrenic and the hepatic veins.

60. Renal Veins.—These vessels pass from the kidney, right and left, to the vena cava; the left, longer than the right, receives the left spermatic or the left ovarian vein.

DISSECTION.—Hook the renal veins anteriorly, and trace the renal arteries to their distribution. Dissect the kidneys free of remaining fat.

61. Renal Arteries.—These arteries pass, right and left, from the aorta to the kidneys, respectively; their short trunks break up into branches, which enter the hilus of the organ; one of the superior branches of each artery distributes a branch to the suprarenal capsule of the side.

62. Kidneys.—These organs are located on either side of the vertebral column. The inferior portion of a kidney lies upon the superior half of a quadratus lumborum muscle; its superior convex end inclines to the vertebral column, and rests upon the interior of the ligamentum arcuatum externum (Plate 43) and the diaphragm above it; where it lies upon the latter muscle, it is located opposite the twelfth rib and the eleventh intercostal muscle and rib—the right kidney rises to the infe-

rior border of the eleventh rib, while the left reaches its superior border. Its external border is convex and projects beyond the external border of the quadratus lumborum muscle; its inferior convex end inclines a little, externally—higher upon the left than upon the right side; its internal and thickest border presents an inferior and a superior convexity, divided by a concavity—the hilus of the organ—where the arteries and nerves enter, and the veins, lymphatic vessels and the ureter leave the organ; its anterior surface is smooth and convex.

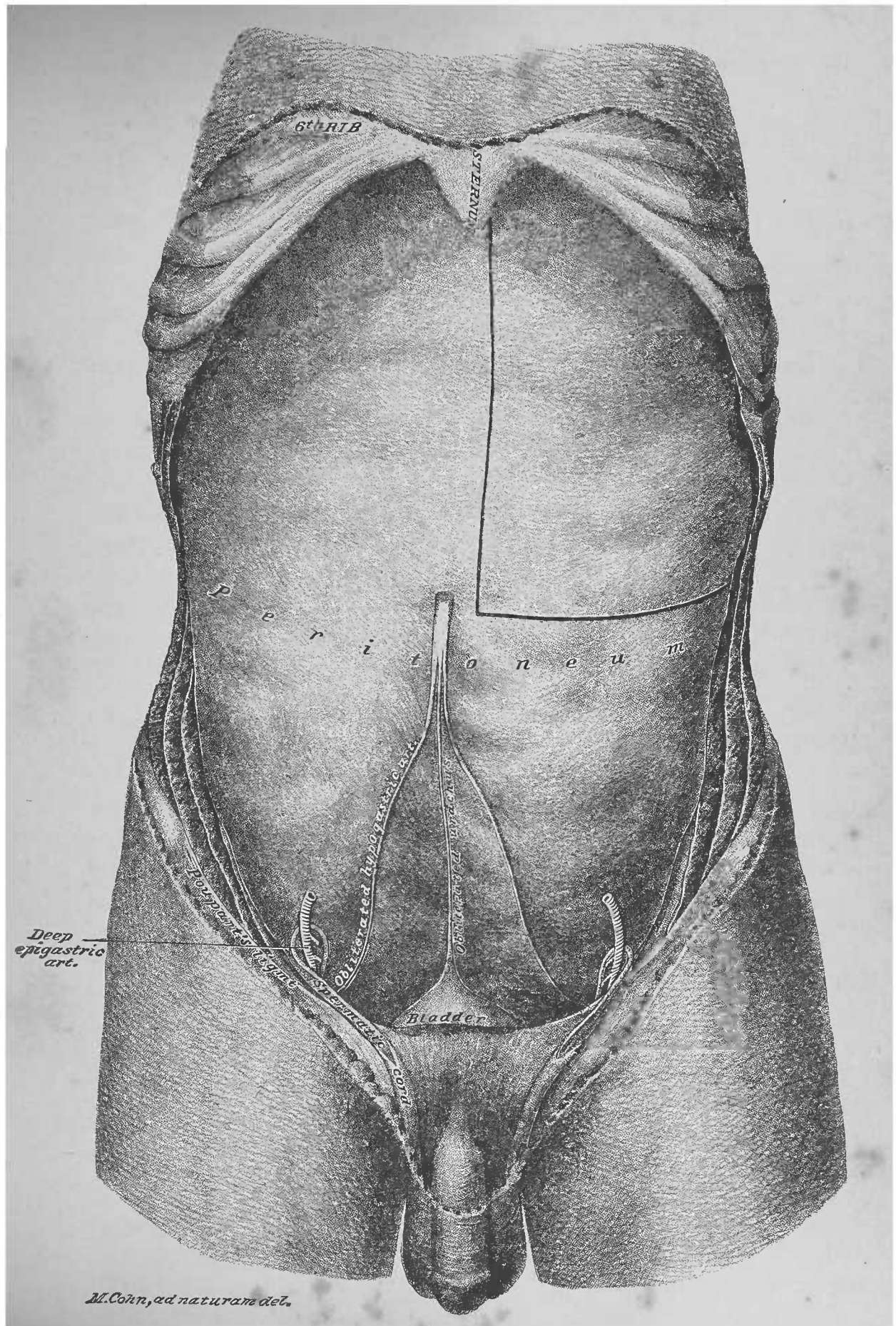
DISSECTION.—Trace the ureters from the kidneys, inferiorly, into the pelvis.

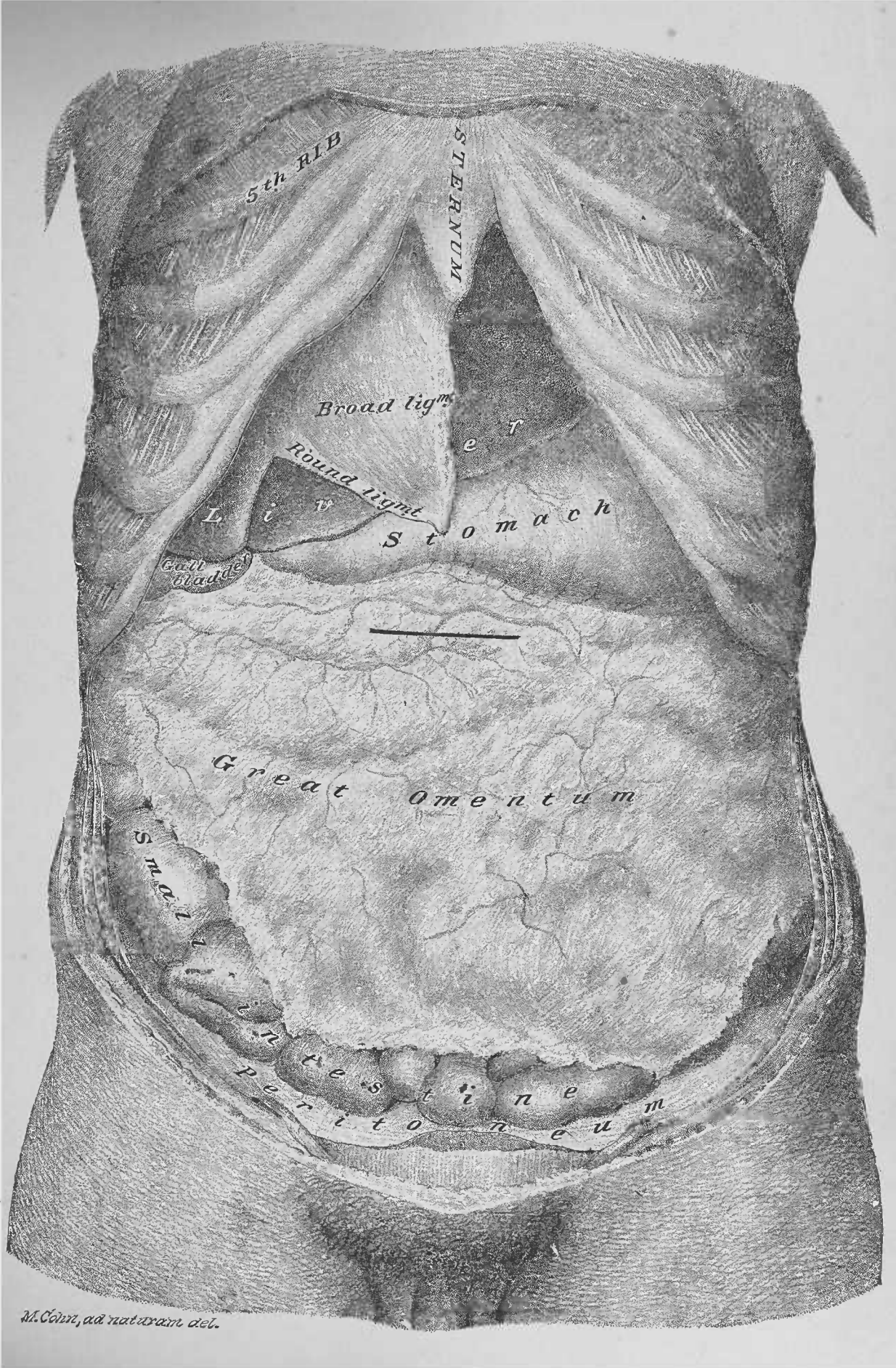
63. Ureters.—These are the ducts of the kidneys. A ureter is about fifteen inches long; it leaves the hilus of a kidney, posterior to the plane of the artery; it continues, inferiorly and internally, upon the anterior surface of the quadratus lumborum, the psoas magnus and the psoas parvus muscles, posterior to the spermatic or the ovarian vessels; it reaches the external iliac artery, passing across its anterior surface, near the bifurcation of the common iliac, and enters the pelvic cavity upon the interior of its lateral wall.

64. Spermatic (of the Male) and Ovarian (of the Female) Arteries.—These arteries spring as a pair, in the respective sexes, one from either side of the aorta, inferior to the origins of the renal branches. A spermatic artery (vena comes) passes, inferiorly and externally, upon the psoas magnus and parvus muscles to the groin, where it leaves the abdominal cavity by the iliac or internal abdominal ring. An ovarian artery (vena comes) passes inferiorly to the iliac fossa; it enters the pelvic cavity, crossing the external iliac artery, to reach the interior of its lateral wall, between the anterior and posterior layers of peritoneum, which form a broad ligament of the uterus.

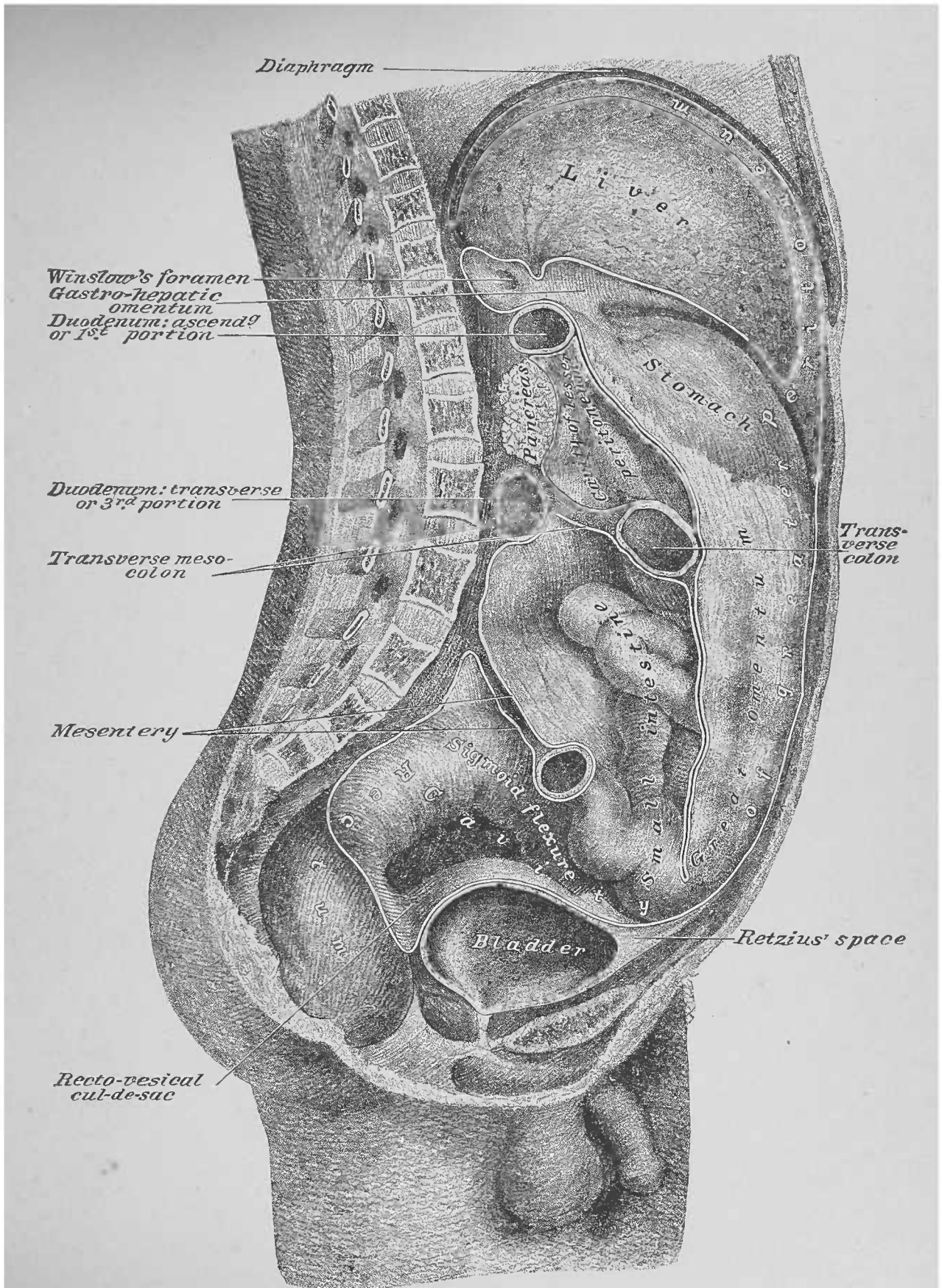
65. Spermatic and Ovarian Veins.—The right and left veins differ: the right spermatic and ovarian empty, at an acute angle, into the vena cava inferior; the left can be traced to where it enters, at a right angle, into the left renal vein.

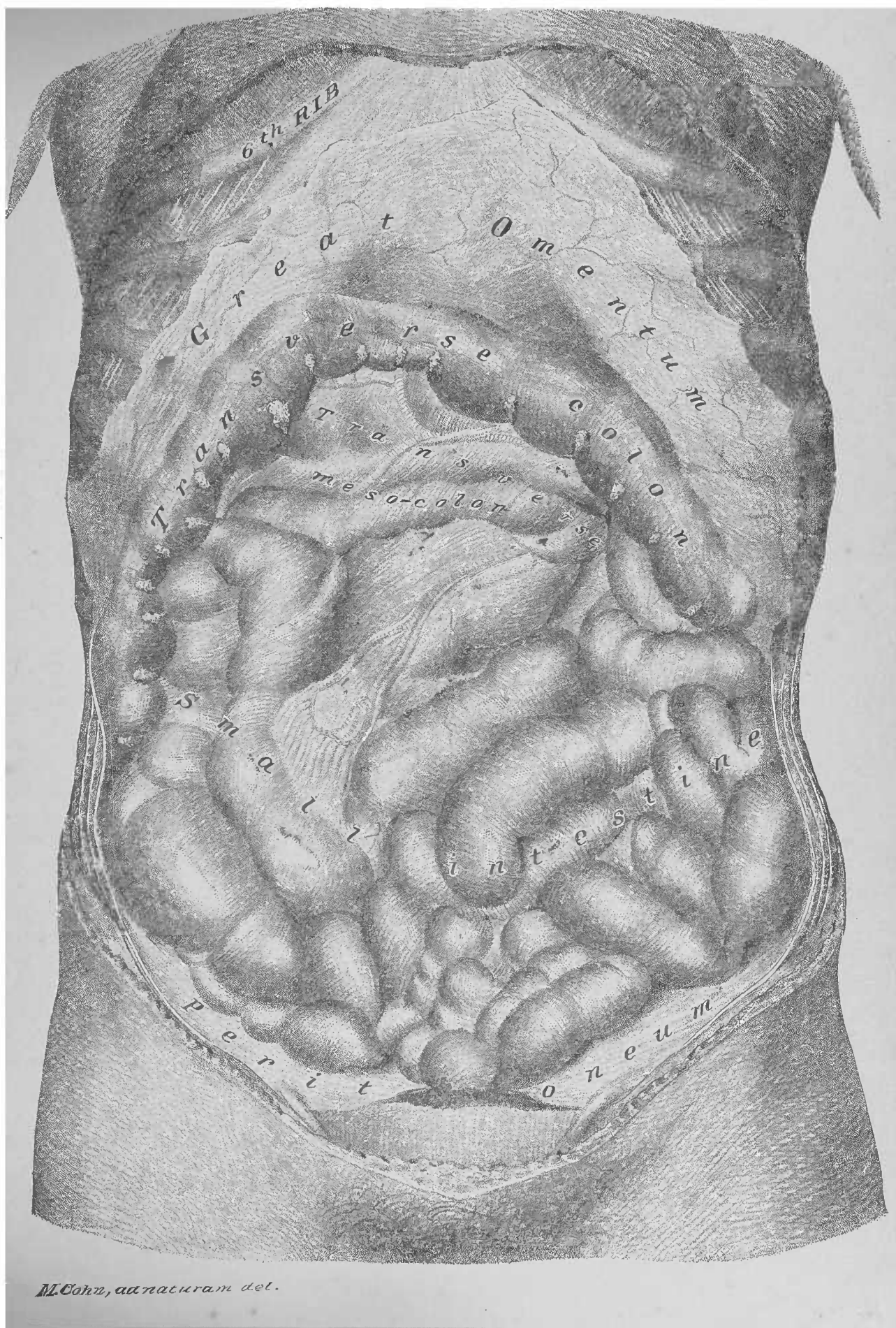
66. Inferior Mesenteric Artery.—This artery (vena comes), a single branch, passes to the left of the vertebral column, and distributes as before described (page 62).



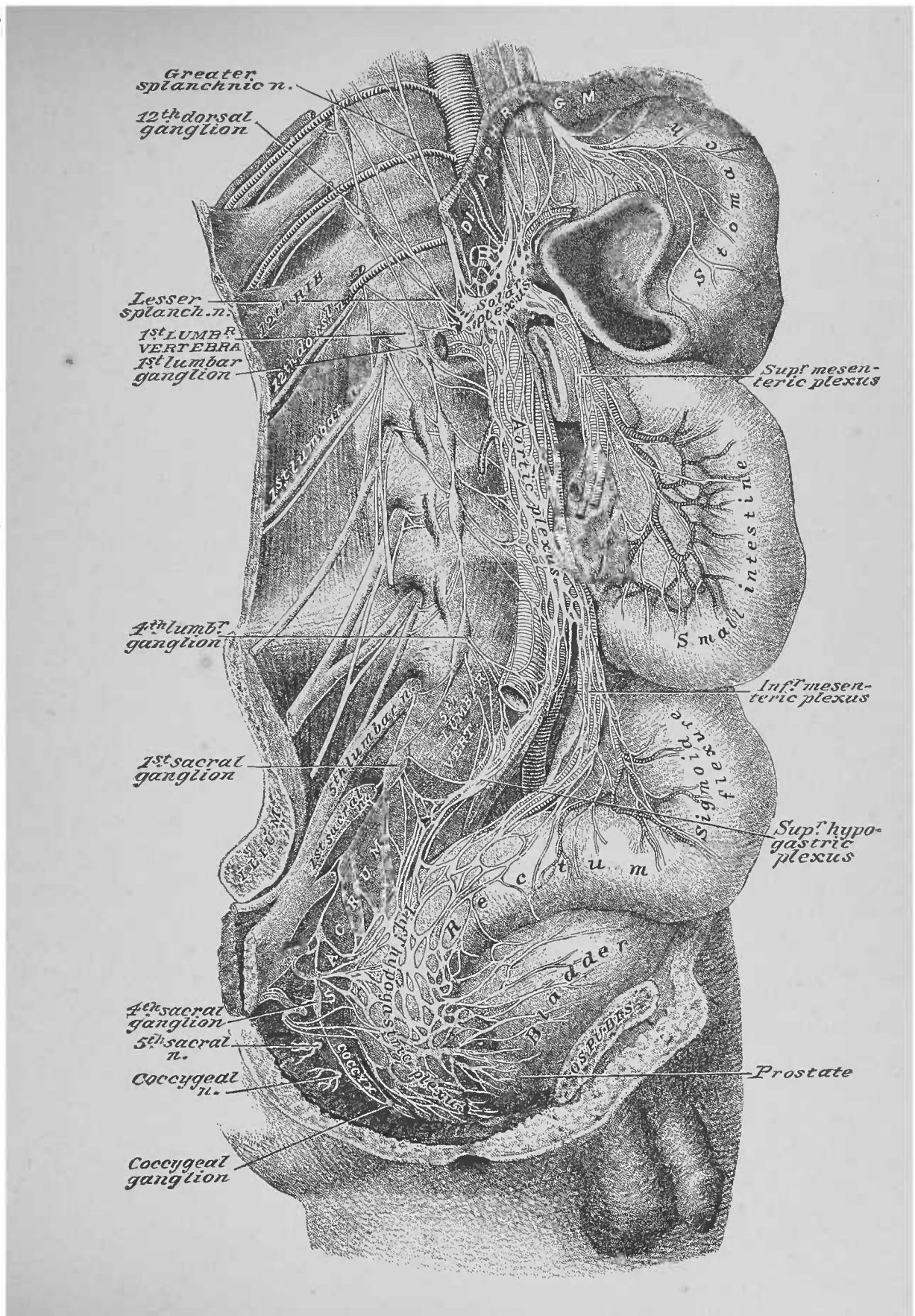


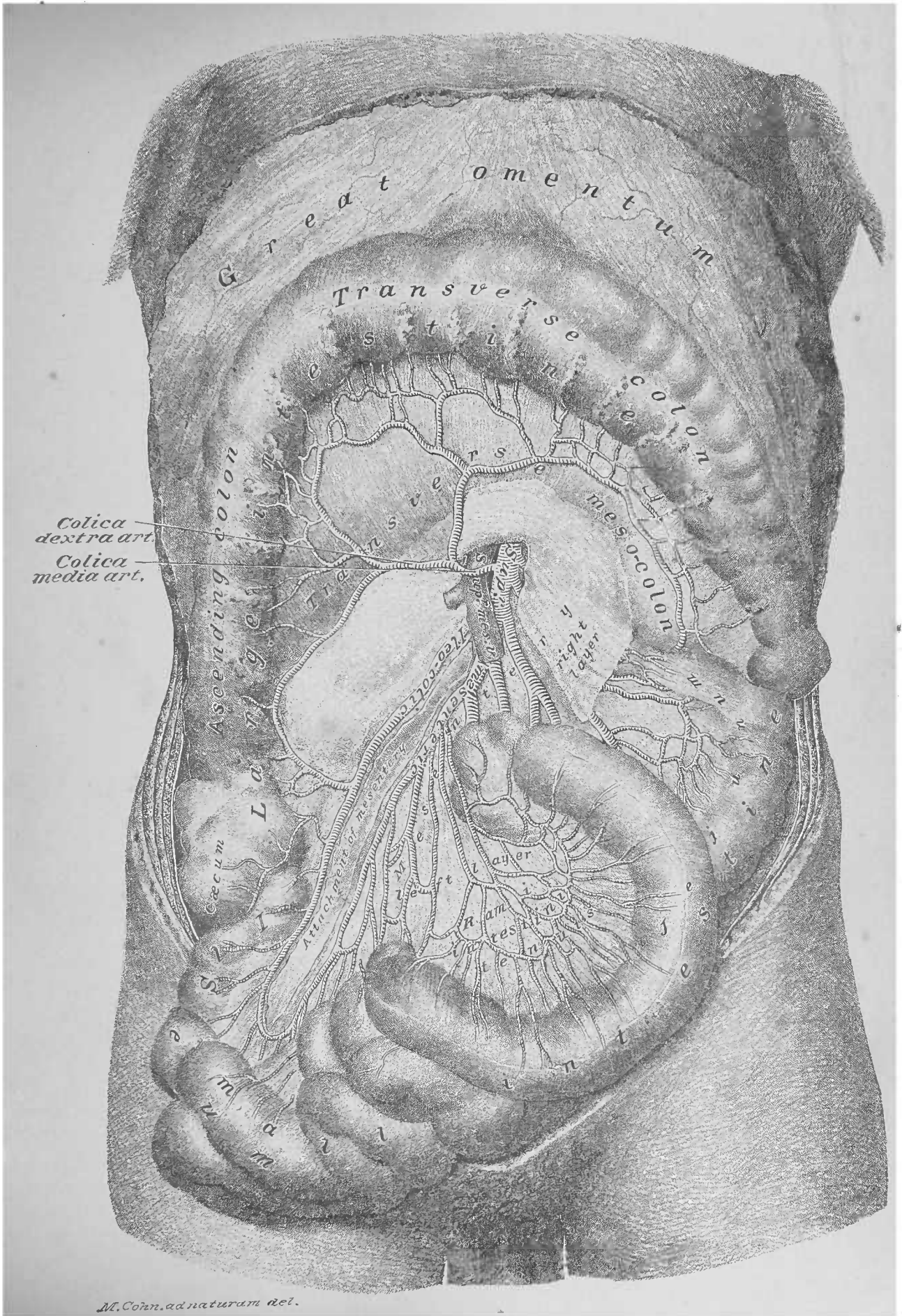
M. Cohn, aâ naturam del.

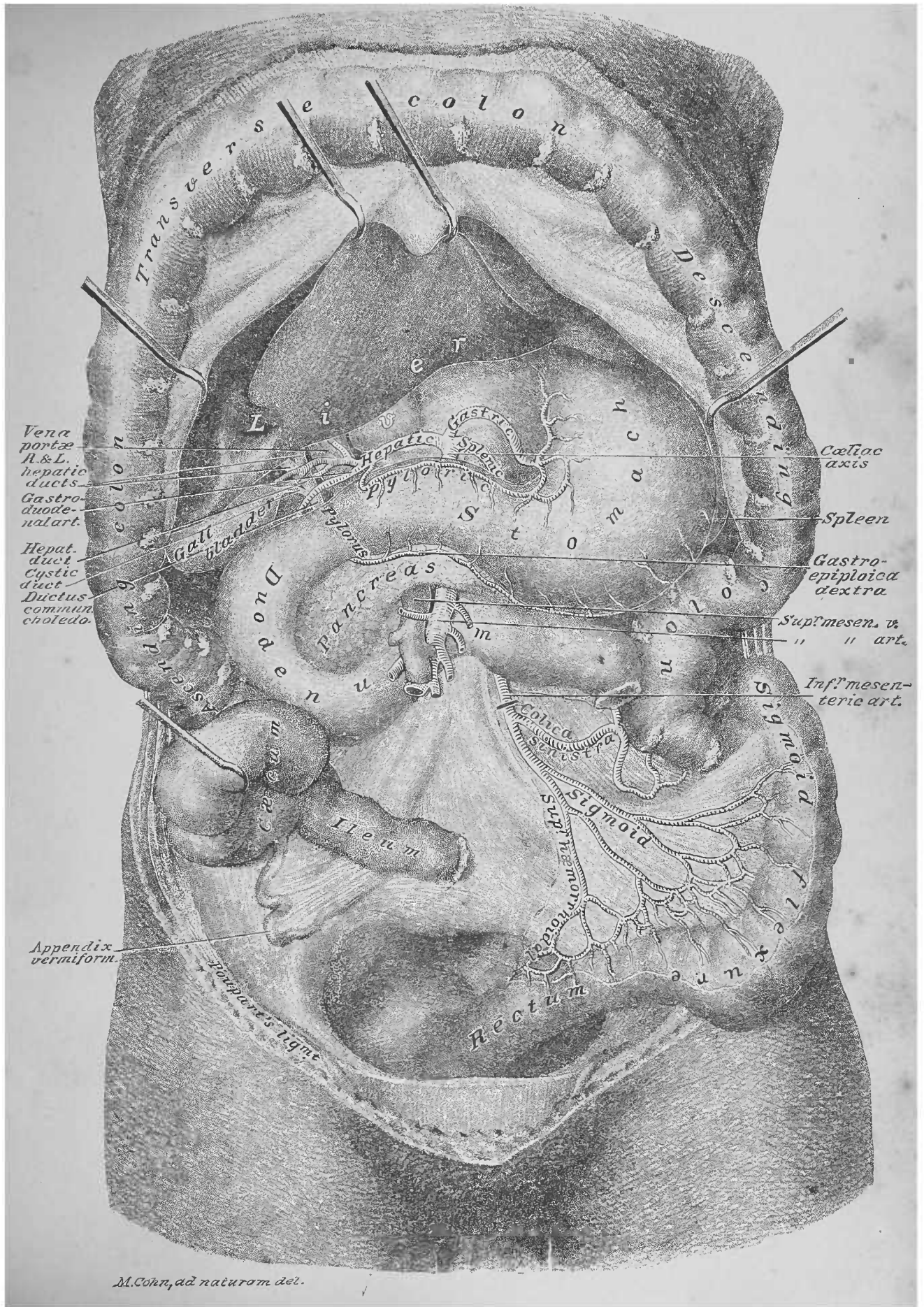


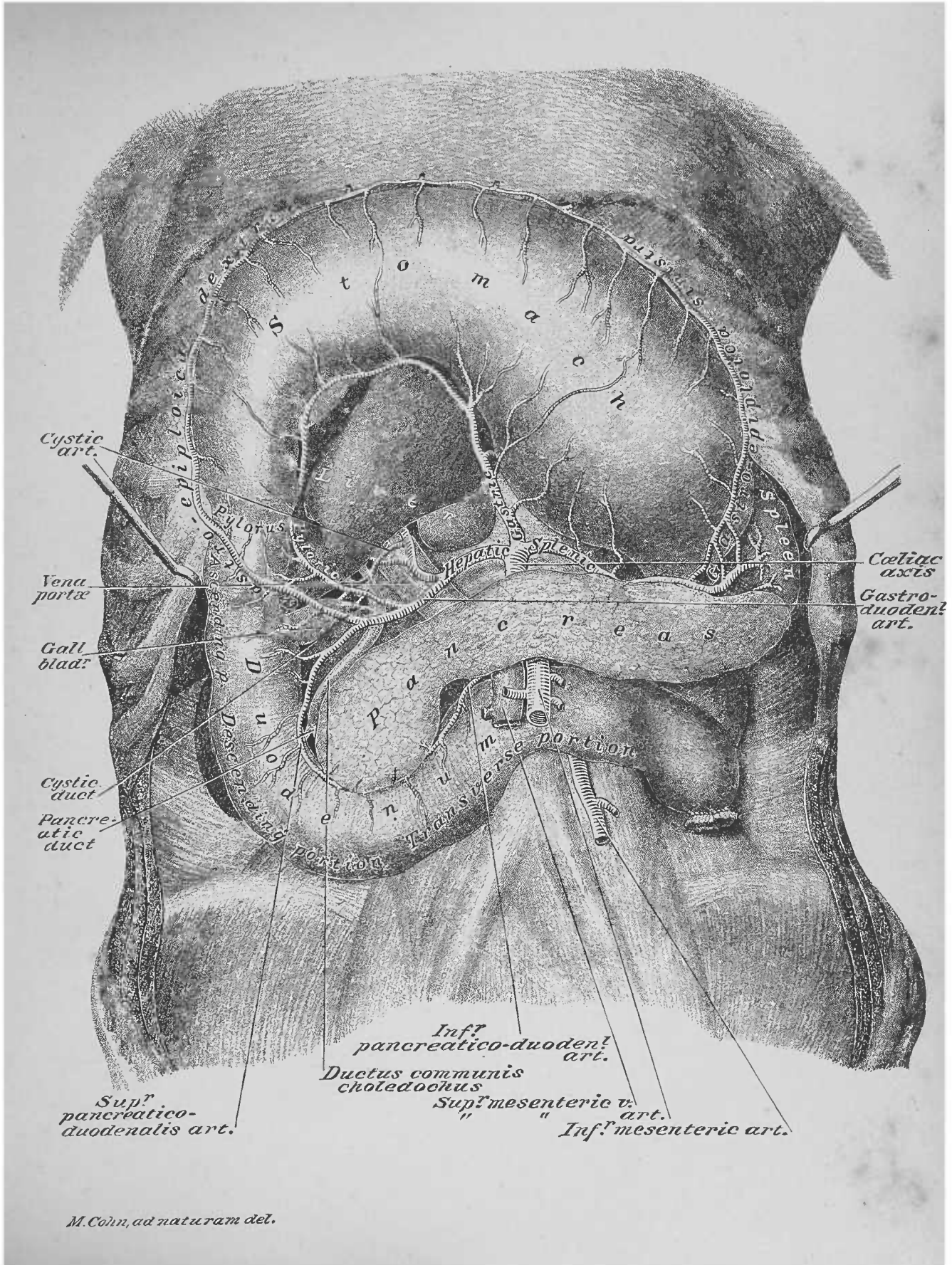


M. Cohnz, ad naturam del.









M. Cohn, ad naturam del.

FIG. 1

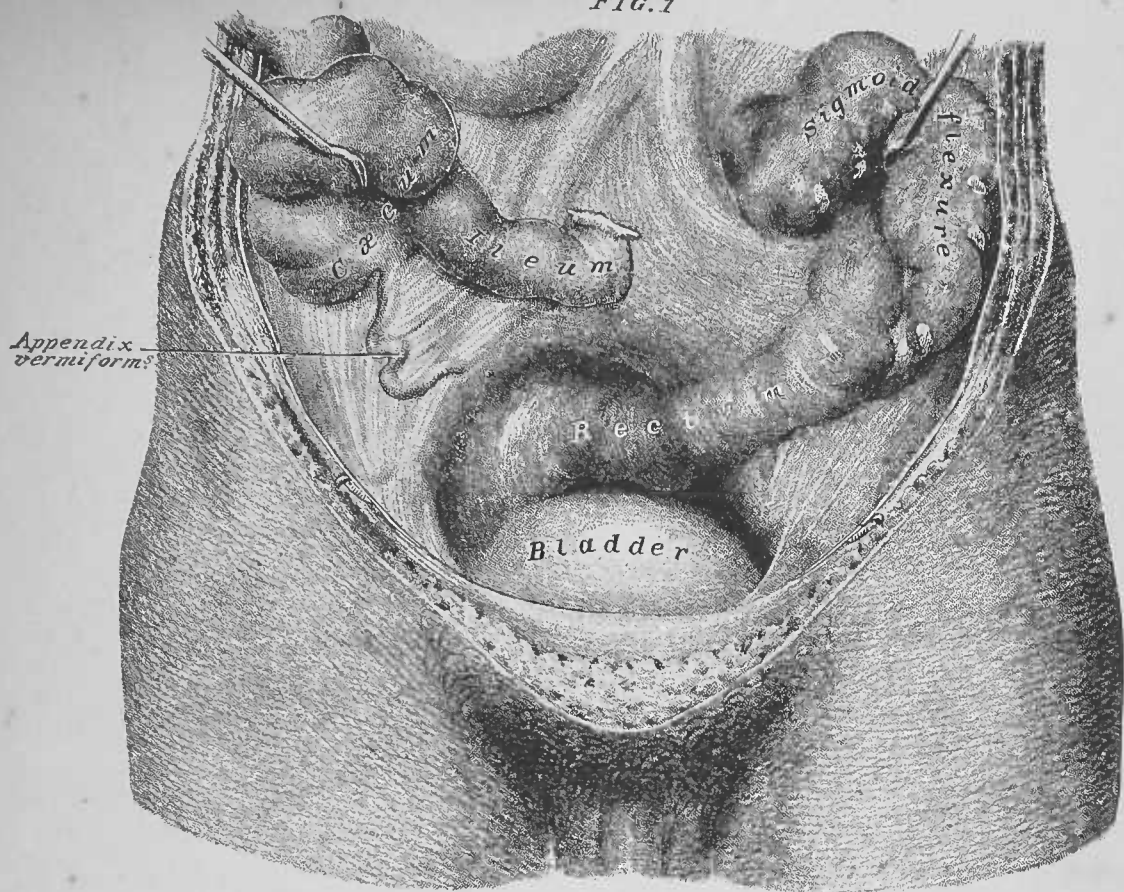
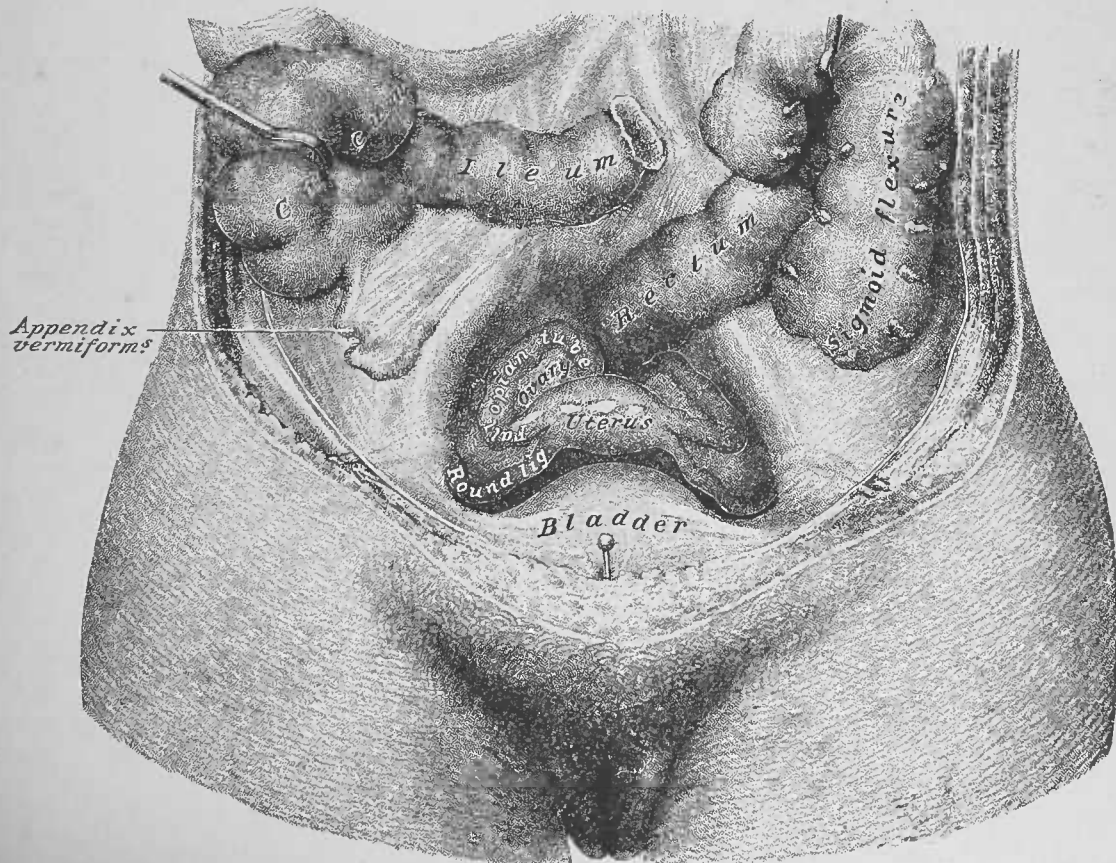


FIG. 2



H. Cohn, ad naturam del.

FIFTH DISSECTION.

ABDOMINAL AND PELVIC INTERIORS.

DISSECTION.—Take up the dissection of the abdominal cavity, as left after the completion of the fourth dissection. Section the vena cava, the ureters and the spermatic vessels (Plate 38); reflect the inferior portions of the two latter into the pelvic cavity. Remove the testes from the scrotum and place them in the pelvis. Spread the thighs and take out the sutures from the perineal flaps. Cut the penis free from the pubic arch, so that it may come away in continuity with the bladder. Trace the ureters and the vasa deferentia or the ureters, the ovarian vessels, and the round ligaments of the uterus as they pass, exterior to the peritoneum, to the interior of the lateral walls of the pelvic cavity; reflect the same, from the respective sides, upon the pelvic viscera, toward the median line. Pass the fingers external to the reflected ducts and vessels, between the peritoneum and the fascia lining the pelvic walls, and free the pelvic organs; use the curved scissors to cut the vesical, middle hemorrhoidal and uterine vessels. Remove the viscera—bladder, rectum (male), or bladder, rectum, uterus, vagina (female), with attached vessels, etc.—through the inferior outlet of the pelvis. Empty and wash out the rectum and bladder, after which the pelvic viscera, *en masse*, may be placed in preservative fluid for subsequent dissection. Bring together the thighs and clean the common, the external and the internal iliac arteries and veins.

1. Common Iliac Arteries, Plates 38 and 39. — These trunks pass from their origin, at the bifurcation of the abdominal aorta upon the body of the fourth lumbar vertebra, to the sacro-iliac articulations. The right lies against the internal surface of the vena cava and the right common iliac vein; the left is between the left psoas magnus muscle, externally, and the left common iliac vein, internally. At the sacro-iliac articulation of a side the artery divides into the external and the internal iliac arteries.

2. External Iliac Artery.—This artery continues, from its origin, along the internal surface of the psoas magnus muscle to pass beneath Poupart's ligament into the thigh, where it be-

comes the femoral artery. Before passing under the ligament it gives off the deep epigastric artery, previously described (page 54); also, the deep circumflex iliac artery, which passes, externally, superior to and parallel with Poupart's ligament, to perforate the transversalis abdominis muscle and reach the lateral area of the abdominal parietes, where it was before recognized (page 50).

3. Internal Iliac Artery.—This vessel, given off by the bifurcation of the common iliac artery, passes, inferiorly, along the posterior portion of the lateral interior of the pelvic cavity. It divides into an anterior and a posterior trunk: the anterior gives off the obturator, the superior vesical, the uterine and the inferior vesical branches, and then divides into the internal pudic and the sciatic arteries; the posterior gives off the ilio-lumbar and the lateral sacral branches and continues as the gluteal artery.

4. External Iliac Vein.—The femoral vein enters the pelvic cavity, subjacent to Poupart's ligament; the external iliac vein continues it, parallel with and inferior to its artery, to where it meets the internal iliac vein.

5. Internal Iliac Vein.—This vessel runs external to its artery, receiving the comites veins of the branches given off from the anterior and posterior trunks of the internal iliac artery.

6. Common Iliac Veins.—These are formed by the junction of the right and left external and internal iliac veins, opposite the sacro-iliac articulations, inferior to and included in the forks of the bifurcations of the common iliac arteries. They converge to form the vena cava inferior, posterior to the commencement of the right common iliac artery. The left vein runs internal to its artery, while the right lies posterior to its arterial trunk.

DISSECTION.—Follow the branches of the anterior trunk of the internal iliac artery; cut away their venæ comites.

7. Obturator Artery, Plates 39 and 46.—This artery (vena comes) has a direct course, from its origin, along the interior

surface of the obturator internus muscle, to where it leaves the pelvic cavity by its foramen in the obturator membrane, to distribute in the thigh.

8. Superior Vesical Artery, Plate 39.—This artery (vena comes) distributes as its name implies. There is continued from it the obliterated hypogastric artery (page 55).

9. Uterine Artery.—This vessel (venæ comites) enters between the folds of the broad ligament of the uterus, passing to the side of the neck of that organ, whence it is distributed to the uterus and vagina, as will be shown hereafter.

10. Inferior Vesical Artery.—In the male, this artery (venæ comites) distributes to the bladder, rectum, etc.; in the female it becomes the *vaginal artery*, which sends branches to the vagina, bladder and rectum.

11. Pudic Artery.—This artery (venæ comites), which takes its origin from the anterior trunk of the internal iliac artery, leaves the pelvic cavity by the great sacro-sciatic foramen, posterior to the spine of the ischium, to reach the exterior surface of the same. Before leaving the pelvic cavity it gives off the middle hemorrhoidal artery. Its return to the pelvic cavity anterior to the spine of the ischium, and its course in the external wall of the ischio-rectal fossa, etc., was seen in the dissection of the perineum (Male Perineum, page 18).

12. Sciatic Artery.—This artery (venæ comites), arising as before described (page 74), lies upon the interior surface of the pyriformis muscle; it passes between the second and third sacral nerves, to leave the pelvic cavity by the great sacro-sciatic foramen, inferior to the pyriformis muscle.

DISSECTION.—Section the common, the external and the internal iliac arteries; also, the pudic, sciatic and obturator arteries (Plate 39); remove the portions of the arteries between the section lines. Cut the common and the external iliac veins (Plate 39); remove the common, external and internal iliac veins. In removing the portions of these vessels clear away the subjacent areolar tissue with care; disturb as little as possible the bifurcation of the common iliac artery. Clean the branches of the posterior trunk of the internal iliac artery; also, the sacra media artery.

13. Sacra Media Artery, Plates 38, 39, 40, and 41.—This artery (*venæ comites*) continues the trunk of the abdominal aorta into the pelvic cavity. It passes to the middle of the anterior surface of the sacrum from beneath the left common iliac vein, continuing, inferiorly, to the coccyx; it gives off lateral branches opposite each segment of the sacrum, which anastomose with branches of the lateral sacral arteries.

14. Lateral Sacral Artery, Plates 39 and 40.—This artery (*venæ comites*) springs from the posterior trunk of the internal iliac, courses, internally, to the external half of the anterior surface of the second segment of the sacrum, whence it continues, inferiorly, to the coccyx. It affords branches to contiguous muscles; others, which enter the anterior sacral foramina; and still others, which anastomose with the *sacra media*.

15. Ilio-Lumbar Artery, Plates 38, 39, 40, and 41.—This artery (*venæ comites*), from the posterior trunk of the internal iliac, passes, superiorly and externally, posterior to the *psoas magnus* muscle, to distribute upon the interior of the *iliacus internus* and *quadratus lumborum* muscles, and in the lateral planes of the abdominal parietes. Its branches anastomose with the inferior lumbar branches of the abdominal aorta, and with the deep circumflex iliac branch of the external iliac.

16. Gluteal Artery, Plates 40 and 46.—This artery (*vena comes*) is the continuation of the posterior trunk of the internal iliac. It hooks beneath the lumbo-sacral cord of the sacral plexus, to leave the pelvic cavity by the great sacro-sciatic foramen above the *pyriformis* muscle.

DISSECTION.—Section the gluteal, lateral sacral and ilio-lumbar arteries (Plate 40). Remove the bifurcation of the common iliac artery. Clean the chain of lumbar sympathetic ganglia and their branches, between the *psoas magnus* muscle and the bodies of the lumbar vertebræ; also the exposed portions of the lumbar arteries.

17. Lumbar Sympathetic Ganglia, etc., Plates 33, 38 and 41.—These four ganglia are lodged as stated in the preceding dissection clause. They have branches of communication with each other; inferiorly, the chain is continued, to the first sacral ganglion of the pelvis; superiorly, the communicating branch from the first ganglion continues to the twelfth dorsal ganglion

of the thorax. They will also be found to have branches of communication with the contiguous anterior branches of the spinal nerves (lumbar). Their distributing branches contribute to the aortic and superior hypogastric plexuses.

18. Lumbar Arteries.—These are four pairs of arteries from the posterior surface of the abdominal aorta; they pass, laterally, over the sides of the bodies of the lumbar vertebræ into the posterior parietes of the abdominal cavity. Their veins commence, on either side, the azygos veins, major right and minor left.

DISSECTION.—Remove fascia and adventitious tissue from the surfaces of the psoas magnus, psoas parvus, quadratus lumborum, posterior portions of the transversalis abdominis, and the iliacus internus muscles, preserving the nerves ramifying upon the interior of the same (Plate 41).

19. Twelfth Dorsal Intercostal Nerve, Plates 33 and 41.—A portion of this nerve runs inferior to the twelfth rib, upon the interior surface of the transversalis abdominis muscle.

DISSECTION.—Section, on one side, the psoas magnus and parvus muscles (Plate 44); reflect the portions of the muscles, superiorly and inferiorly, dissecting out from the muscles the nerves of the lumbar plexus; allow the latter to remain *in situ* (Plate 41).

20. Lumbar Plexus.—This plexus is formed by the anterior branches of the four superior lumbar nerves. It is lodged in the substance of the psoas magnus muscle and upon the interior of the quadratus lumborum and the iliacus internus muscles.

21. Ilio-Hypogastric and Ilio-Inguinal Nerves, Plates 33, 38, and 41.—These nerves originate from the first lumbar nerve; they cross the anterior surface of the quadratus lumborum muscle, continuing upon the interior of the transversalis abdominis muscle, superior to and parallel with the crest of the ilium; they perforate the latter muscle, and pass, as before described, into the planes of the antero-lateral areas of the abdominal parietes (page 49, and Plates 22, 25, 26, and 27).

22. External Cutaneous Nerve, Plates 38, 39, 40, and 41.—This nerve, branch of the second lumbar, passes, inferiorly, to the interior of the posterior extremity of the crest of the ilium;

it then curves, externally and anteriorly, upon the interior of the superior portion of the iliacus internus muscle, running inferiorly to, and parallel with, the crest of the ilium, to pass into the thigh under Poupart's ligament, near the anterior superior spinous process of the ilium.

23. Genito-Crural Nerve, Plates 38 and 41.—This is a branch from the second lumbar, which passes, inferiorly, through the substance of the psoas magnus muscle; it emerges at the internal and rises to the superior surface of the muscle, and continues to Poupart's ligament. The trunk of the nerve bifurcates into a genital and a crural branch; the genital branch joins the spermatic cord at the iliac or internal abdominal ring to distribute to the cremaster muscle; the crural branch leaves the pelvic cavity beneath Poupart's ligament.

24. Anterior Crural Nerve, Plates 38, 39, 40, and 41.—This nerve is contributed to by the second, third and fourth lumbar nerves; the three branches form a single trunk, inferior to the posterior portion of the crest of the ilium, lying between the iliacus internus and the psoas magnus muscles; it appears upon the iliacus internus, superior to Poupart's ligament, along the external border of the psoas magnus; it continues, inferiorly, passing beneath Poupart's ligament into the thigh.

25. Obturator Nerve, Plates 39, 40, 41, and 46.—This branch, given off from the third and fourth lumbar nerves, runs inferiorly and posteriorly to the psoas magnus muscle and the external iliac vein. It appears, inferiorly to the external iliac vein, upon the interior of the obturator internus muscle, where it courses superiorly to, and parallel with, the obturator artery; it leaves the pelvic cavity by the same foramen as the artery (see page 74).

26. Accessory Obturator Nerve.—This is given off (when present) from the fourth lumbar nerve; it accompanies the obturator nerve, but leaves the pelvis under Poupart's ligament, over the horizontal ramus of the os pubis.

DISSECTION.—Trace the fifth lumbar nerve and the branch it receives from the fourth lumbar; also, the four superior sacral nerves, from the anterior sacral foramina to the great sacro-sciatic foramen. Determine the sacral

ganglia of the sympathetic, the fifth sacral nerve, the coccygeal or sixth sacral nerve and the coccygeal ganglion of the sympathetic, or the *ganglion impar*.

27. Sacral Plexus, Plates 33, 39, 40, and 41.—The anterior branch of the fifth lumbar nerve and a branch from the fourth (lumbo-sacral cord) form the superior contribution to the sacral plexus; the plexus is completed by the anterior branches of the first, second, third and part of the fourth sacral nerves. The above trunks converge to two nerves, the great and the small sciatic, which leave the pelvic cavity by the great sarco-sciatic foramen, inferior to the pyriformis muscle. The plexus also affords: interior branches to the pyriformis, the levator ani, and the obturator internus muscles; and exterior branches to the gemellus superior, the gemellus inferior, and the quadratus femoris muscles.

28. Anterior Branches of the Fifth Sacral and the Coccygeal Nerves.—These two nerves distribute to the coccygeus muscle and the skin of the coccygeal region.

29. Sacral Ganglia and Coccygeal Ganglion of the Sympathetic.—These ganglia continue the ganglioric chain of the sympathetic, from the lumbar region into the pelvis; they lie upon the anterior surface of the sacrum, internal to the emergence of the anterior branches of the sacral spinal nerves at the sacral foramina. They are united by branches, and also communicate with the sacral nerves. The fourth sacral ganglion sends a branch to the single coccygeal ganglion (*ganglion impar*), upon the anterior face of the coccyx.

DISSECTION.—Section the aorta, the vena cava, the ureters, the spermatic or the ovarian vessels and the suprarenal branches from the phrenic arteries (Plate 38). Note the arrow placed upon the right crus of the diaphragm, inferior to the renal vein (Plate 38); it points to the receptaculum chyli upon the body of the second lumbar vertebra, posterior to the aorta (Plate 41). Raise, *en masse*, from the interior of the abdominal wall, the suprarenal capsules, the kidneys, the superior portions of the ureters and the spermatic vessels, the renal vessels and the portions of the aorta and the vena cava. In raising the piece of the aorta be careful to hug its posterior surface, so as not to injure subjacent parts. These viscera, attached vessels, etc., should be placed in preservative fluid. In the area exposed by the removal of the portion of the aorta (Plate 41), find a small vein to the right of the median line—the commencement of the vena azygos major—and the receptaculum chyli along

the median line; the latter has minute vessels—lymphatics—converging to it. Note a number of lymphatic glands contiguous to the receptaculum chyli; trace some of the lymphatic vessels from the glands to the receptaculum chyli.

30. Receptaculum Chyli, Plate 41.—This, the commencement of the left lymphatic or thoracic duct of the lymphatic system, lies upon the anterior surface of the body of the second lumbar vertebra, posterior to the abdominal aorta; it is about the size of a small quill, and receives lymphatic vessels from the surrounding lymphatic glands; it continues, superiorly, upon the first lumbar vertebra, and passes into the thorax through the aortic opening of the diaphragm.

DISSECTION.—Remove the peritoneum from the abdominal surface of the diaphragm; trace, in so doing, the ramifications of the phrenic arteries (Plate 41), and note the points of perforation of the phrenic nerves and their distribution. Determine the aortic, the caval and the œsophageal openings in the diaphragm; clean the crura and the ligamenta arcuata externa and interna portions of the diaphragm (Plate 43).

31. Phrenic Arteries, Plates 38 and 41.—These branches from the abdominal aorta (page 70), distribute, right and left, to the inferior surface of the diaphragm. Each artery gives a branch to the suprarenal capsule of its side.

32. Phrenic Nerves.—These nerves perforate the diaphragm from the thorax, to distribute to the inferior surface of the muscle.

33. Cartilage Areas of the Abdominal Interior, Fig. 2, Plate 21.—The cartilage surfaces presenting areas for the attachments of the diaphragm are: the interior surfaces of the ensiform cartilage of the sternum and of the cartilages of the six inferior ribs.

34. Bone Areas of the Abdominal and Pelvic Interiors, Plate 42.—The twelfth dorsal vertebra, the twelfth rib, the lumbar vertebræ and the ilial portion of the os innominatum afford attachments to muscles, that contribute to the superior and postero-lateral walls of the abdominal cavity.

35. Diaphragm, Fig. 2, Plate 21, and Plates 38, 41, 42, 43, and 44.—This muscle forms the septum between the abdominal and thoracic cavities. The portions of the muscle are: a ten-

dinous centre, a circumferential muscle portion and two crura. It is attached as follows: to the interiors of the ensiform cartilage of the sternum and the cartilages of the six inferior ribs, right and left; to the ligamenta arcuata externa—arches of fibrous tissue, that bridge from the cartilages of the twelfth rib to the transverse processes of the first lumbar vertebra; to the ligamenta arcuata interna—internal fibrous arches from the transverse processes of the first lumbar vertebra to the lateral surfaces of the body of the same vertebra; to the anterior surfaces of the bodies of the four superior lumbar vertebræ, by the crura of the muscle. From the abdomen, the fibres are seen to converge from their circumferential attachments to a fibrous portion—the tendinous centre of the diaphragm. Before the removal of the heart from the thorax, the diaphragm maintains the shape of an antero-posterior half-arch over the abdomen (the arch deficient anteriorly); the arch is maintained by the parietal layer of the pericardium, being attached to the superior surface of the tendinous centre inferiorly and to the fixed large vessels, projected from the base of the heart, superiorly; by it the centre of the diaphragm is held up and rendered almost immovable, during inspiration and expiration, respectively. The muscle presents three large openings of communication with the thorax; the aortic, the œsophageal and the caval. The aortic opening is located opposite the twelfth dorsal vertebra, between the crura; it gives transit to the aorta, the left lymphatic or thoracic duct and the right vena azygos. The œsophageal opening is located a little to the left and anterior to the aortic; it allows the œsophagus and the right and left pneumogastric nerves to pass from the thorax into the abdomen. The caval opening is through the tendinous centre of the diaphragm, to the right of, and anterior to the vertebral column; it allows the vena cava inferior to pass from the abdomen into the thorax. The right and left crus are perforated by the sympathetic nerve-trunks and the splanchnic nerves of the sides respectively; the left crus gives transit also to the vena azygos minor vein.

36. Psoas Parvus Muscle, Plate 44, and Plates 39 to 43 inclusive.—This small muscle, when present, is attached to the lateral surface of the body of the twelfth dorsal vertebra (Plate 42); it emerges from beneath the ligamentum arcuatum

internum (Plate 43) ; it continues, inferiorly, upon the interior face of the psoas magnus muscle, and is attached, at the brim of the pelvis, to the ilio-pectineal eminence.

37. Psoas Magnus Muscle, Plates 38 to 44, inclusive.—This muscle is attached, superiorly, to the lateral surfaces of the last dorsal and the lumbar intervertebral discs (Plate 44) ; it emerges inferiorly to the ligamentum arcuatum internum, runs along the brim of the pelvis, and blends with the iliacus internus ; the two leave the abdomen inferiorly to Poupart's ligament.

38. Quadratus Lumborum Muscle, Plates 38, 41, 42, 43 and 44.—This muscle is attached to the inferior border of the twelfth rib, the transverse processes of the lumbar vertebræ, and the posterior third of the interior lip of the crest of the ilium. It emerges from beneath the ligamentum arcuatum externum of the diaphragm (Plate 43). It is located in the plane, posteriorly to the psoas magnus muscle ; it continues, posteriorly, the muscle plane of the transversalis abdominis muscle, of the antero-lateral areas of the abdominal parietes.

39. Iliacus Internus Muscle, Plates 38 to 42, inclusive ; and Plates 44, 45, and 46.—This muscle is attached to the interior of the ilium, and leaves the pelvic cavity with the psoas magnus muscle, inferiorly to Poupart's ligament.

40. Pelvic Cavity, Plates 42, 45, and 46.—This cavity is enclosed : posteriorly, by the bones, sacrum and coccyx, and by the ligaments, great and small sacro-sciatic ; laterally, by the ischial and ilial portions of the os innominatum and the sacro-sciatic ligaments ; anteriorly, by the ossa pubis, the symphysis pubis, the ischia, and the obturator membranes ; superiorly, it presents an inlet, which makes the cavity continuous with the abdominal ; inferiorly, it is closed by the tissue-planes of the perineum (Male or Female Perineum).

41. Bone Areas of the Pelvic Cavity, Plates 42 and 45.—The interior surfaces of all the bones of the pelvic cavity afford attachments to muscles.

42. Piriformis Muscle, Plates 39, 40, 42, and 46 ; Fig. 1, Plate 45.—This muscle has its interior pelvic attachment to

the anterior surface of the lateral mass of the sacrum, external to the anterior sacral foramina (Plates 42 and 45). It leaves the cavity of the pelvis, at a right angle to its attachment, by the great sacro-sciatic foramen; it goes through the foramen, accompanied by vessels and nerves: superior to it are the gluteal vessels and nerve; inferior to it are the sciatic and pudic vessels and nerves.

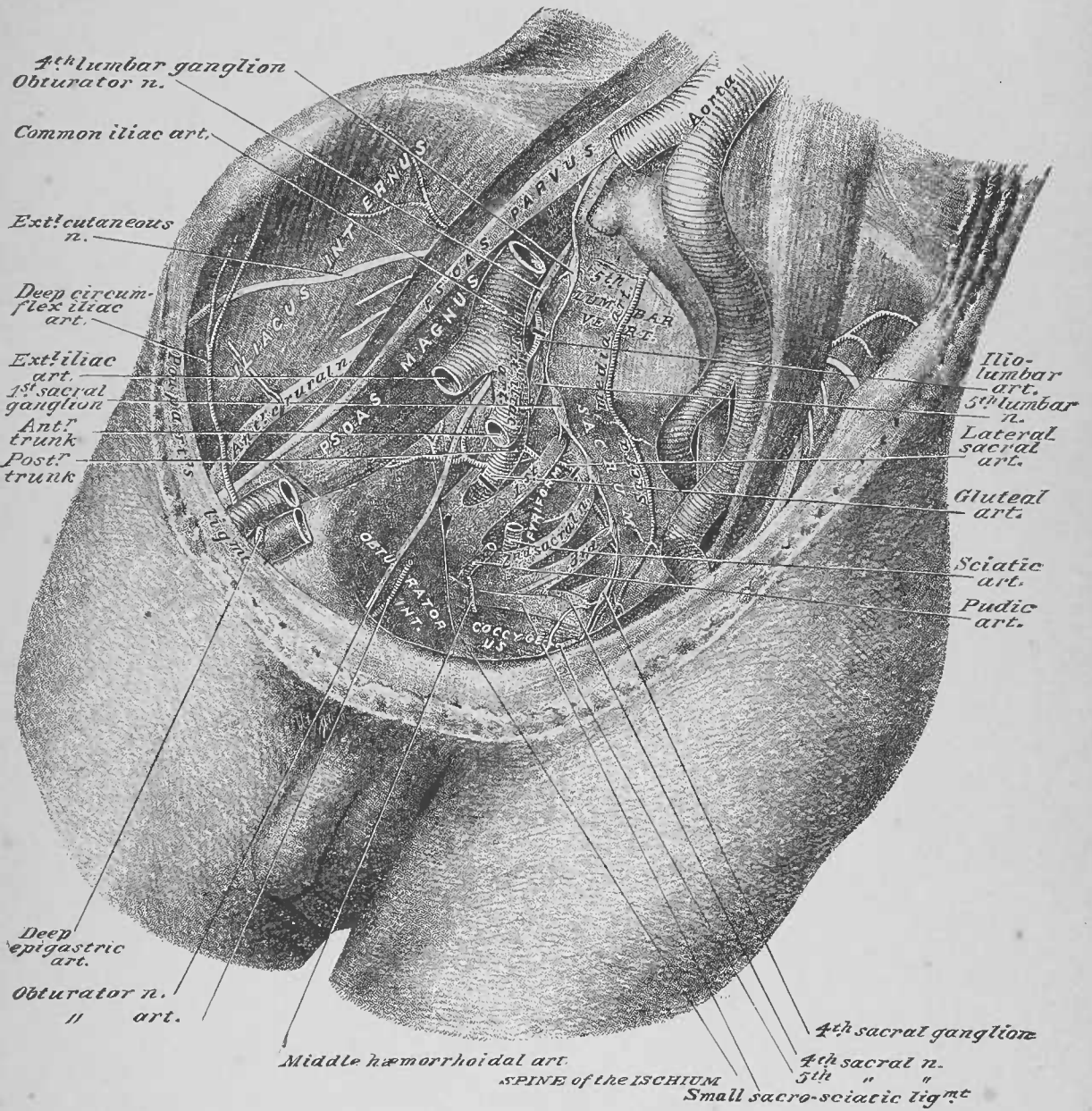
43. Coccygeus Muscle, Plates 39, 40, and 46; Fig. 1, Plate 45.—This muscle is attached to the interior of the spine of the ischium, externally, and the lateral portion of the interior of the coccyx, internally; it crosses upon the interior of the small sacro-sciatic ligament. It is perforated by the fifth sacral and the coccygeal nerves, on their way to the skin of the coccygeal region.

44. Levator Ani et Prostatae, or Levator Ani et Vaginae Muscle, Plates 45 and 46.—This muscle was described and partially dissected in the male and female perinei (pages 24 and 39; Plates 9 and 18). The dissected muscles and fasciæ of the pelvic interior, as shown in Plate 46, is intended to make clear the attachments and fascial relations of these muscles (according to sex). (The dissector is not to reproduce this sectioned pelvis.) From the spine of the ischium to the interior of the os pubis, the line of the splitting of the pelvic fascia, into the recto-vesical and obturator fasciæ, bridges the lateral interior of the pelvis—the *pelvic fascia line*. The levator muscle is attached: to the spine of the ischium, posteriorly; the interior of the os pubis, anteriorly; and along the obturator fascia between these points, inferior to the splitting of the pelvic fascia. From these attachments it passes inferiorly—as the levator ani et prostatae (male) or the levator ani et vaginae (female)—to sling the pelvic viscera, by the meeting of the right and the left muscle, along the median line of, and at the outlets of, the pelvic viscera at the perineum (Plates 9 and 18). From the obturator fascia, inferior to the line of attachment of the levator muscles, the levator fascia—posterior layer of the triangular ligament and the anal fascia—is projected to the median line of the pelvic outlet, exterior to the compound levator muscle (Male Perineum, page 22 and Fig. 3, Plate 8; Female Perineum, page 39, and Plate 17).

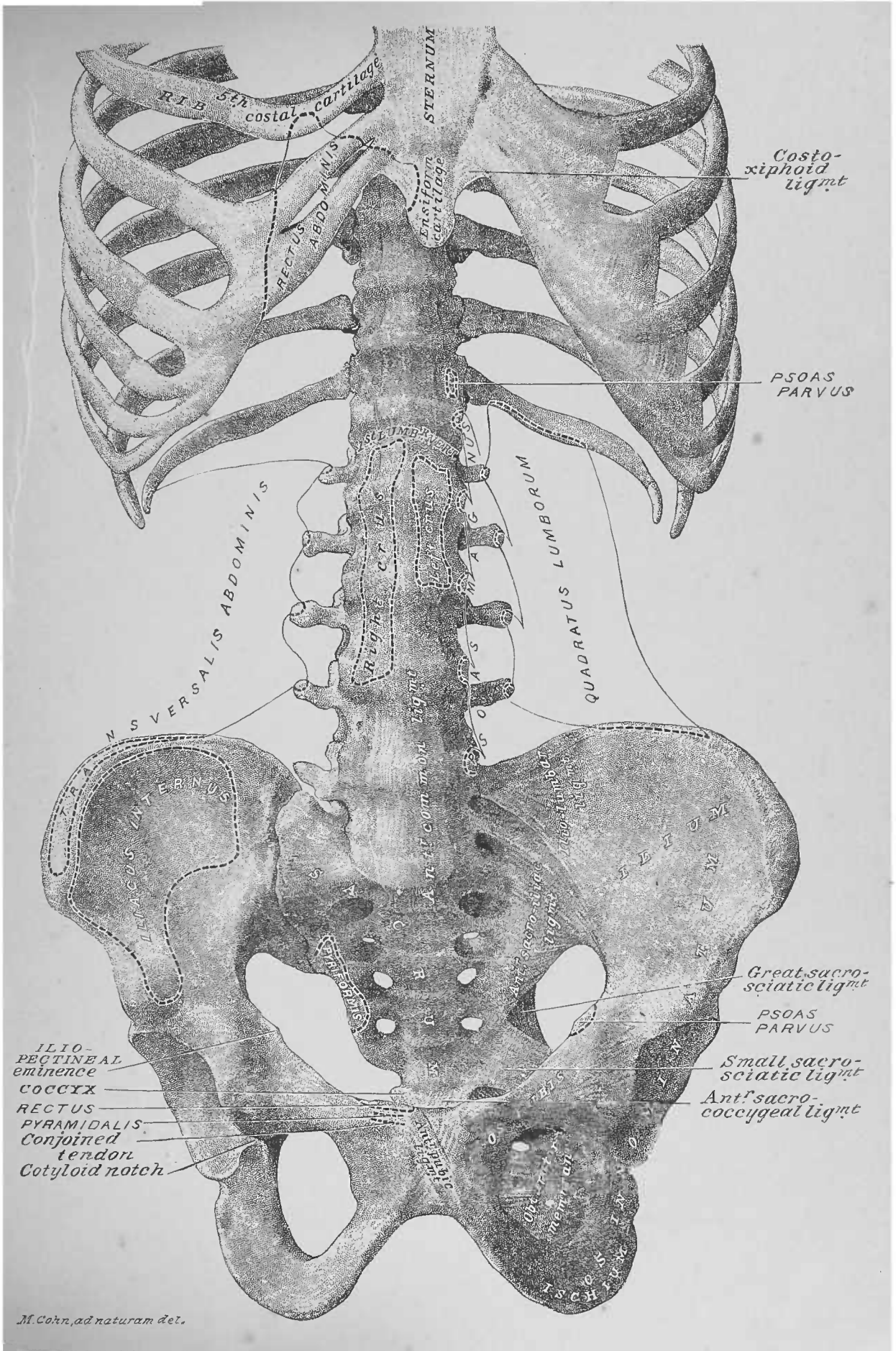
45. Obturator Internus Muscle, Plates 39, 40, 45, and 46.—The inferior portion of this muscle was referred to in the dissection of the male perineum (page 17). It is attached to the interior surface of the obturator membrane and the bony circumference surrounding the same (Fig. 1, Plate 45). From this attachment its tendon leaves the pelvic cavity by the small sacro-sciatic foramen, being projected therefrom into the gluteal region (Plate 100).

46. Ligaments of the Abdominal and Pelvic Interiors, Plates 42 and 45.—These ligaments present as follows: upon the anterior surfaces of the bodies of the lumbar vertebræ, the anterior common ligament of the spinal column; from the transverse process of the fifth lumbar vertebra to the posterior superior spinous process of the ilium, the ilio-lumbar ligament; from the anterior surface of the lateral portion of the sacrum to the interior of the ilium, the anterior sacro-iliac ligament; from the spine of the ischium to the sacrum and coccyx, the small sacro-sciatic ligament; from the sacrum to the body of the ischium, the great sacro-sciatic ligament; from the anterior surface of the inferior segment of the sacrum to the anterior of the coccyx, the anterior sacro-coccygeal ligament; at the symphysis pûbis the posterior, superior and inferior pubic ligaments.

DISSECTION.—If the dissector has the lower extremity assigned to him with the abdomen, he should continue his work by dissecting the anterior surface of the thigh; if he has the trunk region—abdomen, pelvis and thorax—he should take up the dissection of the anterior parietes of the thorax. The demonstration of the abdominal and pelvic viscera will now be given, as they naturally complete the abdomen and pelvis; but the dissector should leave them till after he has finished the dissection of the lower extremity or thorax, according to the assignment of the subject.



M. Cohn, ad naturam del.



M. Cohn, ad naturam del.

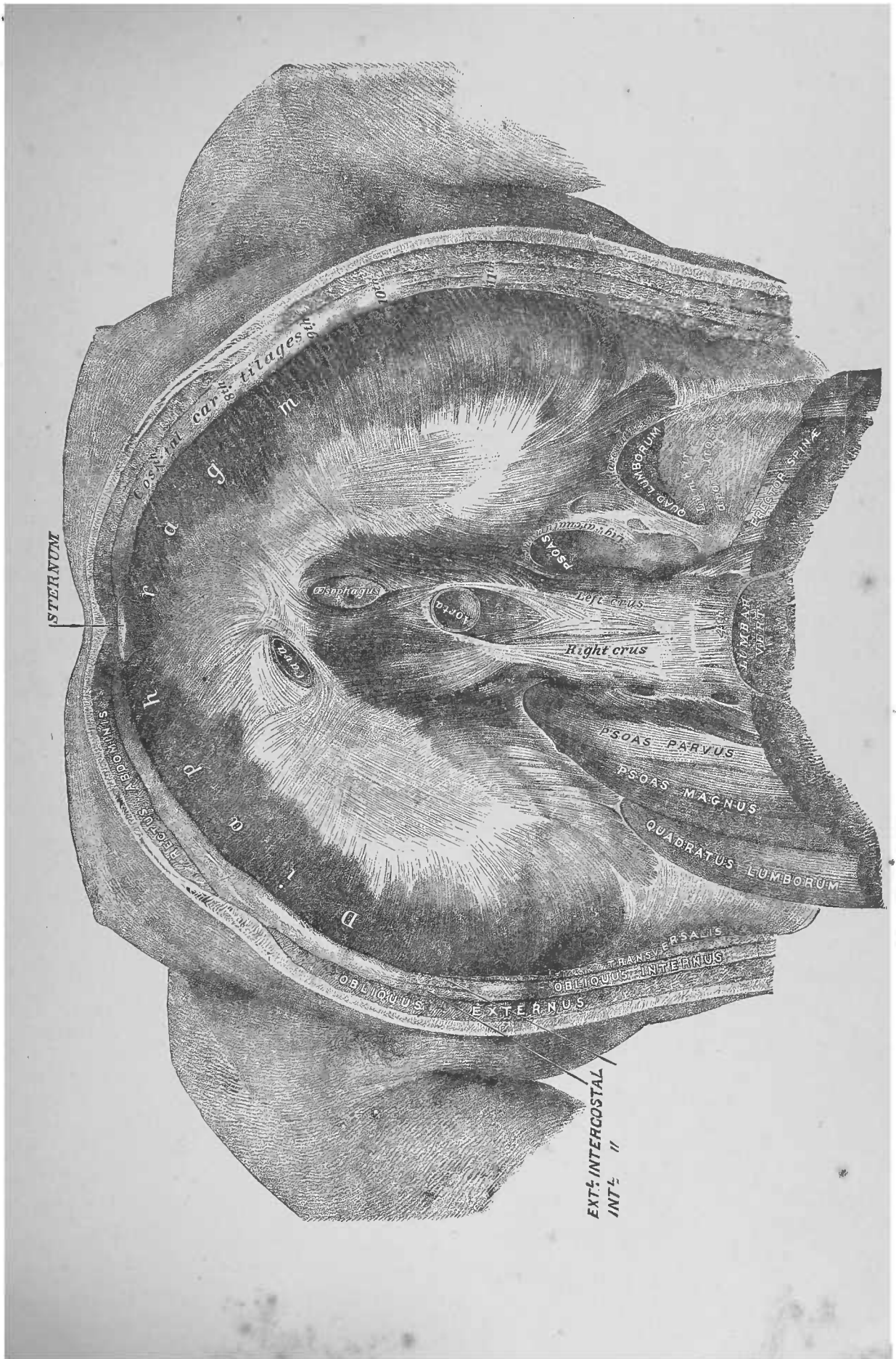


FIG. 1

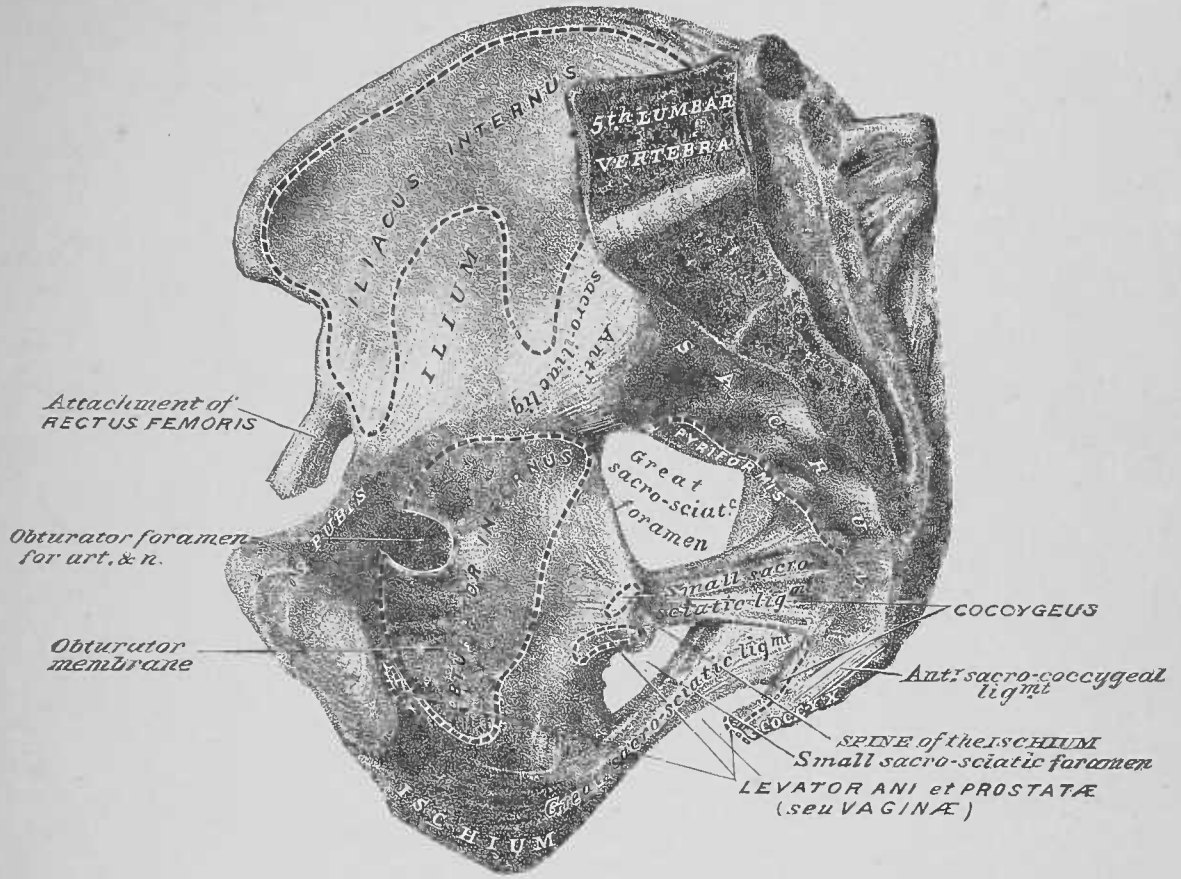
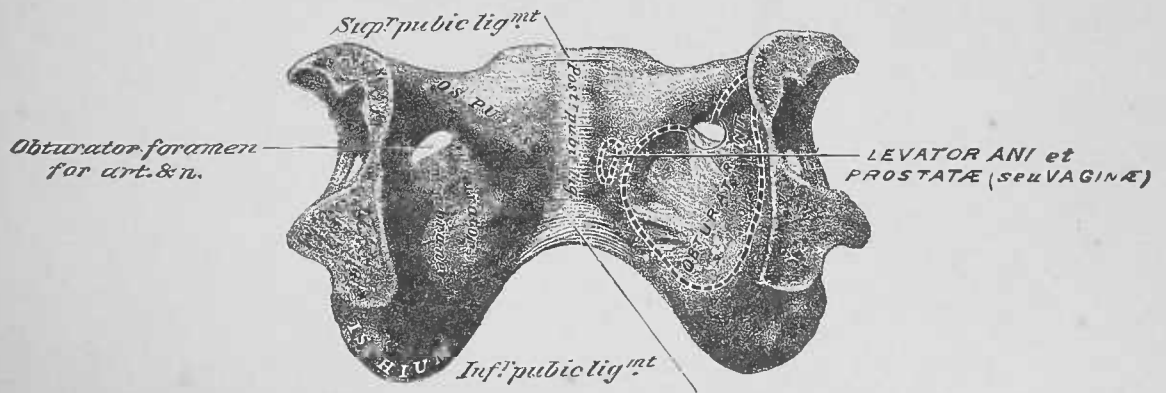
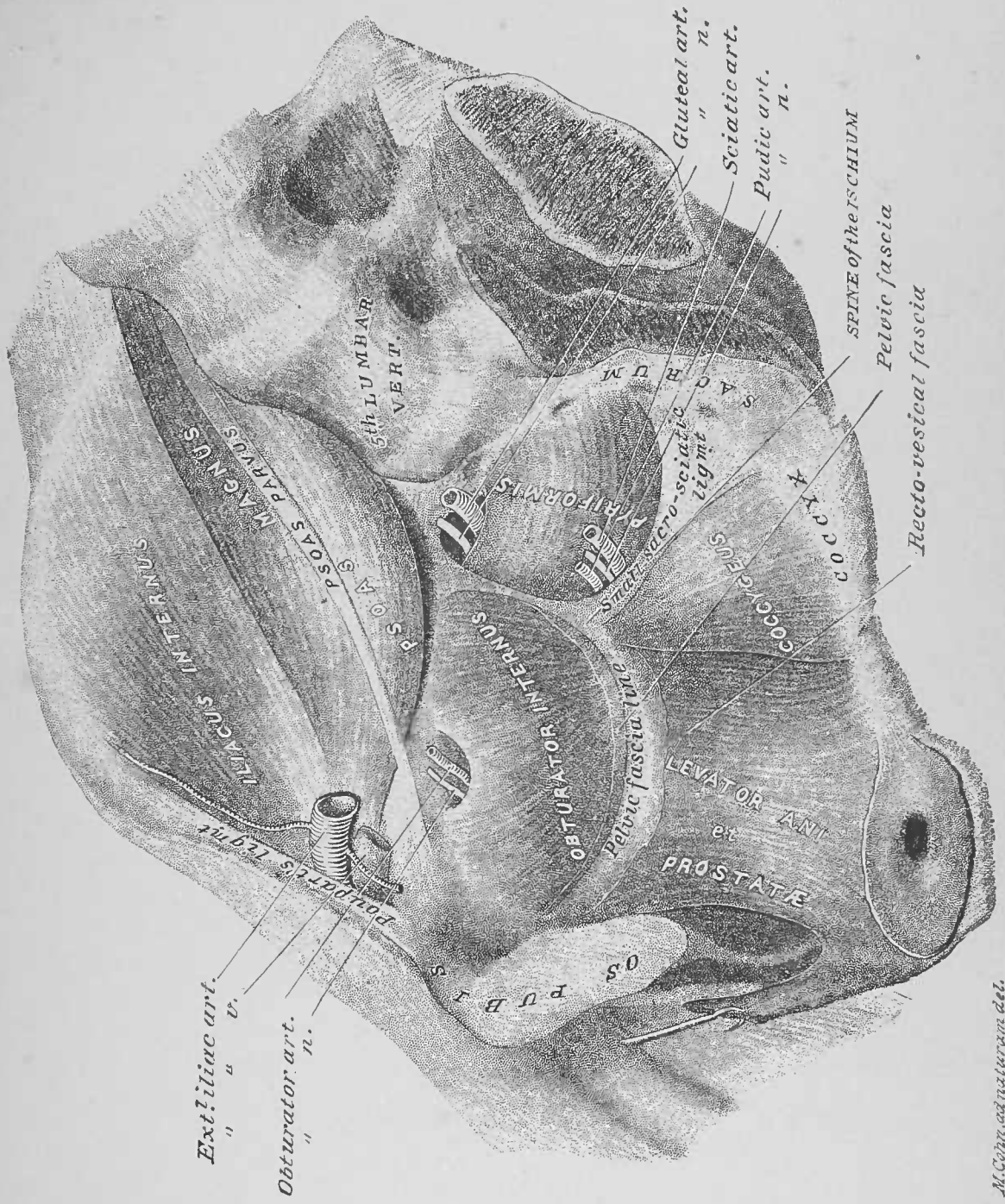


FIG. 2





M. Cohn, anatomurum del.

SIXTH DISSECTION.

ABDOMINAL VISCERA OUT OF THE BODY.

DISSECTION.—Commence the dissection of the abdominal viscera with the jejunal and ileal portions of the small intestine. Trim the shreds of the mesentery from the intestine; stretch out the latter and slit it open from the jejunal end, along its line of mesentery attachment.

1. Jejunum and Ileum of the Small Intestine, Figs. 1 and 2, Plate 47.—The exterior of the small intestine is invested by peritoneum, except at the line where the two layers of the mesentery meet; at this line of its circumference its arteries and nerves distribute to it, and its veins and lymphatic vessels leave it. The mucous membrane, that lines this intestine, presents the *valvulæ conniventes* (Fig. 1, Plate 47); these are formed by the membrane's reduplications, which have a velvety appearance, due to the villi; in the ileal portion the *valvulæ conniventes* diminish in depth and number, and are absent in its inferior third. In the ileum are found, here and there, what are known as Peyer's patches (Fig. 2, Plate 47); these are slightly depressed areas of the mucous membrane with elevated borders, the interiors being somewhat pitted; they are most numerous toward the inferior end of the ileum.

DISSECTION.—Cut off from four to six inches of the small intestine and pin it out taut upon a dissecting board (Fig. 1, Plate 47). Dissect the layers of the intestinal wall; the success of this demonstration will depend upon the freshness of the material.

2. Coats of the Small Intestine, Fig. 1, Plate 47.—This intestine will be found to present a readily demonstrable mucous membrane, a submucous plane not easily determined, a recognizable muscular coat and a well-defined serous coat. Such is the general structure of the subdiaphragmatic portions of

the alimentary canal from the œsophageal end of the stomach to the anus; special variations will be noted in the different portions of the canal.

DISSECTION.—Cut the ascending colon about six inches from the junction of the ileum with the large intestine. Note the relation of the ileum to the cæcum and colon, and that of the appendix vermiformis to all three. Demonstrate the action of the ileo-colic valve, by filling first the ileum and then the colon and cæcum with water; note that while the water will flow readily from the former into the latter, it is impossible to effect the reverse current. Cut away the external side of the large intestine opposite the ileo-colic valve (Fig. 6, Plate 47).

3. Cæcum of the Large Intestine, Figs. 4, 5 and 6, Plate 47.—The cæcum is the sac of the large intestine, which is inferior to the entrance of the ileum of the small intestine into the large intestine. At the junction of the cæcum with the colon the ileum of the small intestine opens; the two intestines are separated by a valve—ileo-colic valve. Upon the surface of the cæcum its longitudinal muscular fibres are seen so collected as to form three bands, one anterior, one postero-external, and one postero-internal; it is these bands that determine its sacculated character. The open cæcum and colon (Fig. 6, Plate 47) show the large intestine side of the ileo-colic valve; it is formed by two reduplications of the mucous membrane, which determine a button-hole slit of communication.

DISSECTION.—Search for the orifice of the canal of the appendix vermiformis into the cæcum; pass a probe into the same, and slit open the appendix.

4. Appendix Vermiformis, Plates 35 and 37; Figs. 4, 5, and 6, Plate 47.—This is a blind tube, from two to six inches long, appended to the cæcum; its relation to the cæcum and ileum varies, but, as a rule, it is curled inferiorly and internally to them, having a special meso. Its canal opens into the cæcum, passing through its wall obliquely, thereby forming a valvular opening. Its mucous membrane lining differs from that of the cæcum.

DISSECTION.—Clear the ascending, transverse and descending colon of shreds of meso-colon and omentum.

5. Colon of the Large Intestine, Plate 35.—This portion of the large intestine is distinguished as follows: by the appen-

dices epiploicæ (pellets of fat beneath its redundant peritoneal investiture) at the clefts between its sacculæ; by the continuous sacculæ of which it is formed; and by the three longitudinal bands, that are present upon its circumference. The latter were recognized at their commencement upon the cæcum; they result from the bundling of the longitudinal muscular fibres of the intestine. The bands, taken continuously, are about half the length of this portion of the large intestine, consequently, the peculiar sacculæ of this gut occur in its adaptation to the length of these bands.

DISSECTION.—Slit open the colon of the large intestine, as was done with the small intestine. Dissect out a portion of one of the longitudinal bands and determine its structure.

6. Mucous Membrane of the Large Intestine, Fig. 3, Plate 47.—This surface of the large intestine presents three longitudinal furrows, corresponding to the exterior muscle bands; between them the mucous membrane is raised into transverse prominences. Here and there more or less well defined, small, prominent points present—the solitary glands.

DISSECTION.—Commence the dissection of the stomach, spleen, duodenum, pancreas and liver, *en masse*, by cutting through the duodenum just beyond the pylorus of the stomach, and separating the latter and the spleen from the other organs. Place the liver upon its anterior surface, with its inferior border upwards, and allow the duodenum and the pancreas to lie upon their posterior surfaces, inferior to and parallel with the superior border of the liver (Plate 48). Clear the exposed areas of the organs free of adventitious tissue, determining vessels and ducts.

7. Duodenum, Plate 48.—This, the superior portion of the small intestine, was described as it presents *in situ* (page 64). In its present dissection, its relations to the ductus communis choledochus should be especially determined.

DISSECTION.—Cut away the anterior wall of the descending portion of the duodenum. Incise the ductus communis choledochus, and enter a fine probe through it into the duodenum (Plate 48); note the orifice of the ductus communis choledochus at the mucous membrane surface of the exposed posterior wall of the duodenum.

8. Ductus Communis Choledochus, Plates 48 and 49.—This duct, before described (pages 63 and 67) and illustrated

(Plates 35 and 36) *in situ*, enters the duodenum through the posterior wall of its descending portion; it receives the duct of the pancreas, before passing into the wall of the gut; it perforates the wall of the latter canal obliquely, thereby determining a valve-like opening.

DISSECTION.—Trace the superior mesenteric and splenic veins to the vena portæ.

9. Vena Portæ, Plates 48, 52, 35 and 36.—This vein takes its origin at the convergence of the superior mesenteric and the splenic veins—the latter receiving the inferior mesenteric. The trunk of the vena portæ receives the gastro-epiploica dextra, the pyloric, the gastric and the cystic veins. The vessel is from two to three inches long from its origin to where it enters the transverse fissure of the liver.

DISSECTION.—Remove the liver by cutting the ductus communis choledochus and the vena portæ, at the section lines (Plate 48). Clear away the superior mesenteric and splenic veins.

10. Pancreas, Plates 48 and 49.—This organ was described (page 65) and illustrated (Plates 35 and 36) *in situ*. In this its special dissection, it is seen to have somewhat the shape of a hammer. Its anterior surface shows its portions to be: a head, to the right, included in the concavity of the duodenum; a neck or constricted portion, anterior to the superior mesenteric vessels; a body, extending to the left; while its tip or tail-like end terminates at the left. The splenic and inferior mesenteric veins lie posterior to the left half of the pancreas.

DISSECTION.—Turn over the two organs (duodenum and pancreas); determine the vessels upon the posterior surface of the head of the pancreas. Dissect longitudinally into the superior half of the posterior surface of the pancreas, from its tip to its head, and search for the pancreatic duct; start the dissection at about the junction of the head and neck of the organ; once recognized, follow the duct to the left into the tail of the viscus and to the right toward its head.

11. Inferior Pancreatico-Duodenal Artery, Fig. 1, Plate 49, and Plate 36.—Upon the posterior surface of the pancreas, at its head, the inferior pancreatico-duodenal branch of the superior mesenteric artery presents; it there follows, from left to right, the curve of the head of the pancreas, as lodged in the concavity of the duodenum; it supplies branches to the pancreas

and duodenum, and anastomoses with the superior pancreaticoduodenal branch of the gastro-duodenal artery.

12. Pancreatic Duct, Plates 49 and 36.—This duct is lodged in the posterior and superior portion of the gland; in its course from the tail of the organ it receives contributing ductlets; in the head of the pancreas it may present two portions, the duct proper and an accessory duct (Fig. 2, Plate 49). The duct proper, as previously stated (pages 67 and 88), joins the ductus communis choledochus, before the latter perforates the coats of the duodenum, the two emptying into the gut by a common opening (Plate 36 and Fig. 1, Plate 49). The accessory duct may open into the duct proper, or, by a distinct opening of its own, into the duodenum; the pancreatic duct proper may, in turn, empty into the duodenum by a special orifice, independent of the ductus communis choledochus.

DISSECTION.—Separate the spleen from the fundus of the stomach, preserving the vessels of the former in continuity with it. Clear away the vessels at the curvatures and fundus of the stomach, slit the organ from its œsophageal orifice along its lesser curvature to within two inches of the pylorus; invert the pylorus and examine its interior appearance.

13. Interior of the Stomach, Fig. 1, Plate 50.—As the interior of the stomach lies exposed, the mucous membrane, at its œsophageal end and at the fundus, is smooth, while that of its body and pylorus is thrown into folds or *rugæ*, which run longitudinally and transversely. The communication of the organ with the duodenum is guarded by a valve—the pyloric; the latter is formed by the thickening of the coats of the organ, more especially the mucous membrane; the opening, as seen inverted, is a circular constriction.

DISSECTION.—Dissect the pancreas from the duodenum; slit the latter open from end to end, and lay it out mucous membrane upwards.

14. Interior of the Duodenum, Fig. 2, Plate 50.—Observe the development of the *valvulæ conniventes* from their commencement in the descending portion (page 64), to their full definition in the transverse or oblique portion. In the ascending and descending portions, the minute prominences of Brunner's glands may be seen. The orifices of the ductus communis choledochus and of the accessory pancreatic duct appear in the descending portion, as before indicated (page 88; Plate 48).

DISSECTION.—Clear the surfaces of the liver, and determine its ligaments, fissures, lobes, vessels and ducts.

15. Liver, Plates 51 and 52.—The liver was described (page 58) and illustrated (Plates 30, 31, 35, and 36) *in situ*. It is the largest organ of the abdominal cavity, weighing from forty to sixty ounces. It is suspended by ligaments, formed by reflections of the greater and the lesser peritoneum, and by the round ligament or obliterated umbilical vein. From the interior of the right superior and anterior parietes of the abdomen, the *broad* or *suspensory ligament* passes to the antero-superior surface of the organ (page 56). The *round ligament* was before described (page 56). The *coronary ligament* at the postero-superior border of the organ, has a superior and an inferior portion: the superior is formed by the spreading of the broad ligament, right and left, and its reflection to the diaphragm; the inferior is a reflection of the lesser peritoneum from the liver to the diaphragm. The *two lateral ligaments* are the right and left extensions of the portions of the coronary ligament, from the superior lateral angles of the liver to the diaphragm.

The postero-inferior surface of the liver is mapped out by furrows, which are called *fissures*. The *umbilical fissure* and the *fissure for the ductus venosus*—named from the parts they lodge—are the two portions of a longitudinal furrow, which commences at the inferior or free border of the organ—at the notch there presenting—and continues across it to its superior border. The *transverse fissure*—about three inches long—runs at a right angle from the right of the junction of the two last-described fissures. The *fissure for the gall-bladder* extends from near the right extremity of the transverse fissure to the inferior border of the viscus. The *fissure for the vena cava* runs obliquely from near the right extremity of the transverse fissure to the superior border of the gland.

The *five lobes* of the liver are mapped out by the fissures upon its postero-inferior surface, as follows: the *right lobe* to the right of the fissure for the vena cava, the fissure for the gall-bladder and the right end of the transverse fissure; the *lobus quadratus* by the transverse fissure superiorly, the fissure for the gall-bladder to the right and the umbilical fissure to the left; the *lobus Spigelii* by the transverse fissure inferiorly, the fis-

sure for the vena cava to the right and the fissure for the ductus venosus to the left ; the *lobus caudatus* extends from the lobus Spigelii into the right lobe, between the right extremity of the transverse fissure and the inferior end of the fissure for the vena cava ; the *left lobe* to the left of the fissure for the ductus venosus and the umbilical fissure.

The liver is partially invested by peritoneum. The greater peritoneum projects the two layers of the broad or suspensory ligament to the antero-superior surface of the organ, which spread therefrom right, left, superiorly and inferiorly : superiorly, it extends to the border of the organ, to become the superior portion of the coronary and the lateral ligaments ; inferiorly, it reaches the border of the viscus and then passes to its postero-inferior face, and, at the inferior limit of the transverse fissure, it is reflected to the lesser curvature of the stomach, as the anterior layer of the gastro-hepatic omentum. The lesser peritoneum invests the postero-inferior surface of the liver superior to the transverse fissure, and, from the superior limit of the fissure, it is reflected as the posterior layer of the gastro-hepatic omentum. At the fissures and the area included by the portions of the coronary ligament, the peritoneum is wanting ; at the latter point the organ is in contact with the diaphragm. The cut surface of the liver presents a dull red color and a dense somewhat granular structure ; the dilated orifices of the hepatic veins appear, while the hepatic arteries are closed.

16. Hepatic Artery, Plates 52 and 48.—This vessel was described (page 63) and illustrated (Plates 35 and 36) *in situ*. Reaching the transverse fissure of the liver, it divides into a right and a left branch, which enter the organ.

17. Vena Portæ.—Formed as before described (page 88) and illustrated (Plates 35 and 36) *in situ*, this vessel branches, right and left, into the transverse fissure of the liver ; at the fissure it is lodged inferior to the lobus Spigelii ; in the foetus the right branch is continuous with the umbilical vein, and the ductus venosus ; in adult life the umbilical vein is, at times, pervious for a variable distance from the vena portæ.

18. Biliary Ducts.—The right and the left leave the liver at the transverse fissure, in a plane inferior to the hepatic arteries ; the two unite into a single canal, the *hepatic duct*,

which receives the *cystic duct* from the gall-bladder; beyond this the canal is called the *ductus communis choledochus* (pages 63, 67 and 87; Plates 35, 36 and 49).

19. Vena Cava Inferior.—This venous trunk impinges upon the liver in the fissure for the vena cava; it continues superiorly, to the area of the organ not covered by peritoneum, where it bridges from the liver to the caval opening of the diaphragm.

20. Hepatic Veins.—The hepatic veins emerge from the liver to empty into the vena cava inferior, in the bed of the fissure for the vena cava and the area at the superior border of the organ not invested by peritoneum.

DISSECTION.—Dissect the gall-bladder free from the fissure, in which it is lodged; section the cystic duct close to the hepatic, also the cystic artery at the hepatic artery. Open the gall-bladder at its fundus, and slit it open to its duct.

21. Gall-Bladder.—This is a pyriform sac, the duct of which is more or less tortuous; the latter may be straightened somewhat by dissecting off the areolar tissue, which invests it.

DISSECTION.—Remove any shreds of peritoneum from the spleen. Determine the vessels of the spleen at its internal surface; after which, it may be placed upon its convex external surface, with its posterior border toward the dissector; then holding the vessels on the stretch toward its posterior border, slice away the spleen tissue of the internal portion of the organ from the hilus to its anterior border, at a sufficient depth to expose the vessels that penetrate the viscus.

22. Spleen, Plate 53.—This organ was located (page 66) and illustrated (Plates 35 and 36) *in situ*. It is somewhat oval in shape, convex and smooth upon its external surface, slightly concave upon its internal surface. It weighs from four to eight ounces. At its internal surface a vertical fissure—the hilus—divides it into two unequal portions, an anterior and a posterior: the anterior and larger area is applied, in order from above downwards, to the stomach, the tail of the pancreas and the splenic flexure of the colon; the posterior and smaller area impinges upon the left suprarenal capsule and kidney. At the hilus the splenic artery and nerves (sympathetic) enter the organ, and the splenic vein and lymphatic vessels leave it. The gastro-epiploica sinistra artery is given off to the stomach from the splenic artery,

at the inferior limit of the hilus of the spleen ; the vasa brevia to the stomach are supplied by branches of the splenic artery opposite the hilus. The slicing away of the spleen tissue, from the anterior half of its internal surface, demonstrates the penetration of vessels into the viscus, and determines by their distribution three portions to the organ : a superior, a middle, and an inferior. Its tissue is darker and much less dense than that of the liver.

DISSECTION.—Let the kidneys, the suprarenal capsules and the portions of the aorta and vena cava, as they were removed from the body (page 79), be laid out in their normal relations, upon a dissecting board. Cut the renal and suprarenal arteries at the aorta, their veins at the vena cava. Clear the surfaces of the suprarenal capsules and kidneys, and determine the relations of the two organs to each other ; after which they may be separated.

23. Suprarenal Capsules, Fig. 1, Plate 54.—These viscera were described (page 71) and illustrated (Plate 38) *in situ*. A capsule will average about one drachm and a half in weight ; it is triangular in shape, slightly concave at its base, for application to the convexity of the kidney, and presents at its anterior face a hilus for the entrance and exit of its vessels, etc.

DISSECTION.—Determine the relations of the vessels and the ureter, that present at the internal border of the kidney. Grasp the kidney in the left hand, its internal border to the palm, its external convex border projecting between the thumb and fingers : as held, section with a scalpel its fibrous capsule along the convexity of the organ, then peel it off of its anterior and posterior surfaces to its internal border, where it will be found to pass into the hilus ; trim the capsule away close to the hilus. Trace the vessels into a kidney as follows : place the kidney upon its posterior surface (Fig. 4, Plate 54), with the renal vein uppermost ; hold taut the vessels and ureter, and cut away the kidney tissue from the internal to the external border of the anterior face of the organ, down to the plane of the renal vein ; this will determine the course of both the veins and the arteries. To follow a ureter into a kidney, place the organ upon its anterior surface (Fig. 3, Plate 54), and pin the ureter and kidney taut ; slice off the posterior half of the kidney, from the internal to the external border, down to the plane of the walls of the pelvis and the infundibula. Demonstrate the three infundibula which converge to the pelvis of the organ : the superior, the middle, and the inferior ; open the infundibula so as to examine their terminations in the calices, which surround the apices of the pyramids of Malpighi.

24. Kidneys, Figs. 2, 3, and 4, Plate 54.—These organs were described (page 71) and illustrated (Plate 38) *in situ*. A kidney will average about four and one-half ounces in weight.

In shape, the organ is flattened antero-posteriorly, with a convex external border ; it has convex superior and inferior ends, which curve in at the internal border ; its internal border presents a notch—the hilus—which lodges the pelvis of the organ, the supplying artery and nerves, and the outcoming veins and lymphatics ; these are bedded in interstitial adipose tissue. At the hilus (Figs. 2 and 4, Plate 54) the relations of parts are as follows : the renal vein is anterior, the ureter posterior, and the renal artery in the middle. In structure a kidney presents : a capsule ; a peripheral portion—the cortical substance ; an interior portion—the medullary ; and an internal portion—the pelvis. The *capsule* is a fibrous investment, which may be peeled off and traced into the hilus, where it is continuous with the walls of the calices of the pelvis. The *cortical substance* is dense tissue without distinctive parts, to the unaided eye ; it is continued into the medullary portion as the *columns of Bertini*. The *medullary portion* is made up of the *pyramids of Malpighi*—formed by the tubuli uriniferi—separated by the columns of Bertini—through which vessels and nerves run ; the bases of the pyramids are directed toward the cortical portion, their apices—presenting the orifices of the tubuli uriniferi—are the *papillæ* projected into the pelvis. The *pelvis portion* is a fibrous sac, with the following parts : the *calices*—at the bottom of the hilus—or the coves, so to speak, between the promontories of the papillæ of the pyramids ; the *infundibula*—superior, middle, and inferior—or bays into which the calices empty ; and the *pelvis proper* or lake-like expansion of the infundibula, whose outlet is the *ureter* or duct of the organ.

25. Renal Veins, Plate 38, and Figs. 2 and 4, Plate 54.—A renal vein, after being formed by several vessels that leave the hilus, empties into the vena cava inferior ; of the renal veins the left is the longer of the two.

26. Renal Artery.—This artery enters the kidney at the hilus ; it breaks up into branches, which pass to the cortical substance, through the columns of Bertini.

27. Renal Nerves, Plate 33.—These nerves, derived from the renal plexus of the sympathetic nerve, enter the kidney upon the renal artery, and its branches.

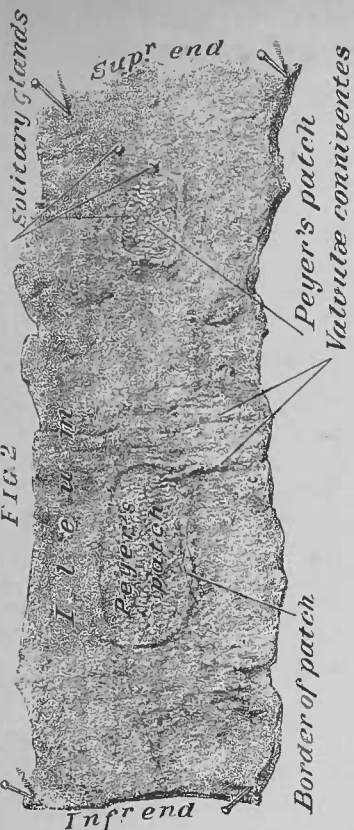


FIG. 2



FIG. 1

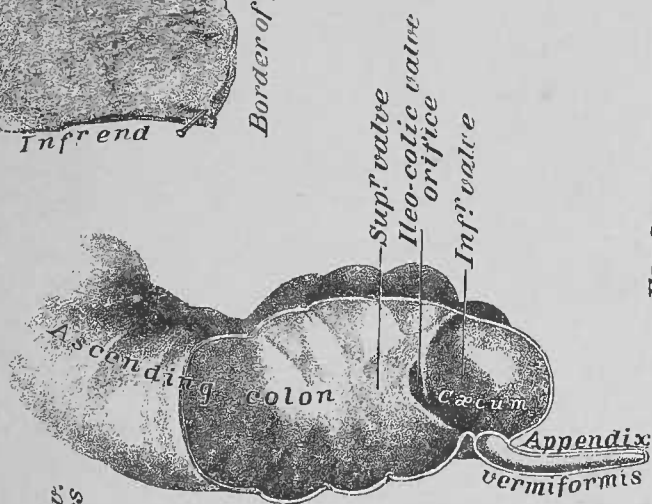


FIG. 6

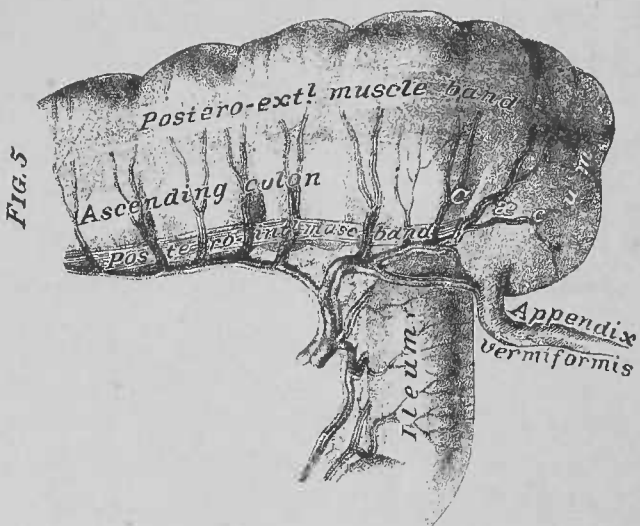


FIG. 5

FIG. 3

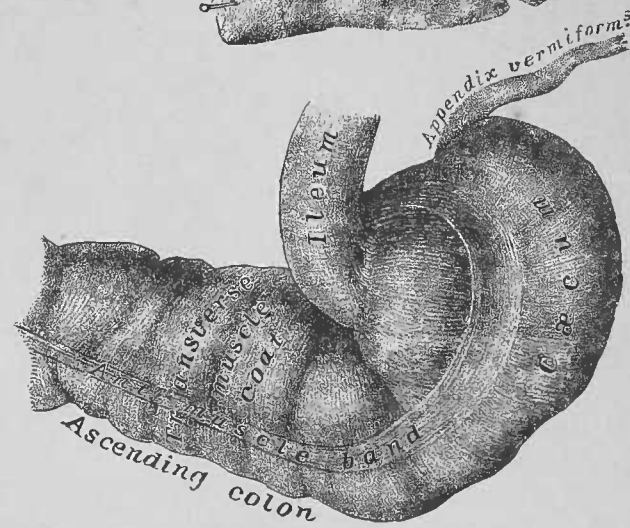

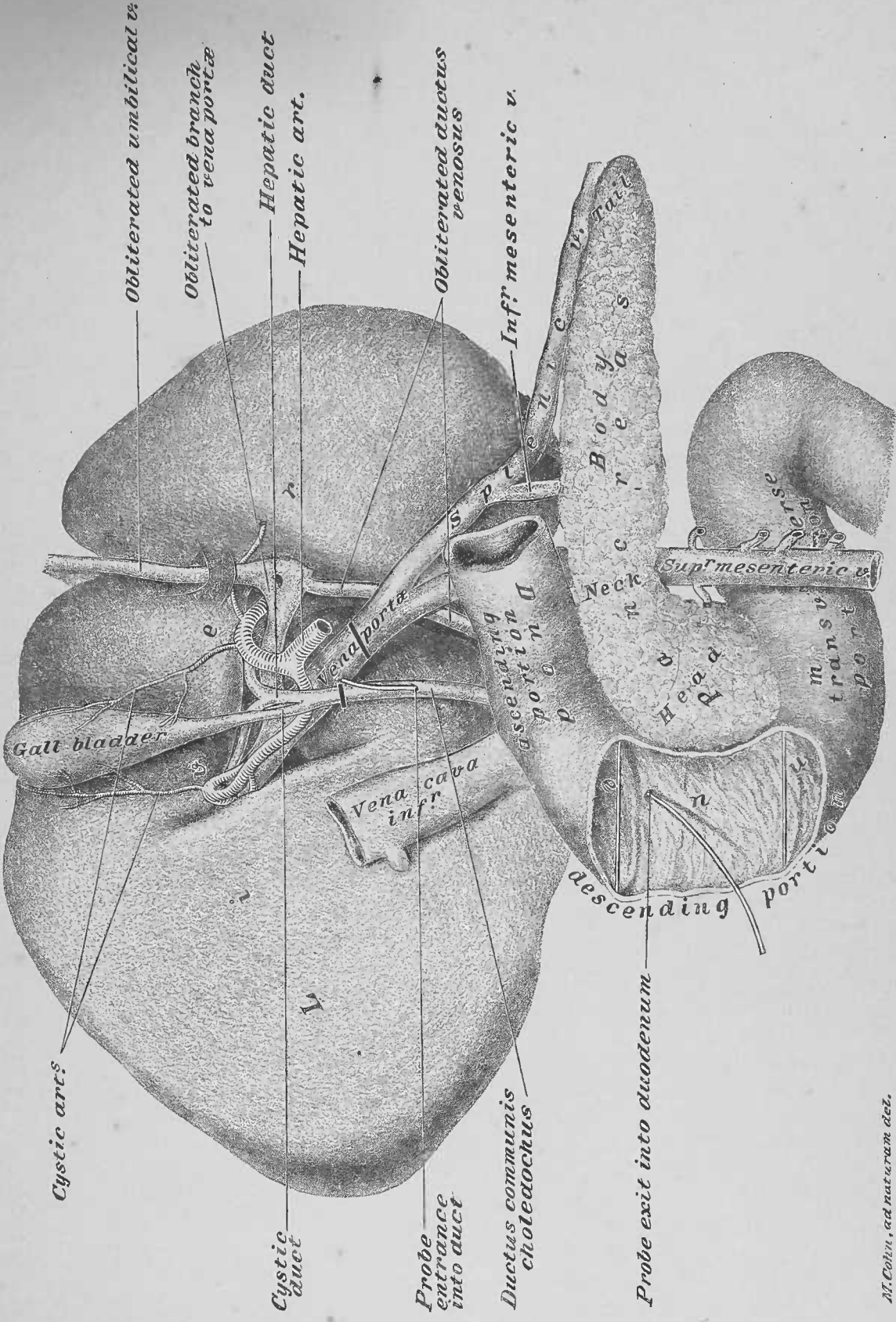


FIG. 4



M. Cohn, ad naturam del.

FIG. 1

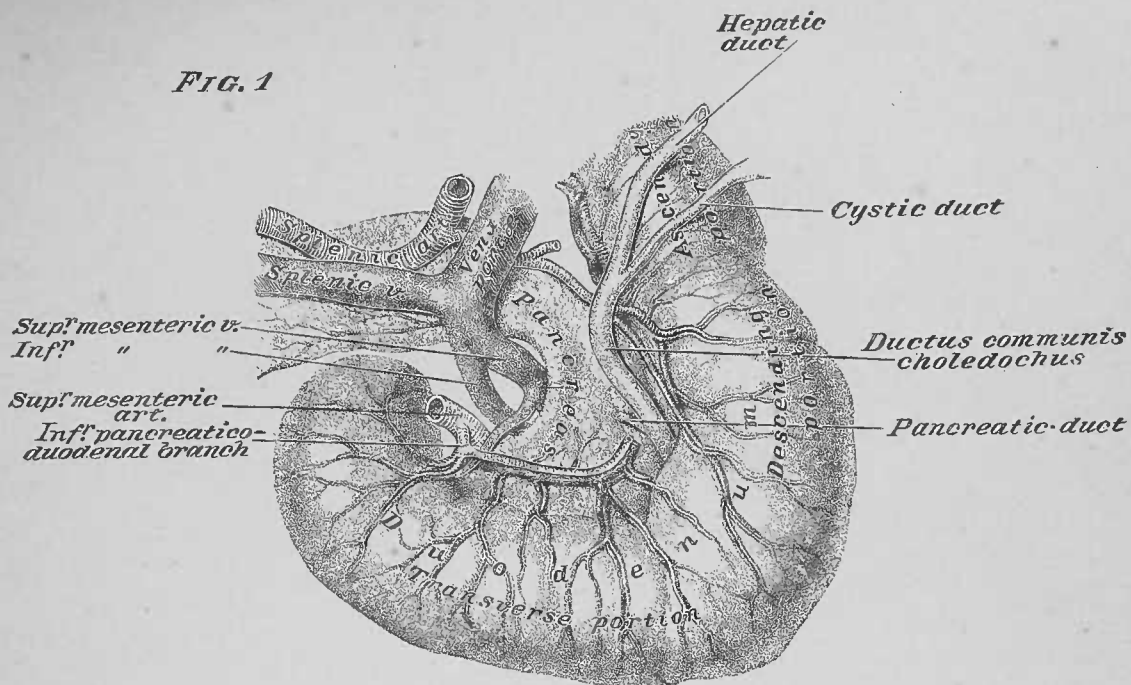


FIG. 2

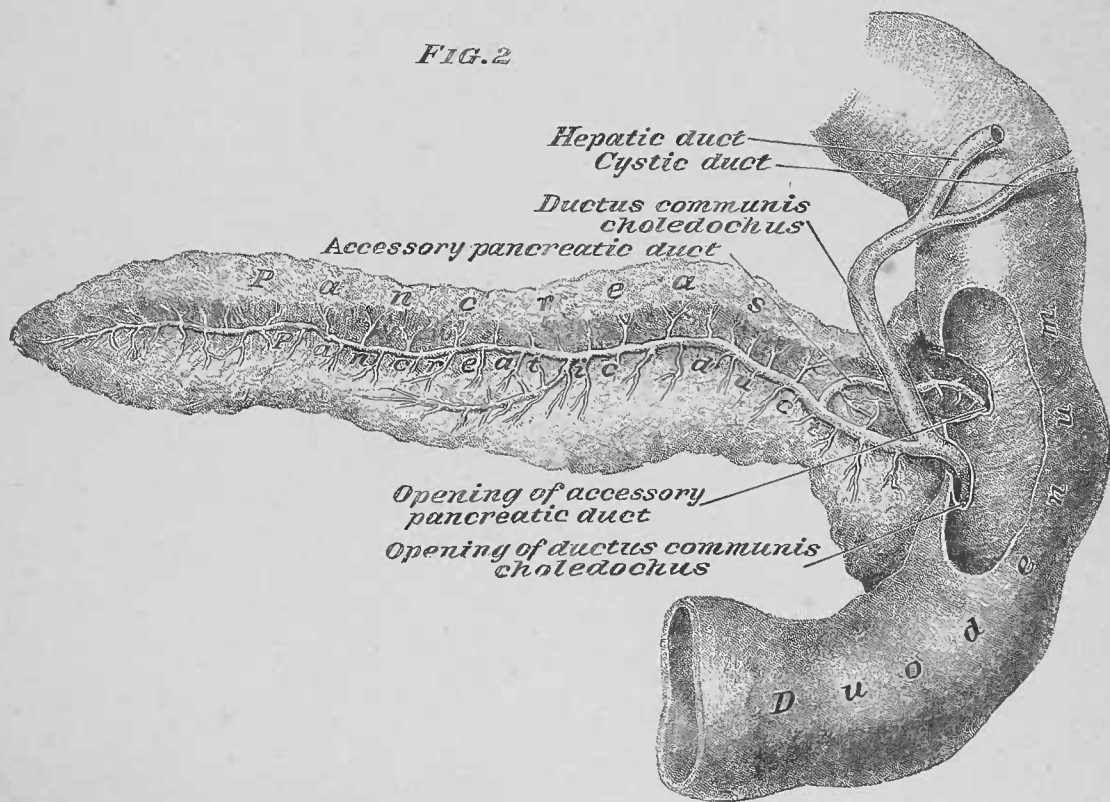


FIG. 1

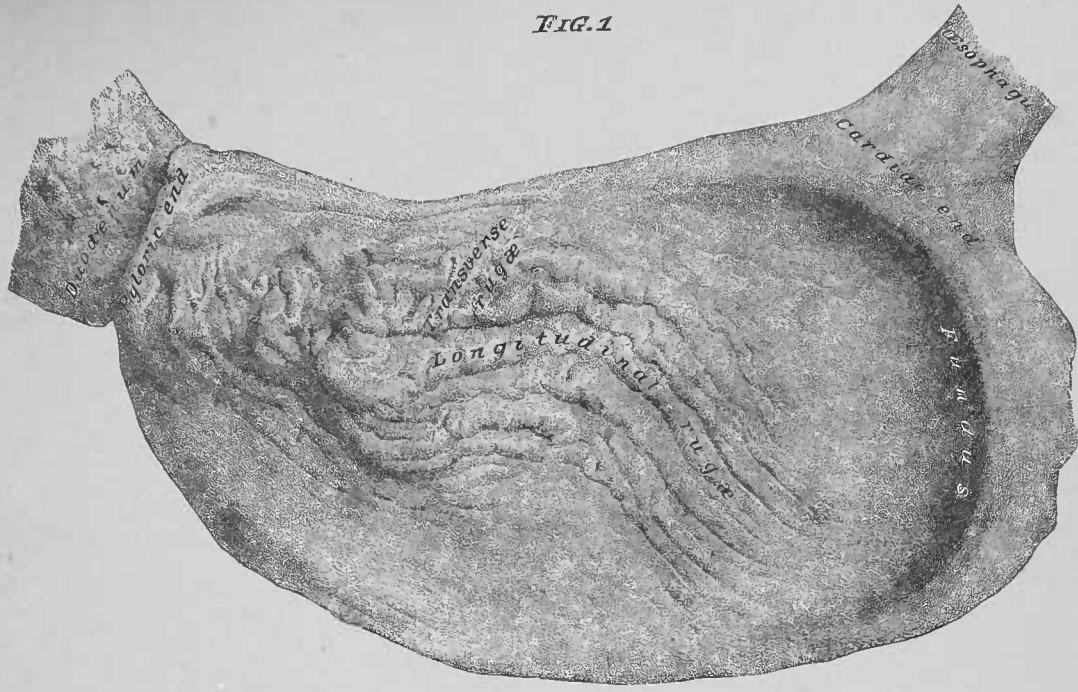
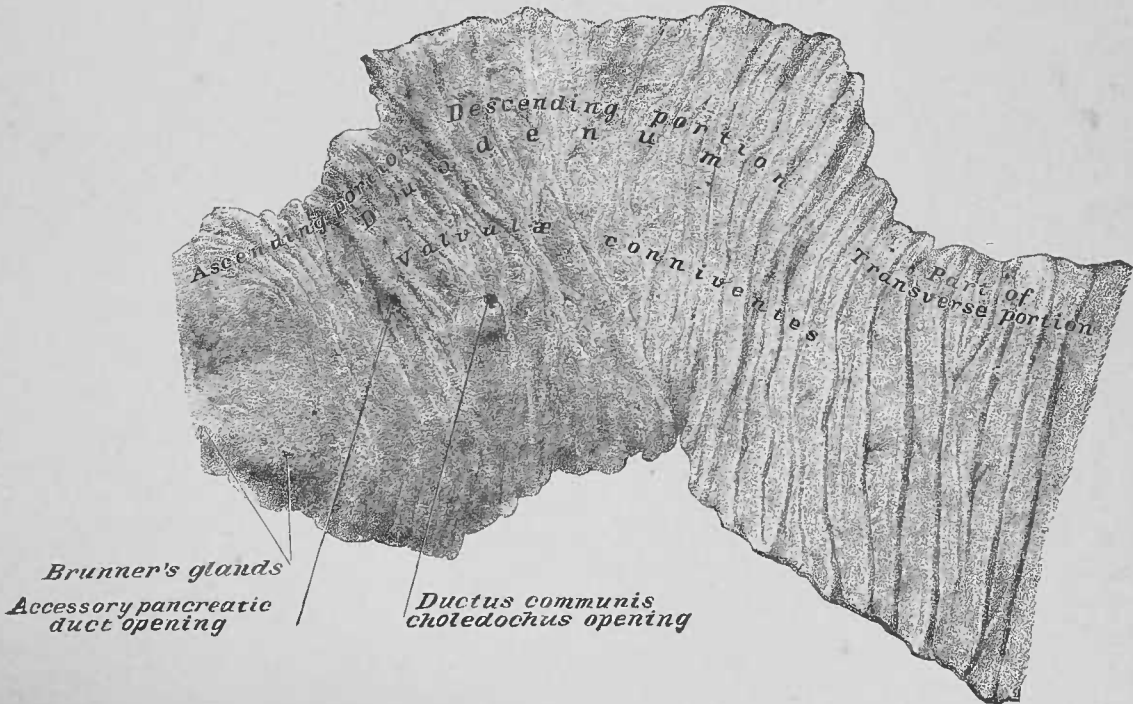
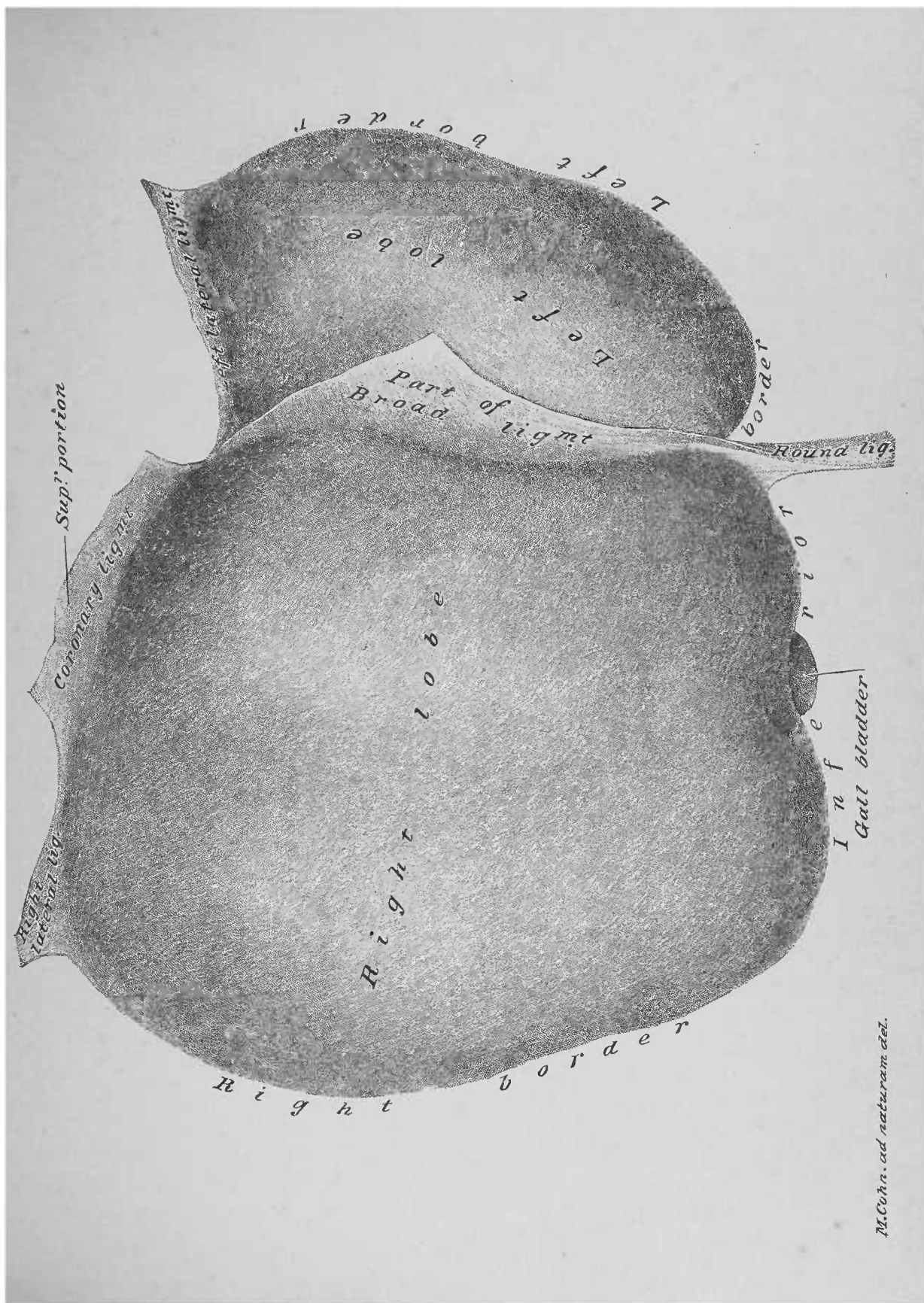


FIG. 2





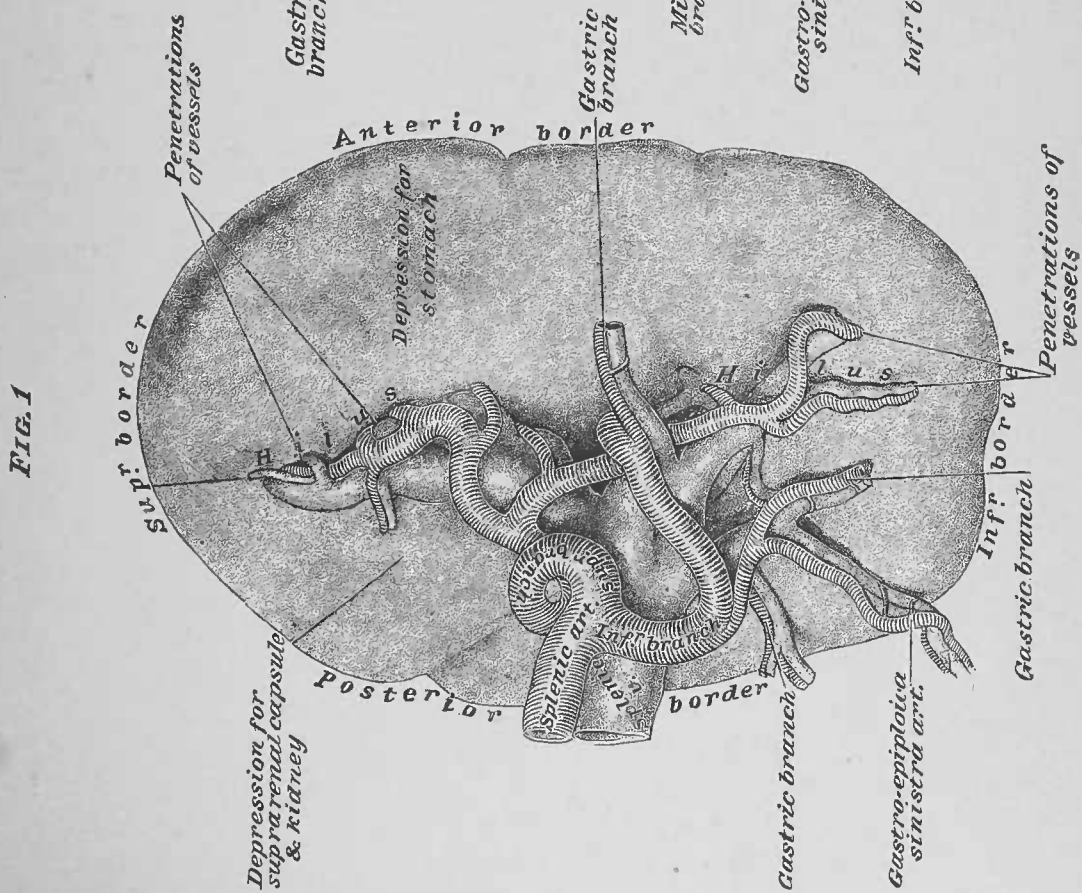
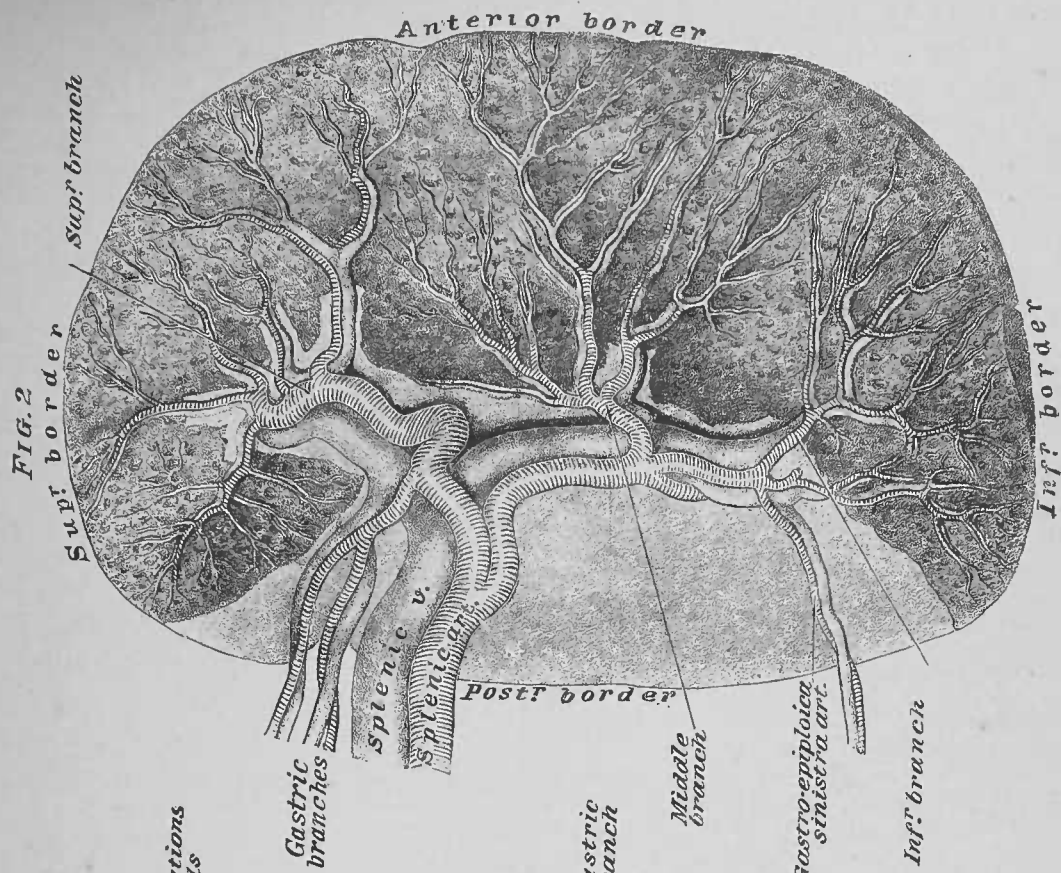
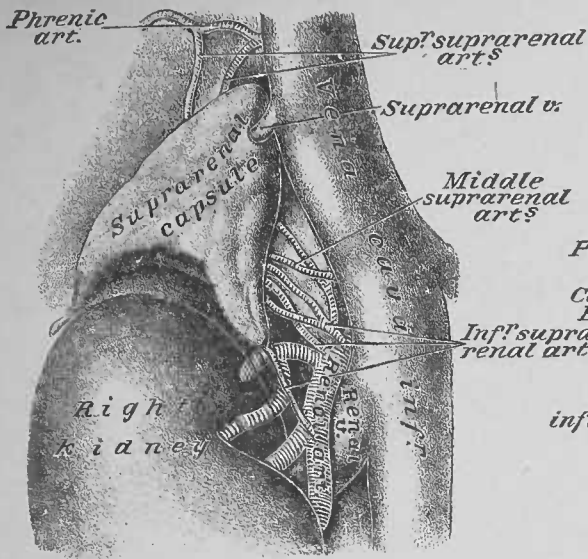


FIG. 1



Supr' infundibulum
Column of Bertini

FIG. 3

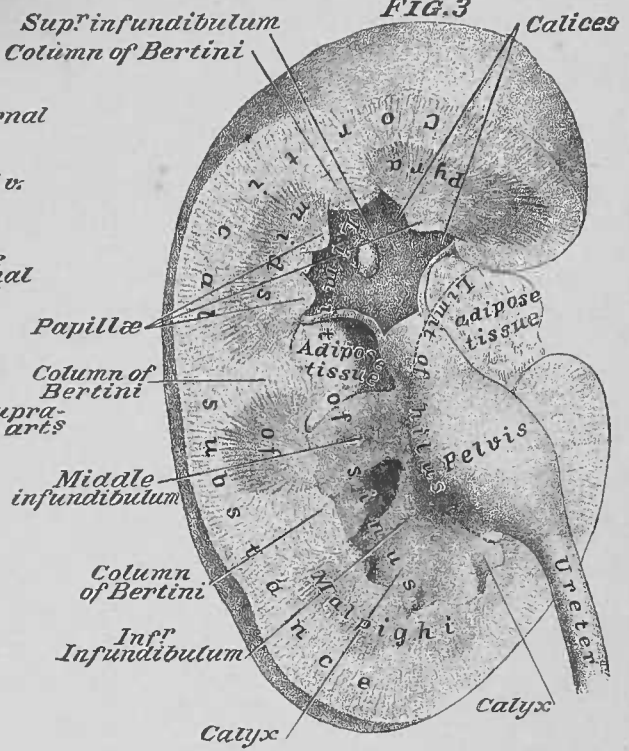


FIG. 2

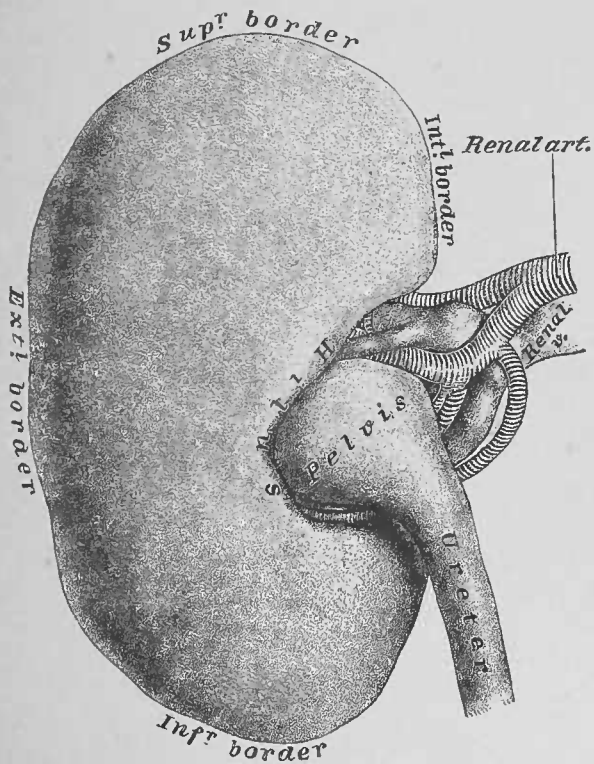
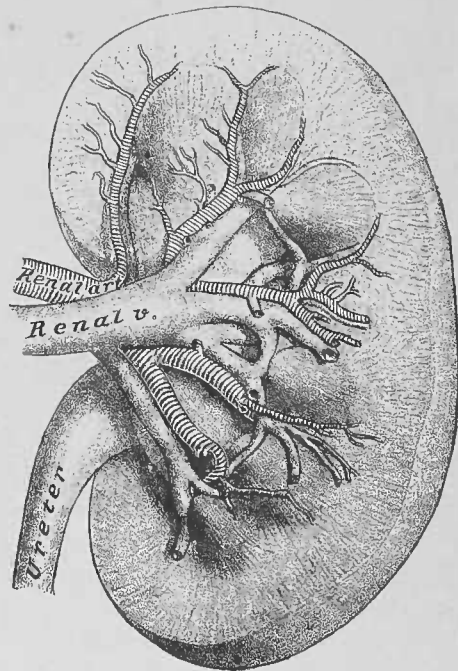


FIG. 4



SEVENTH DISSECTION.

MALE PELVIC VISCERA OUT OF THE BODY.

DISSECTION.—In the dissection of the male perineum, the mutual relations of the base of the bladder, the prostate, the vesiculæ seminales, the vasa deferentia, and the rectum were recognized (pages 26 and 27) and illustrated (Plate 12) *in situ*. At present the viscera, as taken from the pelvis *en masse* (page 73), should be dissected, after which the separate organs will claim special attention. The rectum and bladder may be inflated, or better, the rectum may be stuffed with oakum from its superior end; the bladder, opened by a transverse incision at the superior portion of its anterior wall, may also be inflated or filled with oakum. Clean the exterior of the rectum and bladder of shreds of connective tissue; preserve all arteries and nerves hanging from the organs.

1. Rectum, Bladder, etc.—The rectum as distended presents the double curvature, which determines its three portions; in the concavity of its second portion, the bladder, vesiculæ seminales, and prostate are lodged.

2. Peritoneal Investment of Bladder, Plates 12, 31, and Fig. 1, Plate 37.—The fundus, the two lateral, and the posterior surfaces of this organ are invested by peritoneum. Posteriorly, the peritoneum descends to the line of the posterior extremities of the vesiculæ seminales, where it is reflected to the rectum, as the recto-vesical cul-de-sac (pages 27 and 67).

3. Peritoneal Investment of Rectum, Plate 31, and Fig. 1, Plate 37.—The anterior and the right lateral surfaces of the first portion of the rectum, and the anterior and right lateral surfaces of the superior part of the second portion are covered by peritoneum.

DISSECTION.—Cut the peritoneal reflection between the bladder and rectum, and dissect the rectum from the bladder, etc. Cut the vasa deferentia at about four inches from the prostate, thus detaching the testes. The rectum and testes may be returned to the preservative fluid. Cut the ureters about two inches from their vesical ends. Open the bladder and pin it and the penis to a dissect-

ing board, with the exterior of the base of the bladder and the inferior surface of the penis uppermost. Determine the ureters, the vasa deferentia, the vesiculæ seminales, the prostate, the membranous portion of the urethra, Cowper's glands, the bulb of the corpus spongiosum, and the crura of the corpora cavernosa.

4. Ureters, Fig. 1, Plate 55.—The superior portions of these renal ducts were recognized (page 72) and illustrated (Plate 38) *in situ*; their inferior portions were left passing into the pelvic cavity upon the interior of its lateral walls; now they are seen perforating the wall of the bladder.

5. Vasa Deferentia. 6. Vesiculæ Seminales. 7. Exterior of Trigone. 8. Prostate (inferior surface). 9. Membranous Portion of the Urethra (inferior surface). 10. Cowper's Glands. 11. Bulb of the Corpus Spongiosum. 12. Crura of the Corpora Cavernosa.—The parts, 5 to 12 inclusive, were described and illustrated in the dissection of the Male Perineum (pages 19, 20, 22, 23, 26; Plates 10 and 12).

DISSECTION.—Section the prostate on the median line from the notch at its base toward its apex, so as to expose the ejaculatory ducts, traversing its substance.

13. Ejaculatory Ducts, Plate 55.—These ducts, a right and a left, result from the convergence of the right and left vas deferens with the duct of the right and left vesicula seminalis, respectively. The junctions of these ducts take place at or within the prostate; as formed, the ejaculatory ducts continue in a channel through the prostate.

DISSECTION.—Enter probes or wisps of broom-straw into the ureters and vasa deferentia (Fig. 1, Plate 55); unfasten the bladder and penis; then pin them again to the dissecting board, with the interior of the former and the dorsum of the latter uppermost. Section the penis, a little to one side of the median line of its dorsum, from the glans penis to the bladder, so as to separate the corpora cavernosa and to open into the urethral canal, from the meatus to the bladder (Fig. 1, Plate 56); secure the penis, so as to expose the inferior wall of the urethra.

14. Interior of the Bladder, Fig. 2, Plate 55.—The interior of this organ has a smooth, pale mucous membrane; at its base are seen to protrude the probes at the orifices of the ureters. An interior trigone area appears, which is smaller than the exterior one; the orifices of the ureters are at the angles of its base line, about one inch and a half apart; the

opening into the urethra, at the neck of the bladder, forms its apex, about one inch and a half from the openings of the ureters, respectively. The mucous membrane of the trigone area differs from that of the rest of the interior of the organ, in that it is studded with mucous glands.

15. Urethra, Fig. 2, Plate 55, and Fig. 1, Plate 56.—The urethra extends from the bladder to the meatus urinarius; it is a urino-seminal duct—urinary from the bladder, and seminal from the prostatic portion of the urethra. It averages about eight inches in length, and has a prostatic, a membranous, and spongy portion. It is lined by mucous membrane, continued from the bladder and from the ejaculatory ducts; at the meatus (the narrowest part of the canal) the membrane is continuous with the skin upon the glans penis.

The *prostatic portion*, one inch and a quarter long, presents, along the mucous membrane lining of its inferior wall, a median-line longitudinal raphe or urethral crest, which continues, posteriorly, to the neck of the bladder, and, anteriorly, into the membranous portion of the canal. At the highest point of the crest is the caput gallinaginis or veru montanum, which presents the opening of the sinus pocularis, or male utricule (analogue of the uterus of the female); from this sinus the probes or wisps entered into the vasa deferentia (page 95), protrude from the ejaculatory ducts, which open into it. The mucous membrane at the sides of the urethral crest presents the orifices of mucous glands—the prostatic follicles.

The *membranous portion*—three-quarters of an inch long—is the narrowest portion, and is located between the prostate and the corpus spongiosum. The narrowest interior point of the urethral canal is the opening through the triangular ligament (page 20), which is at the junction of the membranous and spongy portions.

The *spongy portion*, six inches long, tunnels the corpus spongiosum cylinder of the penis, and is divided in turn into three sections: the bulbous, the body, and the glands or fossa navicularis. The *bulbous* is the deepest section; it is about one inch in length, has the largest calibre of the three, and presents the openings of the ducts from Cowper's glands. The *body*, about four inches long, is the narrowest part of the spongy portion of the urethra. The *fossa navicularis*, an

inch in length, is an expansion of the urethra, which is situated just within the meatus urinarius, and is lodged in the glans portion of the corpus spongiosum. The mucous membrane of the urethra presents the orifices of sinuses, known as lacunæ; the largest of these is located in the superior wall of the fossa navicularis—the lacuna magna.

DISSECTION.—Detach the bladder and penis from the dissecting board. Cut through the membranous portion of the urethra. Cut the vesiculæ seminales at the points of junction of their ducts with the vasa deferentia and dissect them from the bladder; straighten the convoluted tube of a vesicula seminalis.

16. Prostate, Plates 12, 55, and Fig. 1, Plate 56.—This is a muscular organ, which encloses two canals: one for the transit of the ejaculatory ducts; the other for the urethra. Its muscular structure is continuous with the muscle coat of the neck of the bladder, and with that of the membranous portion of the urethra. In the prostatic portion of the urethra are mucous glands, known as the prostatic follicles, which have led to the organ being called the prostate gland; this appellation is incorrect, as its follicles are of but secondary importance. Anteriorly, it is a single organ, but, posteriorly, it is divided by the cleft at its base (page 26) into a right and a left lobe. The portion inferior to the neck of the bladder forms an isthmus, which unites its two lobes; this isthmus may, in old age, become hypertrophied, which circumstance has led to its being called the middle lobe of the prostate; normally the organ has no middle lobe.

17. Vesiculæ Seminales, Fig. 1, Plate 55.—A vesicula seminalis will be found upon dissection to be a single convoluted tube about six inches long; from the tube blind sacs are projected at intervals.

18. Penis, Figs. 1 and 2, Plate 56, and Fig. 1, Plate 55.—The enveloping sheaths, the vessels and the nerves of this organ are presented in the section Fig. 2, Plate 56; these several parts were described (pages 44, 45 and 46) and illustrated (Plate 22) *in situ*. The penis is formed by three longitudinal bodies or cylinders: the right and left corpus cavernosum, and the corpus spongiosum.

The *corpora cavernosa* are attached by their crura and by the ischio-cavernosi muscles to the rami of the pubic arch

(pages 20 and 19); the crura converge over the bulb of the corpus spongiosum and meet at the median line to form the dorsal longitudinal cylinders of the penis; the corpora have an investing fibrous capsule and are separated by a fibrous septum.

The *corpus spongiosum* (page 19; Plates 8 to 12 inclusive) presents three sections: the bulb, the body, and the glans. The *bulb* is lodged between the crura of the corpora cavernosa; the *body* continues forward inferior to the corpora cavernosa as far as the free ends of the latter; the *glans* is its expansion, capping the ends of the corpora cavernosa.

DISSECTION.—A testis, with the scrotal portion of the spermatic cord, should be laid upon a dissecting board and pinned thereto—one pin through the body of the testis, another through the proximal end of the outstretched spermatic cord. Section the sheath (internal spermatic or infundibuliform fascia), investing the cord, and reflect the same. Open the tunica vaginalis of the testis and reflect it; recognize the testis, the epididymis, the vas deferens, the vas aberrans, the artery of the vas deferens, the spermatic artery, the spermatic veins, the spermatic nerves (sympathetic); the latter are continued to the testis upon the artery.

19. Internal Spermatic Fascia, Fig. 3, Plate 56.—This sheath of the spermatic cord and the testis (page 54) is continued as an infundibuliform (funnel spout) prolongation of the transversalis fascia; it blends with the tunica vaginalis of the testis. It occupies a plane interior to the cremasteric muscle fibres of the spermatic cord (page 50).

20. Tunica Vaginalis.—This is the serous investment of the testis. It is a closed sac, which is applied to the antero-lateral surfaces of the testis; it has a visceral and a parietal layer. It, originally, was a portion of the peritoneum, which descended from the abdominal cavity with the testis; at first it has a canal of communication (the canal of Nuck) with the cavity of the peritoneum; later the canal becomes obliterated into a fibrous thread.

21. Testes.—A testis is an ovoid body, weighing from four to eight drachms and suspended from the end of the spermatic cord. It is partially invested by the tunica vaginalis; its posterior surface (in the illustration the accidental position of the testis would make it appear, that it was the superior surface), not invested by the tunica vaginalis, presents the hilus of the

organ, where vessels, nerves, and ducts pass. The testis has a fibrous capsule—the *tunica albuginea*. Upon section a testis presents a grayish pulp which extrudes from compartments of the gland.

22. Vas Deferens, Fig. 3, Plate 56, and Plates 29 and 38.—This duct, about two feet in length, commences at the hilus of the testis; it is a recognizable element of the spermatic cord, being like a hard cord of about the size of a thick knitting-needle.

23. Epididymis, Fig. 3, Plate 56.—The epididymis is the convoluted portion of the vas deferens; it is lodged posterior to, and opposite the hilus of the testis. Its portions are the *globus major*, at the superior end (in the figure at the right end); the *body* parallel with the hilus; the *globus minor*, at the inferior end (in the illustration the left end). From the last-named portion the straight part of the vas deferens is continued.

24. Vas Aberrans.—This is a short blind duct, about one and a half to two inches long, which springs from the globus minor of the epididymis; it runs parallel with the vas deferens in the spermatic cord.

25. Artery of the Vas Deferens.—This artery accompanies the vas deferens in the spermatic cord, distributing to it and to the epididymis.

26. Spermatic Artery.—This artery is an element of the spermatic cord, distributing to the testis, the hilus of which it enters.

27. Spermatic Veins.—These leave the testis at its hilus, forming a plexus (the pampiniform) in the scrotal portion of the cord; from the plexus two veins result, which form the venæ comites of the spermatic artery.



1786

FIG. 1.

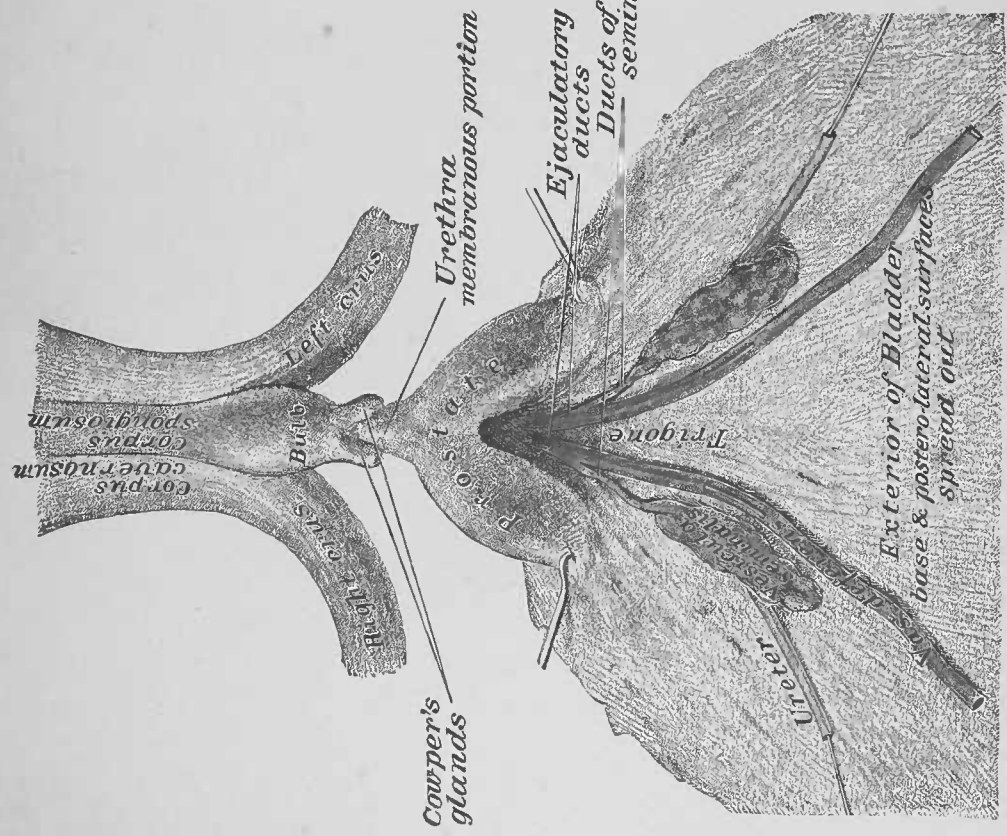
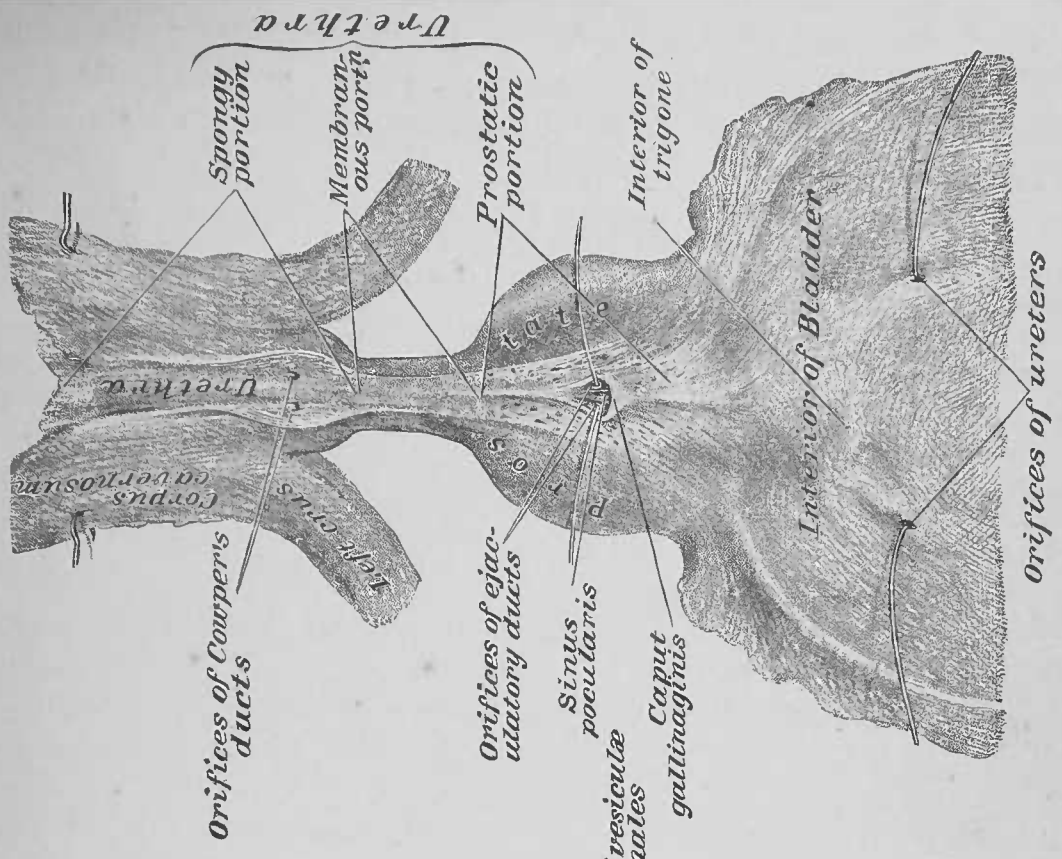


FIG. 2.



M. Cohn, ad naturam del.

EIGHTH DISSECTION.

FEMALE PELVIC VISCERA OUT OF THE BODY.

DISSECTION.—The female pelvic viscera, as taken *en masse* from the body (page 73), may be dissected upon a dissecting board. The rectum and bladder should be prepared as in the dissection of the male pelvic organs (page 95); the vagina should be moderately distended with oakum. In the dissection of these organs as they presented at the pelvic outlet (pages 40, 41; Plates 19 and 20), the relations of the organs were disturbed; they should now be carefully adapted in their normal relations, with one of their lateral surfaces uppermost. All connective tissue should be removed from them, being careful to preserve their peritoneal investiture, the vessels distributing to them, and the broad ligaments of the uterus, with its associated parts.

1. Lateral View of the Female Pelvic Viscera.—In this view of the viscera the rectum presents as a canal with two curvatures; its postero-inferior convexity is for lodgment in the concavity of the sacrum; its antero-superior concavity receives the postero-inferior convexity of the vagina. The uterus protrudes from the superior end of the vagina, with a broad ligament projected from its lateral border. The intimate relations of the contiguous vaginal and rectal walls were before recognized (page 41). The vagina presents an antero-superior concavity, into which is received the postero-inferior convexity of the bladder and the urethra. The bladder will be found adherent to the anterior surface of the supra-vaginal portion of the neck of the uterus. The relations of the contiguous urethral and vaginal walls were determined in the dissection of the Female Perineum (page 41).

2. Reflections of the Pelvic Peritoneum.—The peritoneum may be traced over the fundus of the bladder—the anterior surface of the organ not being invested by it—whence it spreads over its sides and posterior wall; it is reflected from the latter surface to the anterior of the body of the uterus, thereby forming the vesico-uterine cul-de-sac; it invests the anterior of the

body of the uterus, and it folds over its fundus to cover the posterior of the same; it continues upon the posterior surface of the superior end of the vagina, from which it is reflected to the anterior wall of the rectum, thereby forming the recto-vaginal or Douglas' cul-de-sac (page 41; Fig. 2, Plate 20). From the lateral border of the body of the uterus, the peritoneum is projected in two layers (from the anterior and the posterior surface, respectively) as a broad ligament of the organ (page 69; Fig. 2, Plate 37).

DISSECTION.—Section the peritoneum of the vesico-uterine cul-de-sac, and dissect the bladder and urethra from the uterus and the vagina. Section the recto-vaginal cul-de-sac, and separate the vagina from the rectum. Slit open the bladder and urethra along the mid-line of their antero-superior wall and spread them open upon a dissecting board.

3. Bladder and Urethra.—The interior of the female bladder presents the same appearances as the male (page 97). The short female urethra, one inch and a half in length, is in marked contrast to the male urethra of eight inches; it was seen (page 40; Fig. 1, Plate 20) forming a conical projection from the neck of the bladder; on section, this projection will be found forming a thick wall to the canal.

DISSECTION.—Lay the uterus with its broad ligaments and the vagina (emptied of ova) upon the dissecting board, with their antero-superior face uppermost (Fig. 1, Plate 57); pin the organs fast.

4. Broad Ligaments of the Uterus, Fig. 1, Plate 57.—These two ligaments are projected one from either side of the body of the uterus; they are formed as shown above by two layers of peritoneum; the anterior layer presents a smooth unbroken surface.

DISSECTION.—Incise and dissect off the anterior layer of the right broad ligament of the uterus (Fig. 1, Plate 57); determine the Fallopian tube, the round ligament of the uterus, the ligament of the ovary, and the ramifications of the uterine and ovarian arteries between the layers of the ligament. Recognize the slit in the anterior face of the posterior layer of the ligament, where the vessels to, and from, the ovary pass; the ligament of the ovary also passes to the latter through it.

5. Fallopian Tubes.—These canals spring from the superior and lateral angles of the body of the uterus. A Fallopian tube

is about four inches in length, and terminates by a free fimbriated extremity ; one of the fimbriæ being pervious.

6. Round Ligament of the Uterus.—This so-called ligament springs from the side of the body of the uterus ; it passes between the layers of the broad ligament, to emerge from beneath its anterior layer.

7. Ligament of the Ovary.—This so-called ligament is projected from the side of the body of the uterus, at a point between the giving off of the Fallopian tube and the round ligament (nearer the former) ; it continues laterally, between the layers of the broad ligament, to pass out from between them, at the slit in the posterior layer of said ligament (page 102), for attachment to the internal end of the ovary.

8. Uterine Artery, Figs. 1 and 2, Plate 57.—This artery enters between the layers of the broad ligament, external to and opposite the attachment of the vagina to the uterus. It gives off an inferior branch to the exterior of the lateral wall of the vagina, and then continues parallel with and external to the lateral border of the uterus, toward the fundus of the latter ; at about opposite the middle of the body of the uterus, it anastomoses with a branch from the ovarian artery of the side.

9. Ovarian Artery.—This artery enters between the layers of the broad ligament ; it runs parallel with, and inferior to, the Fallopian tube, toward the body of the uterus. It gives off branches to the ovary and the Fallopian tube, of the side, and finally anastomoses with the uterine artery, as before shown. Its branches to the ovary pass to that organ through the slit in the posterior layer of the broad ligament (page 102).

DISSECTION.—Detach the uterus, etc.; spread the organs out upon the board with their posterior face uppermost and pin them fast (Fig. 2, Plate 57).

10. Peritoneal Investment of the Uterus, Fig. 2, Plate 57.—The greater peritoneum, as before stated (page 102), covers the entire posterior surface of the body of the uterus and is continued, inferiorly, upon the exterior of the superior end of the vagina. From the sides of the uterus it is projected, as the posterior layer of the broad ligament.

11. Ovary.—This almond-shaped body is swung free from the posterior face of the posterior layer of the broad ligament; it is attached thereto by its long axis. An ovary is about one inch and a quarter long, three-quarters of an inch wide, and half an inch thick; it weighs about four scruples. Its arteries and nerves reach it, and its veins and lymphatics leave it by the slit, seen at the anterior face of the posterior layer of the broad ligament (page 102; Fig. 1, Plate 57).

12. Vagina.—This canal, about four inches long, has an exterior fibrous, a middle muscular, and an interior mucous coat. Its free end, which is its narrowest point, forms a vertical fissure or opening at the pudendum (pages 30 and 41; Plates 19 and 20); at its middle, which is its widest part, its transverse diameter is the longest; at its attached or uterine end it is almost circular, receiving into its opening the neck of the uterus; the walls of the vagina (page 41) are in apposition. Slitting open the vagina along its postero-inferior wall (Fig. 2, Plate 57), it presents an antero-superior and a postero-inferior mid-line ridge of its mucous membrane—the columns of the vagina; between these columns the lateral halves of the mucous membrane bridge, forming rugæ; these rugæ are best marked at the pudendal end of the canal, and become less and less so toward its uterine end.

13. Uterus.—The uterus is a cylindrical body, constricted at its middle, and somewhat flattened antero-posteriorly; it weighs about ten drachms, and measures two inches and a half long, one inch and a half wide, and one inch thick; its superior end, the fundus, is globular and larger than its inferior. The inferior end is projected into the superior opening of the vagina, the latter being attached to the circumference of the former. The uterus is a hollow organ, the canals of the Fallopian tubes open into the cavity of its body, the latter into the cavity of its neck, and the cavity of the neck of the uterus opens, at the *external os*, into the vaginal canal. It is about equally divided into a body and neck portion. From the lateral borders of the body, the Fallopian tubes, the ovarian, the round and the broad ligaments are projected, as before shown (pages 102 and 103). The inferior portion of the neck projects into the vagina, where it presents a short anterior and

a long posterior lip, which are determined by the *external os* (mouth of the uterus) between the two.

DISSECTION.—Trim away the broad, the ovarian, and the round ligaments from the border of the uterus; cut the Fallopian tubes two inches from the uterus. Slit open the posterior wall of the uterus from the *os uteri* to the fundus; enter a fine probe into the stump of the Fallopian tube, and cause it to emerge into the cavity of the body of the uterus; make two additional lateral slits to the uterine openings of the Fallopian tubes; pin out the uterus thus opened (Fig. 3, Plate 57).

14. Interior of the Uterus, Fig. 3, Plate 57.—The interior of the uterus shows the organ to be about equally divided into a body and a neck portion. The cavity of the neck and the cavity of the body are readily distinguishable by the difference in the appearance of their mucous membrane. The cavity of the body is somewhat triangular, and has the Fallopian tubes opening into it at the angles of its base; at the apex of the cavity of the body is a slightly constricted portion, the *internal os*, through which it opens into the cavity of the neck portion of the organ. The cavity of the neck is dilated at its mid-portion, and constricted at its ends, the *internal os* and the *external os*; its interior presents a median-line longitudinal ridge upon the anterior and the posterior walls, between which its redundant mucous membrane is laid in transverse pleats upon its lateral walls, *arbor vitæ uterinus*. The exterior of the uterus is, as before shown (page 104), partially covered by peritoneum; the interior of its cavities are lined by mucous membrane, continuous with that of the Fallopian tubes and the vagina; the mid-portion of the wall of the organ, between its serous and mucous membrane, is composed of involuntary muscular fibre.

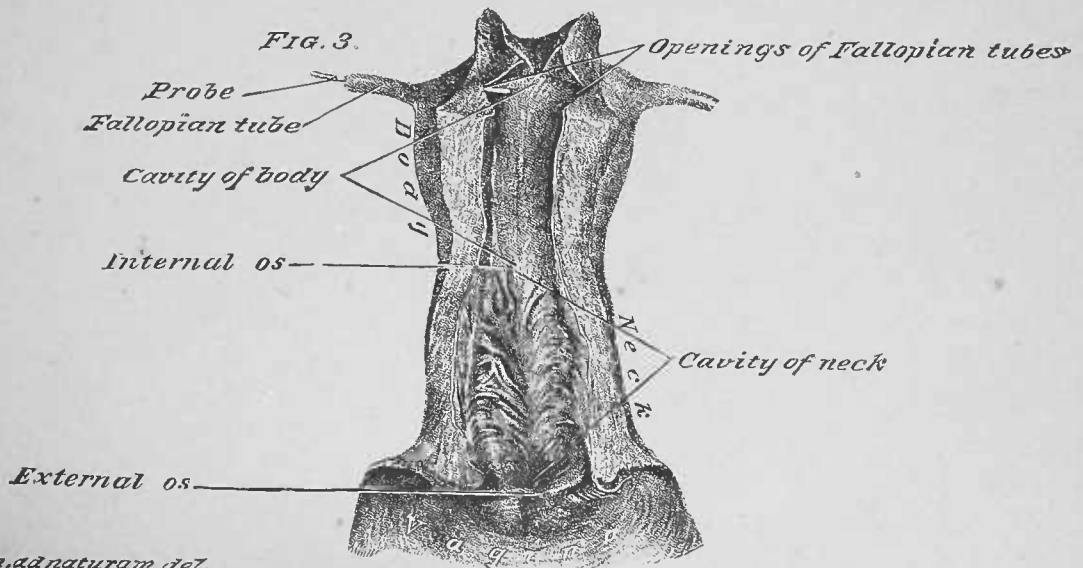
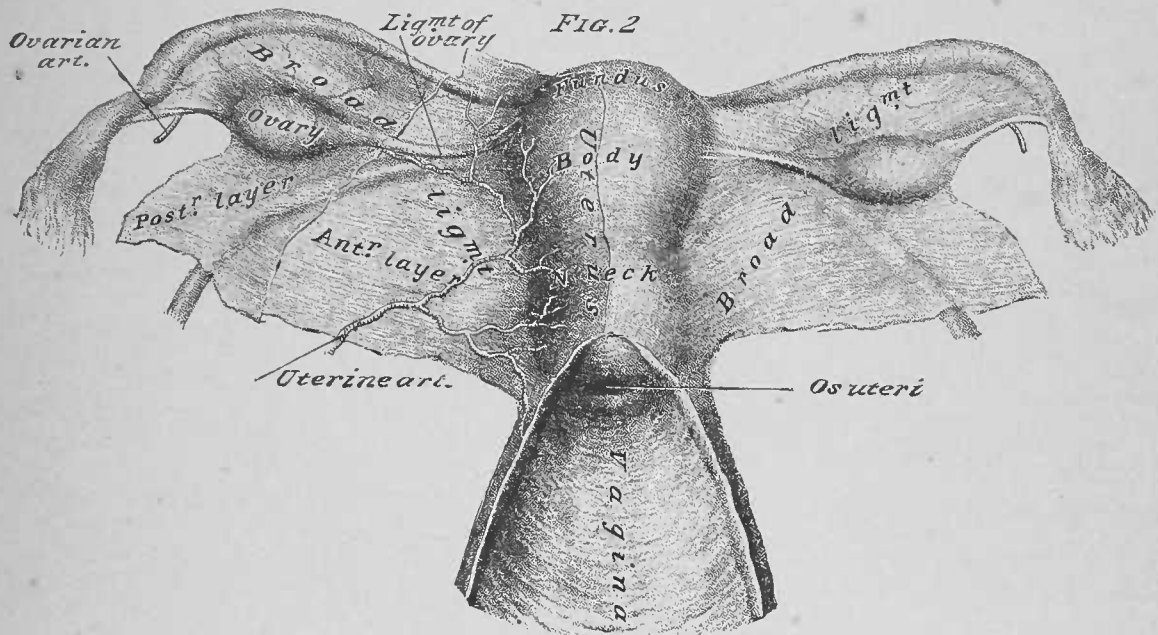
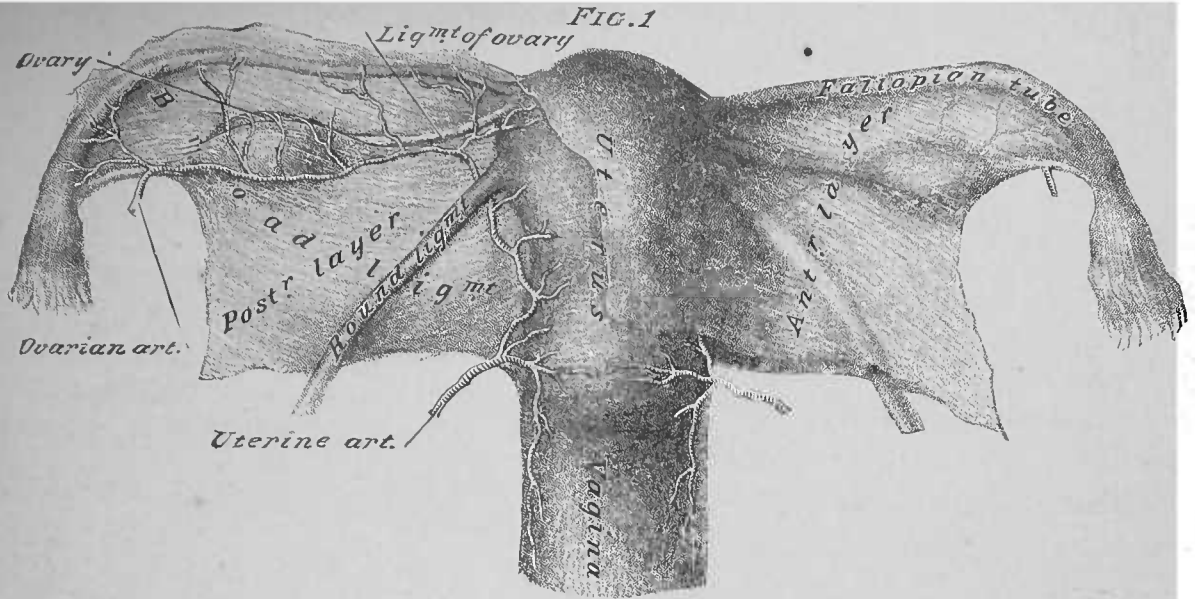
DISSECTION.—Dissect off loose fibrous tissue from the circumference of the rectum, preserving its partial investment of peritoneum, and the arteries that distribute to it. This portion of the alimentary canal is described here, at the end of the dissection of the female pelvic organs, but the description is intended to apply to the rectum in both sexes. Remove the oakum from the rectum, and expose its interior, by slitting it from its inferior end and folding back the two sides of the canal.

15. Rectum, Figs. 1 and 2, Plate 58.—Portions of the rectum presented and were described in the dissections of the organs at the pelvic outlet, male (page 27; Plates 11 and

12) and female (page 41 ; Fig. 2, Plate 20). This, the terminal eight inches of the large intestine, presents two curvatures, which form its three portions, viz.: first, second, and third. The first portion extends to the first curvature ; the second, between the curvatures, has a postero-inferior convexity and an antero-superior concavity ; the third portion, beyond the second curvature, tips posteriorly, and terminates at the anus, where it is surrounded by the sphincter ani muscle. The rectum differs from the colon of the large intestine : first, in the absence of the three longitudinal bands of the latter ; second, in the absence of appendices epiploicæ.

In unfolding the rectum, as directed, note a contraction at the anus, produced by the external and internal sphincters ; a dilatation within the anus ; and a bend in the gut at the junction of its second and first portions.

In structure, the walls of the rectum will be found to present an exterior, partial, peritoneal coat (pages 67 and 95), a muscular coat, a submucous coat and an interior mucous coat. In the muscular coat the fibres are both longitudinal and circular : the longitudinal fibres are distributed to the entire circumference of the canal, presenting lateral thickenings of the same, by which an attempt at a right and left muscle-band are determined. The sphincter ani muscle surrounds the anal orifice, and the fibres of the levator ani portion of the levator ani et prostatae or levator ani et vaginae muscle reach the wall of the rectum, beneath the plane of the sphincter ani muscle (page 25 ; Plates 10, 11, and 12).



J. Cohn, a. d. naturam del.

FIG. 1

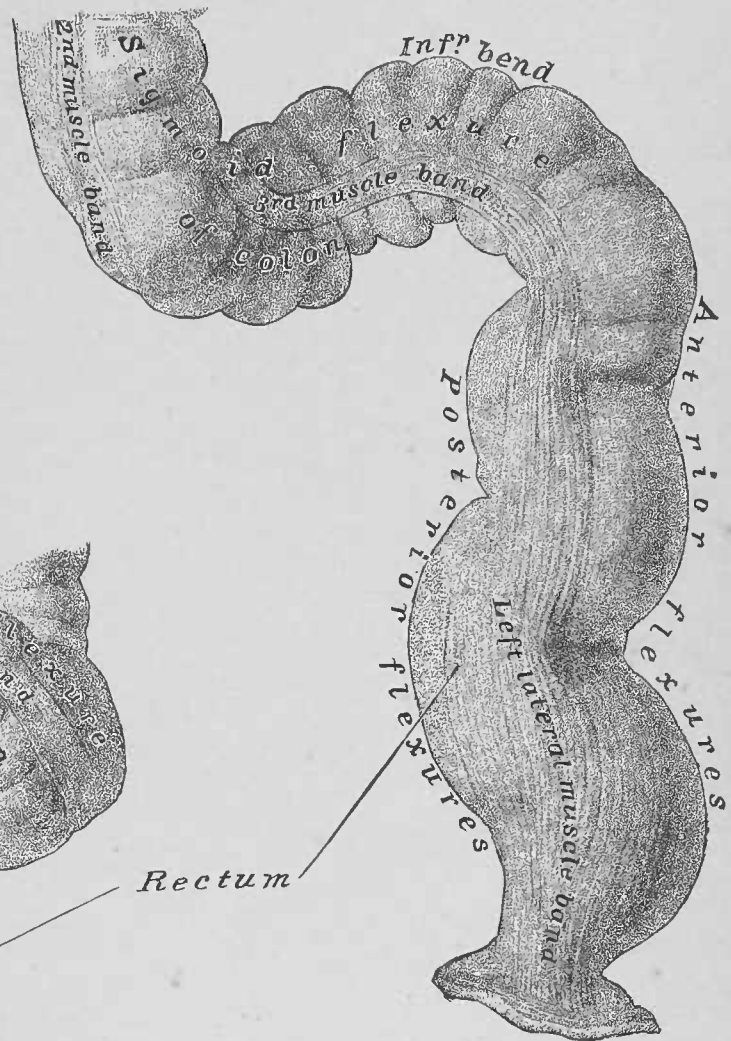
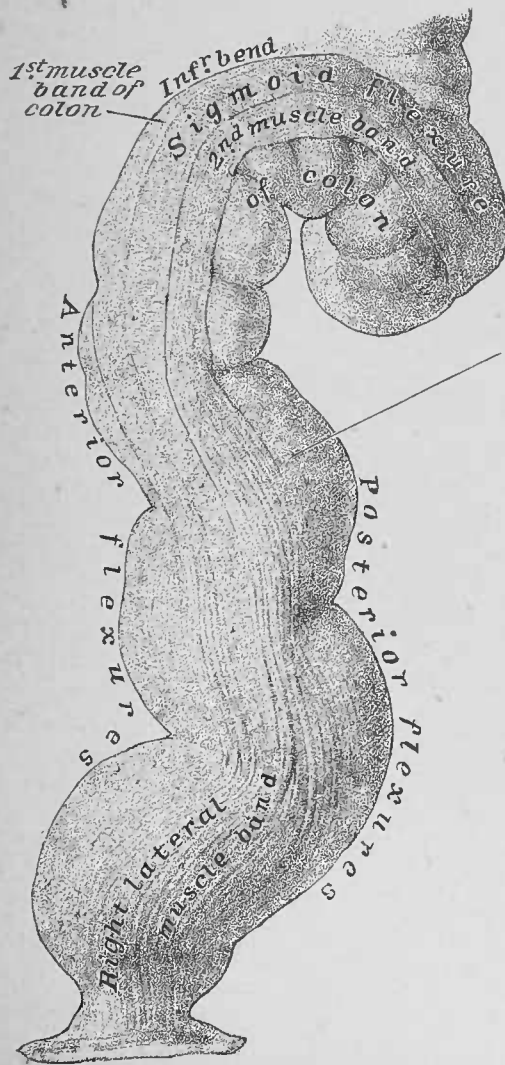


FIG. 2



Rectum

I. C. B. - BIBLIOTECA
TRAN F. F. M. - D PT. ANATOMIA
DA A 17/11/1975 1786

QM34
W432p
1888
v.1

DEDALUS - Acervo - ICB
Practical human anatomy;



12100003991

SYS.0294129

N.º 1786.....

QM34

W432p

1888

Autor Weisse, Faneuil Dunkin^{v.1}.....

Título Practical human anatomy;

a working guide for ...

NOME	DATA

QM34

W432p

1888

v.1

t.1786

Weisse, Faneuil Dunkin
Practical human anatomy; a working guide for students of medicine and ready-reference for surgeons and physicians

**U.S. PUBLIC HEALTH SERVICE
F. B. U.S.P.
BIBLIOTECA**

